COLUMBIA LIBRARIES OFFSITE
HEALTH SCIENCES RESTRICTED
HR02093723

SERIAL

V.5

A

24th-26th meeting
1891-1893

Columbia University
in the City of New York

College of Physicians and Surgeons

Reference Library

15

TRANSACTIONS

OF THE

AMERICAN OTOLOGICAL SOCIETY.

1891-1893.

VOLUME V.

NEW BEDFORD:
MERCURY PUBLISHING COMPANY, 112 AND 114 UNION STREET.
1893.

INDEX TO VOLUME V.

OF THE

TRANSACTIONS OF THE AMERICAN OTOLOGICAL SOCIETY.

Anatomy. A concluding report of the — of the elephant's ear. H. Richards 139

Anatomy. Notes on the comparative — of the ossicles. L. Howe 450

Autopsies in two cases of complicated ear disease. T. Y. Sutphen 414

Bacon, Gorham. Notes on the use of the Leiter coil in the early stage of mastoid disease 108

Bacon, Gorham. A case of mastoid disease, following an operation for the removal of adenoid vegetations 213

Bacon, Gorham. Alphabetical index of otological literature from July 1, 1891, to July 31, 1892 352

Bacon, Gorham. Alphabetical index of otological literature, from July 31, 1892, to July 31, 1893 517

Barclay, R. On the difficulty of operation in the depth of the ear canal; with description and drawing of new instruments for surmounting it 500

Blake, C. J. Alphabetical index of otological literature, from July 1, 1890, to July 1, 1891 151

Blake, C. J. Mastoid cases 23

Blake, C. J. Mastoid cases 203

Blake, C. J. Middle ear operations 306

Blake, C. J. Notes of two fatal cases of suppurative middle ear disease, with brain complications and operation 425

Blake, C. J. Statistics of the Aural Department of the Massachusetts Charitable Eye and Ear Infirmary, from April 1 to July 1, 1893, with remarks 429

Blake, C. J. Stapedectomy and other middle ear operations . . . 464

Brain surgery. A contribution to the — of ear disease. Thomas R. Pooley 439

Brain symptoms. Two cases of ear disease with —; mastoid oper-

ation in both: recovery in one, death in the other. H. Knapp 403
Buck, A. H. The strongly counter-irritant effect of the usual mastoid operation 387
Burnett, Chas. H. Excision of the membrana tympani and necrotic malleus in four cases of chronic suppurative otitis media . 116
Burnett, Chas. H. The surgical treatment of chronic tympanic vertigo — often misscalled Ménière's disease 488

Craniometric studies. Preliminary notes on — in relation to aural anatomy. B. Alexander Randall 255

Difficulty. On the — of operation in the depth of the ear canal; with description and drawing of instruments for surmounting it. R. Barclay 500
Dislocation. An unusual form of — of the malleus handle. Samuel Theobald 137

Emerson, J. B. A case of pyæmia, following acute suppurative otitis. Recovery 221
Excision of the membrana tympani and necrotic malleus in four cases of chronic suppurative otitis media. Chas. H. Burnett . 116
Excision of the membrana tympani and malleus for catarrhal deafness, followed by suppuration, mastoid empyema and burrowing abscess of the neck. B. Alex Randall 325
Exostosis. A case of — of the external auditory canal. Removal. Considerable improvement in the hearing power. D. B. St. John Roosa 331

Forceps. A new aural —. E. D. Spear 149

Green, J. Orne. Demonstration of pathological specimens . . . 454
Gruening, E. Notes on operations on the mastoid process 66
Gruening, E. A case of septic thrombosis of the lateral sinus, with autopsy 419

Holt, E. E. Removal of the entire auricle and a part of the lobe by the bite of a horse 340
Howe, L. Notes on the comparative anatomy of the ossicles . . 450

Index. Alphabetical — of otological literature, from July 1, 1890, to July 1, 1891, compiled by C. J. Blake 151
Index. Alphabetical — of otological literature, from July 1, 1891, to July 31, 1892, compiled by G. Bacon 352
Index. Alphabetical — of otological literature from July 31, 1892, to July 31, 1893, compiled by G. Bacon 517
Infirmary. Statistics of the Aural department of the Massachusetts Charitable Eye and Ear —, from April 1 to July 1, 1893, with remarks. C. J. Blake 429
Influenza-otitis in 1891. B. Löwenberg 70

Jack, F. L. Remarkable improvement in hearing, by removal of the stapes 284
Jack, F. L. Further remarks on removal of the stapes 474

Kipp, C. J. A case of acute purulent inflammation of the middle ear, with double optic neuritis, but without tenderness or swelling of, or spontaneous pain in, the mastoid process, in which the opening of the mastoid cells was followed by a rapid subsidence of the optic neuritis and cure of the ear disease 216
Knapp, H. Two cases of acute mastoid inflammation; both operated on. In one, otorrhœa and fatal meningitis. Death, as shown by autopsy, preventable. In the other, the drumhead unbroken. Perfect recovery 13
Knapp, H. A case of chronic purulent otitis media; old pulmonary tuberculosis; opening of the mastoid; death from acute basilar meningitis; autopsy 205
Knapp, H. Two cases of ear disease with brain symptoms; mastoid operation in both: recovery in one, death in the other . . 403

Lateral sinus. Wound of the — during an operation upon the mastoid process, in a patient with phthisis pulmonalis. Septicæmia. Recovery. D. B. St. John Roosa 274
Lateral sinus. A case of septic thrombosis of the — with autopsy. E. Gruening 419
Leiter coil. Notes on the use of the — in the early stage of mastoid disease. G. Bacon 108
Löwenberg, B. Influenza-otitis in 1891 70

Mastoid inflammation. Two cases of acute —, both operated on. In one, otorrhœa and fatal meningitis. Death, as shown by autopsy, preventable. In the other, the drumhead unbroken. Perfect recovery. H. Knapp 13
Mastoid cases. C. J. Blake 23
Mastoid process. Notes on operations on the —. E. Gruening . 66
Mastoid disease. Cases of —, exhibiting somewhat extensive carious processes. O. D. Pomeroy 192

Mastoid cases. C. J. Blake 203
Mastoid. Result of opening the — in a case of chronic middle ear suppuration, with cerebral complications and septicæmic symptoms. Recovery. T. Y. Sutphen 210
Mastoid disease. A case of —, following an operation for the removal of adenoid vegetation. Gorham Bacon 213
Mastoid operation. The strongly counter-irritant effect of the usual —. A. H. Buck 387

Members of the American Otological Society 5, 183, 379
Mercury. The value of weak solutions of bichloride of — in the treatment of otitis media suppurativa. Samuel Theobald . . 232
Middle ear operations. C. J. Blake 306
Minutes of annual meetings 8, 186, 382

Nomenclatura morborum auris et nomenclatura morborum nasi et naso-pharyngis. E. D. Spear 341
Notice.—The *Lenval* prize 351

Pathological specimens. Demonstration of —. J. Orne Green . 454
Perforations. Some partially successful attempts to promote the healing of old — of the tympanal membrane. Samuel Theobald 125
Pomeroy, O. D. Cases of mastoid disease, exhibiting somewhat extensive carious processes 192
Pooley, Thos. R. A contribution to the brain surgery of ear disease 439
Purulent inflammation of the middle ear. A case of acute —, with double optic neuritis, but without tenderness or swelling of, or spontaneous pain in, the mastoid process, in which the opening of the mastoid cells was followed by a rapid subsidence of the optic neuritis, and cure of the ear disease. C. J. Kipp . . . 216
Purulent otitis media. A case of chronic —; old pulmonary tuberculosis; opening of the mastoid; death from acute basilar meningitis. Autopsy. H. Knapp 205
Pyæmia. A case of —, following acute suppurative otitis. Recovery. J. B. Emerson 221

Randall, B. Alex. A case of suppuration, exostosis, and otic epilepsy; mastoid trephining, followed by fatal septic meningitis 93
Randall, B. Alex. Preliminary notes on craniometric studies in relation to aural anatomy 255
Randall, B. Alex. Excision of membrane and malleus for catarrhal deafness, followed by suppuration, mastoid empyema, and burrowing abscess of the neck 325
Randall, B. Alex. The statistics of ear disease 511
Ray, J. Morrison. Acute suppuration of the middle ear; meningitis; death; autopsy; no involvement of the temporal bone . . 90
Reflex. A case of aural — of unusual character, due to impacted cerumen. Samuel Theobald 508
Removal of the stapes. Remarkable improvement in hearing by—. F. L. Jack 284
Removal of the stapes. Further remarks on —. F. L. Jack . . . 474
Removal of the entire auricle and a part of the lobe by the bite of a horse. E. E. Holt 340

Richards, H. A concluding report on the anatomy of the elephant's ear 139
Roosa, D. B. St. John. Wound of the lateral sinus during an operation upon the mastoid process in a patient with phthisis pulmonalis. Septicæmia. Recovery 274
Roosa, D. B. St. John. A case of exostosis of the external auditory canal. Removal. Considerable improvement in hearing power 331

Spear, E. D. A new aural forceps 149
Spear, E. D. Nomenclatura morborum auris et nomenclatura morborum nasi et naso-pharyngis 341
Stapedectomy and other middle ear operations. C. J. Blake . . . 464
Statistics. The — of ear disease. B. Alex. Randall 511
Suppuration. Acute — of the middle ear; meningitis; death; autopsy; no involvement of the temporal bone. J. Morrison Ray 90
Suppuration. A case of —, exostosis, otic epilepsy, mastoid trephining, followed by fatal septic meningitis. B. Alex. Randall 93
Suppurative middle ear disease. Notes of two fatal cases of —, with brain complications and operation. C. J. Blake 425
Suppurative otitis. Three cases of acute —, with complications and one death. F. M. Wilson 84
Sutphen, T. Y. Result of opening the mastoid in a case of chronic middle ear suppuration, with cerebral complications and septicæmic symptoms. Recovery 210
Sutphen, T. Y. Autopsies in two cases of complicated middle ear disease 414

Theobald, Samuel. Some partially successful attempts to promote the healing of old perforations of the tympanal membrane . . 125
Theobald, Samuel. An unusual form of dislocation of the malleus handle 137
Theobald, Samuel. The value of weak solutions of bichloride of mercury in the treatment of otitis media suppurativa 232
Theobald, Samuel. A case of aural reflex of unusual character, due to impacted cerumen 508
Tympanic vertigo. The surgical treatment of chronic —, often miscalled Ménière's disease. Chas. H. Burnett 488

Wilson, F. M. Three cases of acute suppurative otitis, with complications and one death 84

TRANSACTIONS

OF THE

AMERICAN OTOLOGICAL SOCIETY,

TWENTY-FOURTH ANNUAL MEETING.

ARLINGTON HOUSE, WASHINGTON, D. C.,

SEPTEMBER 22, 1891.

VOL. V., PART 1.

PUBLISHED BY THE SOCIETY:
MERCURY PUBLISHING COMPANY, PRINTERS,
NEW BEDFORD, MASS.
1892.

Extra copies may be had by addressing the secretary, Dr. J. J. B. Vermyne, 2 Orchard street, New Bedford, Mass., or the Mercury Publishing Company, 112 and 114 Union Street, New Bedford, Mass.

CONTENTS.

Members of the American Otological Society 5
Minutes of the Twenty-Fourth Annual Meeting 8
Two cases of acute mastoid inflammation; both operated on. In one, otorrhœa and fatal meningitis. Death, as shown by autopsy, preventable. In the other, the drumhead unbroken. Perfect recovery. By H. Knapp, M. D., New York, N. Y. 13
Mastoid cases. By Clarence J. Blake, M. D., Boston, Mass. . . . 23
Notes on operations on the mastoid process. By E. Gruening, M. D., New York, N. Y. 66
Influenza-otitis in 1891. By B. Lœwenberg, M. D., Paris, France. 70
Three cases of acute suppurative otitis with complications and one death. By F. M. Wilson, M. D., Bridgeport, Conn. . . 84
Acute suppuration of the middle ear—meningitis—death—autopsy—no involvement of the temporal bone. By J. Morrison Ray, M. D., Louisville, Ky 90
A case of suppuration, exostosis, and otitic epilepsy; mastoid trephining followed by fatal septic meningitis. By B. Alex. Randall, M. D., Philadelphia, Pa. 93
Notes on the use of the Leiter coil in the early stage of mastoid disease. By Gorham Bacon, M. D., New York, N. Y. . . 108
Discussion. 109
Excision of the membrana tympani and necrotic malleus in four cases of chronic suppurative otitis media. By Charles H. Burnett, M. D., Philadelphia, Pa. 116
Some partially successful attempts to promote the healing of old perforations of the tympanal membrane. By Samuel Theobald, M. D., Baltimore, Md. 125
Discussion. 133
An unusual form of dislocation of the malleus handle. By Samuel Theobald, M. D., Baltimore, Md. 137
A concluding report on the anatomy of the elephant's ear. By Huntington Richards, M. D., New York, N. Y. 139
A new aural forceps. By E. D. Spear, M. D., Boston, Mass 149
Alphabetical index of otological literature from July 1, 1890, to July 1, 1891. Compiled by Clarence J. Blake, M. D., Boston, Mass. 151

MEMBERS

OF THE

AMERICAN OTOLOGICAL SOCIETY.

Names of members deceased while in membership in italics.

HONORARY MEMBERS.

PROF. A. GRAHAM BELL, . 1336 Nineteenth St., . . Washington, D. C.
Dr. E. H. Clarke.
PROF. ALFRED M. MAYER, Stevens Institute, . . . Hoboken, N. J.
PROF. OGDEN M. ROOD, . 340 East 15th St., . . . New York, N. Y.
Dr. E. Williams.

ACTIVE MEMBERS.

DR. FRANK W. ABBOTT, . 223 Franklin St., ... Buffalo, N. Y.
Dr. C. R. Agnew.
DR. HARLAN P. ALLEN, . 73 East State St., . . . Columbus, O.
DR. A. ALT, ... 3036 Locust St., ... St. Louis, Mo.
DR. J. A. ANDREWS, 9 West 22d St., ... New York, N. Y.
DR. S. C. AYRES, 64 West 7th St., ... Cincinnati, O.
DR. GORHAM BACON, . . . 63 West 54th St., . . . New York, N. Y.
DR. BENJAMIN J. BALDWIN, 13 South Perry St., . . Montgomery, Ala.
DR. ROBERT BARCLAY, . . 3211 Lucas Ave., ... St. Louis, Mo.
DR. EDWIN W. BARTLETT, 422 Jefferson St., . . . Milwaukee, Wis.
DR. CLARENCE J. BLAKE, . 226 Marlboro St., . . . Boston, Mass.
DR. R. O. BORN, ... 163 West 34th St., . . . New York, N. Y.
DR. ALBERT H. BUCK, . . 19 East 38th St., ... New York, N. Y.
DR. CHARLES H. BURNETT, 127 South 18th St., . . Philadelphia, Pa.
DR. FRANKLIN P. CAPRON, 203 Washington St., . . Providence, R. I.
DR. W. H. CARMALT, . . . 87 Elm St., ... New Haven, Conn.
Dr. J. H. Dix.
Dr. E. Dyer.
Dr. E. P. Ely.
DR. J. B. EMERSON, . . . 20 East 30th St., ... New York, N. Y.
DR. B. E. FRYER, U. S. A., 1224 Broadway, ... Kansas City, Mo.

Dr. John Green, ... 2670 Washington Ave., St. Louis, Mo.
Dr. J. Orne Green, . . . 182 Marlborough St., . . Boston, Mass.
Dr. Emil Gruening, . . . 109 East 23d St., ... New York, N. Y.
Dr. G. W. Hale, ... 235½ North Summer St., Nashville, Tenn.
Dr. George C. Harlan, . 1515 Walnut St., ... Philadelphia, Pa.
Dr. David Harrower, Jr., 9 Elm St., ... Worcester, Mass.
Dr. Neil J. Hepburn, . . 369 West 23d St., . . . New York, N. Y.
Dr. Edward L. Holmes, 112 Clark St., ... Chicago, Ill.
Dr. E. E. Holt, ... 723 Congress St., . . . Portland, Me.
Dr. Wm. H. Hotchkiss, . 3813 Washington Ave., St. Louis, Mo.
Dr. Lucien Howe, ... 183 Delaware Ave., . . Buffalo, N. Y.
Dr. Frederick L. Jack, . 437 Boylston St., . . . Boston, Mass.
Dr. W. B. Johnson, . . . 197 Market St., ... Paterson, N. J.
Dr. Samuel J. Jones, . . Argyle Bg., 7 Jackson St. Chicago, Ill.
Dr. Charles J. Kipp, . . 534 Broad St., ... Newark, N. J.
Dr. Herman Knapp, . . . 25 West 24th St., ... New York, N. Y.
Dr. J. W. Lawton.
Dr. J. A. Lippincott, . . 435 Penn. Ave., ... Pittsburg, Pa.
Dr. W. S. Little.
Dr. F. B. Loring, ... 1420 K St., North West, Washington, D. C.
Dr. C. J. Lundy, ... 27 Adams Ave., East, . Detroit, Mich.
Dr. Arthur Mathewson, 139 Montague St., . . . Brooklyn, N. Y.
Dr. Read J. McKay, . . . 900 Market St., ... Wilmington, Del.
Dr. C. S. Merrill, ... 23 Washington Ave., . Albany, N. Y.
Dr. H. G. Miller, ... 262 Benefit St., ... Providence, R. I.
Dr. W. W. Morland.
Dr. H. L. Morse, ... 112 Marlborough St., . Boston, Mass.
Dr. Robert C. Myles, . . 25 West 36th St., . . . New York, N. Y.
Dr. Henry D. Noyes, . . 233 Madison Ave., . . . New York, N. Y.
Dr. J. F. Noyes, ... Detroit, Mich.
Dr. Oren D. Pomeroy, . 316 Lexington Ave., . . New York, N. Y.
Dr. Thomas R. Pooley, . 107 Madison Ave., . . . New York, N. Y.
Dr. J. S. Prout, ... 26 Schermerhorn St., . Brooklyn, N. Y.
Dr. B. Alexander Randall,
1806 Chestnut St., . . . Philadelphia, Pa.
Dr. Wm. Rankin, Jr., . . 23 Cedar St., ... Newark, N. J.
Dr. J. M. Ray, ... 414 W. Chestnut St., . . Louisville, Ky.
Dr. R. A. Reeve, ... 22 Shuter St., cor. Victoria, ... Toronto, Canada.
Dr. Huntington Richards,
19 East 38th St., ... New York, N. Y.
Dr. S. O. Richey, ... 732 Seventeenth St., Washington, D. C.
Dr. Charles E. Rider, . 53 South Fitzhugh St., Rochester, N. Y.
Dr. Wheelock Rider, . . 53 South Fitzhugh St., . Rochester, N. Y.
Dr. Frank W. Ring, . . . 101 Park Ave., ... New York, N. Y.

Dr. S. D. Risley,	1722 Walnut St.,	Philadelphia, Pa.
Dr. D. B. St. John Roosa,	20 East 30th St.,	New York, N. Y.
Dr. John D. Rushmore,	129 Montague St.,	Brooklyn, N. Y.
Dr. Wm. W. Seely,	S. E. cor. 4th and Broadway,	Cincinnati, O.
Dr. Ralph W. Seiss,	49 North 17th St.,	Philadelphia, Pa.
Dr. Samuel Sexton,	12 West 35th St.,	New York, N. Y.
Dr. J. B. Shapleigh,	2332 Washington Ave.,	St. Louis, Mo.
Dr. Henry L. Shaw,	431 Boylston St.,	Boston, Mass.
Dr. E. D. Spear,	6 Beacon St.,	Boston, Mass.
Dr. H. N. Spencer,	2725 Washington Ave.,	St. Louis, Mo.
Dr. George T. Stevens,	33 West 33d St.,	New York, N. Y.
Dr. S. B. St. John,	43 Pratt St.,	Hartford, Conn.
Dr. George Strawbridge,	1500 Walnut St.,	Philadelphia, Pa.
Dr. T. Y. Sutphen,	963 Broad St.,	Newark, N. J.
Dr. J. O. Tansley,	28 West 43d St.,	New York, N. Y.
Dr. Samuel Theobald,	304 West Monument St.,	Baltimore, Md.
Dr. William Thomson,	1426 Walnut St.,	Philadelphia, Pa.
Dr. Charles A. Todd,	2645 Washington Ave.,	St. Louis, Mo.
Dr. J. Vanduyn,	111 South Salina St.,	Syracuse, N. Y.
Dr. J. J. B. Vermyne,	2 Orchard St.,	New Bedford, Mass.
Dr. David Webster,	266 Madison Ave.,	New York, N. Y.
Dr. F. M. Wilson,	317 State St.,	Bridgeport, Conn.

American Otological Society.

The Twenty-Fourth Annual Meeting of the American Otological Society was held at the Arlington House, Washington, D. C., on Tuesday, September 22, 1891, in connection with the Second Congress of American Physicians and Surgeons. The President, Dr. Gorham Bacon, of New York, N. Y., in the chair.

The Society was called to order at 10 A. M.

The following members were present:

Drs. Gorham Bacon,	New York, N. Y.
Benj. J. Baldwin,	Montgomery, Ala.
Clarence J. Blake,	Boston, Mass.
Chas. H. Burnett,	Philadelphia, Pa.
W. H. Carmalt,	New Haven, Conn.
John Green,	St. Louis, Mo.
Emil Gruening,	New York, N. Y.
David Harrower, Jr.,	Worcester, Mass.
E. E. Holt,	Portland, Me.
W. B. Johnson,	Paterson, N. J.
S. J. Jones,	Chicago, Ill.
Herman Knapp,	New York, N. Y.
F. B. Loring,	Washington, D. C.
Arthur Mathewson,	Brooklyn, N. Y.
Read J. McKay,	Wilmington, Del.
B. Alex. Randall,	Philadelphia, Pa.
J. M. Ray,	Louisville, Ky.
R. A. Reeve,	Toronto, Canada.
Huntington Richards,	New York, N. Y.
S. O. Richey,	Washington, D. C.
Charles E. Rider,	Rochester, N. Y.
J. D. Rushmore,	Brooklyn, N. Y.
S. B. St. John,	Hartford, Conn.
T. Y. Sutphen,	Newark, N. J.
S. Theobald,	Baltimore, Md.
J. J. B. Vermyne,	New Bedford, Mass.
F. M. Wilson,	Bridgeport, Conn.

And by invitation:

Drs. Swan M. Burnett, ... Washington, D. C.
J. E. Colburn, ... Chicago, Ill.
H. Gradle, ... Chicago, Ill.
H. Koplik, ... New York, N. Y.
J. A. Maloney, ... Washington, D. C.
H. S. Oppenheimer, ... New York, N. Y.

The President announced that invitations had been extended to a number of otologists abroad to be present at this meeting, but all had refused on account of distance, or lateness of the season, as interfering with the opening of the course of study at the different universities.

The President appointed as the Business Committee Drs. John Green, J. D. Rushmore, and F. M. Wilson.

On account of absence of Drs. Theobald and Risley, members of the Committee on Membership, at the time the Society was called to order, Dr. C. J. Blake and B. Alexander Randall were appointed on the committee.

The Treasurer's report was read and referred to Dr. C. H. Burnett as Auditing Committee. Subsequently this committee stated that the Treasurer's accounts were correct and properly vouched for, and the report of the Treasurer was then accepted.

The Committee on Membership reported favorably on the names of

Drs. W. B. Johnson, of Paterson, N. J.
Wheelock Rider, of Rochester, N. Y.
Robert C. Myles, of New York, N. Y.

who were all elected on ballot.

The reading of papers was then commenced and papers were read in the following order:

1. Dr. H. Knapp, of New York, N. Y. Two cases of Acute Mastoid Inflammation, both operated on. In the one, Otorrhœa and Fatal Meningitis; Death, as shown by

the Autopsy, Preventable; in the other the Drumhead Unbroken; Perfect Recovery.

2. Dr. J. C. Blake, of Boston, Mass., Mastoid Cases.

At the conclusion of the reading of Dr. Blake's paper, the chairman of the Business Committee announced that, as the afternoon was devoted to the sessions of the Congress, and as the Committee of Arrangements for the Congress desired to leave the evening free for social pleasure, there would be but one session of the society, until 2 P. M. He therefore recommended that papers be read by abstract or by title as much as possible.

Subsequently the following papers were read:

3. Dr. E. Gruening, of New York, N. Y. Remarks on Operations on the Mastoid. By abstract.

4. Dr. B. Loewenberg, of Paris, France. Influenza-Otitis in 1891. By title.

5. Dr. F. M. Wilson, of Bridgeport, Conn. Three Cases of Suppurative Otitis Media with Complications and One Death. By title.

6. Dr. J. M. Ray, of Louisville, Ky. Acute Suppuration of the Middle Ear; Meningitis; Death; Autopsy; No Involvement of the Temporal Bone. By title.

7. Dr. B. Alexander Randall, of Philadelphia, Pa. A Case of Suppuration; Exostosis and Otitic Epilepsy;—Trephining, followed by Fatal Septic Meningitis, with a Consideration of other Specimens, Illustrating the Avenues of Communication of Otitis to the Brain. Read by abstract and specimen and illustrations shown.

8. Dr. Gorham Bacon, of New York, N. Y. Notes on the use of the Leiter Coil in the Early Stage of Mastoid Disease. By abstract.

The different papers on Mastoid Disease were then collectively discussed by Drs. McKay, Burnett, Sutphen, Wilson, Gruening, Knapp, and Randall.

9. Excision of the Membrana Tympani and Necrotic

Malleus in a Case of Chronic Suppurative Otitis Media, by Dr. C. H. Burnett, of Philadelphia, Pa. By title.

10. Dr. S. Theobald, of Baltimore, Md. Some partially Successful Attempts to Promote the Healing of Old Perforations of the Tympanal Membrane.

Discussed by Drs. McKay, Blake, Richey, Jones, and Burnett.

11. A second paper by Dr. Theobold, entitled: An Unusual Form of Dislocation of the Malleus Handle, was read by title and illustration shown.

12. Dr. Huntington Richards of New York, N. Y., presented specimens and illustrations from his "Concluding Paper on the Anatomy of the Elephant's Ear," and gave an abstract from his paper.

13. A paper by Dr. R. A. Reeve, of Toronto, Canada, on Cases of Exostosis of the External Meatus was read by title.

14. A New Aural Forceps, by Dr. E. D. Spear, of Boston, Mass., was exhibited to the Society.

All papers were referred to the Committee on Publications, and at 1.45 P. M. the Society went into executive session.

The Business Committee reported the following list of officers for the ensuing year:

President:	DR. GORHAM BACON.
Vice President:	DR. HUNTINGTON RICHARDS.
Secretary and Treasurer:	DR. J. J. B. VERMYNE.
Committee on Publications: . .	DR. C. J. BLAKE. DR. J. ORNE GREEN. The Secretary, ex officio.
Committee on Membership: . .	DR. A. MATHEWSON. DR. S. THEOBALD. DR. S. W. RISLEY.

who all were duly elected on ballot.

The Committee further recommended that the next Annual Meeting of the Society be held on the day before

the next Annual Meeting of the American Ophthalmological Society and at the same place. Carried.

On motion of Dr. Mathewson the Secretary was instructed to convey to Dr. J. S. Prout, of Brooklyn, N. Y., who for a number of years had been President of the Society, their regret at his illness, and their sincere wishes for his speedy recovery.

On motion, the reading of the records was dispensed with, and at 2.15 P. M. the Society adjourned.

J. J. B. VERMYNE, *Secretary*.

TWO CASES OF ACUTE MASTOID INFLAMMATION; BOTH OPERATED ON. IN ONE, OTORRHŒA AND FATAL MENINGITIS. DEATH, AS SHOWN BY AUTOPSY, PREVENTABLE. IN THE OTHER, THE DRUMHEAD UNBROKEN. PERFECT RECOVERY.

By H. Knapp, M. D., *New York, N. Y.*

Case I.—Acute otitis media purulenta with marked cerebral symptoms. Chiselling of mastoid to the depth of half an inch; no pus struck. Remission of symptoms. Death thirty-three days later from meningitis, propagated from pus pent up in attic of tympanum and jugular fossa.

Louis Blau, æt. 26, of New York City, came to the New York Ophthalmic and Aural Institute after having suffered four weeks from painful inflammation of his left ear, set in after coryza, with a good deal of prostration. The purulent discharge from the ear was copious at times, scant at others. He had more or less *headache* all the time, frequently *nausea*, but what he chiefly complained of was *dizziness* and some stupor. When he entered the hospital, Jan. 23, 1891, I found him very feeble, with the expression of intense suffering, but his intellect was free, and his answers were to the point. The ear was full of pus and when cleansed showed the soft parts at the bottom of the canal, especially the upper and posterior, dark red and swollen. His temperature was normal.

From the subjective as well as the objective symptoms it was clear that the chief site of the inflammation was the attic of the drum and its surroundings, including the cranial cavity.

I kept the patient in bed, had the ear canal carefully syringed, and warm boric acid water frequently instilled. The next two days there was free discharge and the patient felt easier. Then the dizziness increased and the skin over the mastoid was swollen and tender. Therefore on Jan. 26th I *opened the mastoid.*

A free incision of 1½ inches was made close to the insertion of the auricle, down to the tip of the process. When the periosteum was detached, the bone proved even and hard. An oval opening was chiselled into it, fully one-half inch in depth. The bone was dense, the cells were vascular, and as no pus was found at the depth mentioned, I desisted from chiselling more deeply. The next day the patient felt much better. Temperature 99°. *On the fifth day there was free suppuration from the opening and the ear.* Patient felt well, his pulse was 68, but his temperature 100°.

Feb. 1. Intense pain at night. Steaming ordered. In the morning profuse discharge of thick, somewhat offensive, greenish pus. Patient felt well then.

During the next week his condition changed considerably; attacks of headache, nausea, and dizziness were followed by more or less complete relief. His temperature was mostly increased from 99° to 101°. His ear was steamed, when the discharge stopped. When the headache was intense ice compresses were applied to the head. His force was kept up by generous diet and some alcoholic drinks. There was some doughiness of the skin above and behind the ear.

In the morning of Feb. 16th, the patient felt somewhat relieved, but at 2 P. M. he had intense headache, vomiting, and chills. Temperature 101°; pulse 78. The doughiness of the skin had disappeared and there was no local sign of mastoiditis. Iced applications to head. At 10.30 P. M., temperature 102°, pulse 84. Patient at times restless, at others drowsy; when waked he gave intelligent answers, but did not recognize some friends who called on him.

Feb. 17th, 4 A. M. Temperature 102°, pulse 88; 7.30 A. M., temperature 103°, pulse 68, weak and irregular. Patient restless, at intervals drowsy. The wound of mastoid operation healed. No swelling or tenderness of mastoid. In the afternoon of the same day, at my request, Dr. Charles McBurney was kind enough to see the patient in consultation with me, in order to decide on the advisability of opening the cranial cavity. His opinion was that it was impossible to localize the focus of pus, the inflammation evidently being generalized. Under these circumstances an operation could be only exploratory. After speaking with the family it was decided not to operate.

At 10 P. M., temperature 105°, pulse 100, weak; patient restless and delirious.

Feb. 18th, 3.30 A. M. Temperature 106°, pulse 120. Patient delirious. Spasms. 4.30 A. M., patient more or less comatose; died at 9.45 A. M.

Autopsy at 3 P. M. same day.

Skull cap and dura normal.

The convexity of the brain, after the removal of the dura, showed a grayish-yellow, purulent infiltration, penetrating into the sulci between the convolutions, principally in the temporal lobes, extending upward over the parietal.

Base of the brain. On slight pressure a thin purulent liquid oozed from the left lateral ventricle, in which, particularly in the posterior cornu, a considerable quantity of thin purulent liquid was found. The ependyma appeared infiltrated. Nothing noteworthy was discovered in the brain substance.

The pia mater, covering the *cerebellum*, was grayish, thickened, yet free from purulent infiltration. Substance normal.

The internal surface of the *left temporal bone* was markedly congested. On removing the dura, a small ab-

scess cavity was found in the foramen lacerum posterius. It could not be followed farther than the tip of the mastoid process. On chiselling through the tegmen tympani and adjacent part of the petrous portion of the temporal bone, a large collection of pus was found in the tympanic attic. Anxious to know what would have occurred had I extended the opening chiselled into the mastoid during life, I laid the scar in the bone free and penetrated through it into the cranial cavity. *The chisel passed through a thin layer of healthy bone into the abscess cavity in the foramen lacerum posterius.*

The labyrinth and the substance of the petrous portion of the temporal bone showed nothing but congestion.

No pus could be found outside the cranial cavity, either in the neighborhood of the jugular vein or elsewhere.

REMARKS.

The foregoing description shows the complete picture of a plain, I may say typical, case of an acute purulent inflammation of the attic of the tympanum, its extension into the neighborhood, and its fatal termination by general purulent meningitis. From the beginning the cerebral symptoms were prominent. The localisation of the chief focus of suppuration in the cupola space of the tympanic cavity was evident from the swelling in the upper and posterior parts of the tympanic walls. Free incisions into the bulging parts and the lower portion of the membrana tympani are now generally recommended in such cases and should not be delayed, in order to prevent, by free drainage, the extension of the suppuration into the cranial cavity. There is, however, a great number of cases in which the process, though commonly protracted, does not travel beyond the middle and external ears and terminates favorably without operative interference or opening a sub-

periosteal abscess in the ear canal. Our case showed as symptoms of extension of the morbid process, *persistent headache*, *nausea*, and, most markedly, *dizziness;* chills and vomiting only in the last days. As long as the former symptoms only are present and persist through weeks, in spite of rest and careful nursing of the patient, the mastoid should be opened.

The autopsy, in the case under consideration, plainly demonstrated that the operation I made was indicated, was situated in the right place, but was insufficient. Had I chiselled from three to five millimeters deeper I would have opened the abscess cavity, and, *possibly*, saved the patient's life.

Küster of Berlin and other surgeons have of late very pointedly and unsparingly reproached aurists for not being abreast with modern surgery. They say, whenever there is pus or necrosed tissue pent up in the mastoid process or any part of the ear, such dead substance must be removed. Not only should we open the mastoid, but, if we do not reach the limits of the morbid products in it, the wound should be extended into the tympanic and even into the cranial cavity, in order to remove all necrosed and infective material. The correctness of this rule could not be more convincingly and forcibly illustrated than by the case under consideration. I should not have stopped at a depth of half an inch, but extended the wound into the cranium, as well as into the tympanic cavity, for in both there were collections of matter which, when removed, might have turned the scale of life in the patient's favor.

This is all very well and good, but it is a dangerous endeavor to abstract rules for general guidance from a limited number of cases, and before the case lies before us in its whole course, we are confronted with the uncertainty of the diagnosis.

In grave cases the surgeons advise us to penetrate into

the mastoid deep and deeper, and when we strike no pus, go forward into the tympanic cavity, emptying it completely, *i. e.*, removing ossicles and chorda tympani, then remove a portion of the roof of the tympanum, lay the dura mater bare, pierce through the inner table of the mastoid and lay the lateral sinus bare, exsect a portion of the thrombosed sinus, or bore into the cranial substance in order to detect and evacuate pus: all this is highly meritorious, when there is thrombo-phlebitis or a cerebral abscess, but it is mortifying when such extensive operating is done and no pus discovered. I have seen such cases, and the older I get the more am I convinced that the strength of the medical man does not lie in his skill, but in his knowledge of the natural history of disease and his penetration as a diagnostician.

Pardon these generalities, Mr. President and Gentlemen, and allow me to illustrate them by an example entirely opposite to the case just reported.

Case II.—Acute mastoiditis interna; membrana tympani unbroken; chiselling; no pus found; recovery.

J. H., a strong man, 51 years old, of New York, came to my office Nov. 30, 1889. He said that six weeks previously he had used the nasal douche for an ordinary cold in his head. Immediately after an application with cold water he had felt pain in his right ear which lasted three or four days, then disappeared, but left a feeling of numbness around the ear, extending over the right side of his head and down the neck to the clavicle. No nausea, no dizziness. The pain returned with more or less severity, deprived him of sleep and greatly depressed his spirits. A competent aurist, a pupil of Schwartze, urged opening of the mastoid process, to which the patient would not consent without a consultation. The consultant concurred in

the opinion of the aurist, but the next day the patient informed the latter that he had concluded to put himself into other hands. He came to my office, giving me the above details, and asked me to take charge of his case. As he was determined not to return to his physician, I examined and treated him. I found the mastoid process somewhat reddened, slightly swollen and tender, the membrana tympani reddish, bulging in the upper posterior part, of normal situation in the anterior and lower. The left drumhead was pale and sunken. H=R $\frac{c}{24}$, L $\frac{5}{24}$; V=R $\frac{20}{60}$, L $\frac{20}{20}$; F=R O>A, L A>O. Some naso-pharyngeal congestion. Not finding any alarming symptoms, I thought I would for the present abstain from surgical interference and try general treatment. I ordered him rest and salicylate of soda, and, later, small doses of quinine. For the next week his ear and head continued to ache, but on the whole he felt better. Dec. 8th he had spells of dizziness the whole day. Dec. 9th he felt well again. The membrana tympani continued red and bulging in its supero-posterior part. On Dec. 13th he came again and told me that he had had intense headache every night but no nausea or dizziness. I found his hearing and *Mt.* as before, but the mastoid swollen and tender, yet fluctuation was not present. Politzer's inflation produced no change either in his hearing or in his feeling.

Thinking that the patient was suffering from a purulent or at least an intense catarrhal mastoiditis interna, and seeing that rest and nursing had as little influence on him as cold applications applied by his former physician to the mastoid had had, I advised him to have his mastoid opened. He consented, went to the New York Ophthalmic and Aural Institute, and was operated on in the afternoon of the same day.

The bulging of the supero-posterior part of the drumhead indicating swelling and exudation in the tympanic

attic and the mastoid antrum. I made an incision over an inch in length close to the insertion of the auricle. The periosteum and bone were somewhat congested. I chiselled an oblong cavity into the bone. The outer cortex was compact, very vascular, three or four millimeters thick. I laid a considerable portion of the cells bare, and opened the antrum to what seemed to be its orifice into the tympanum. The cells and antrum contained no pus, but only a very small quantity of serous liquid. The lining membrane of the air cavities was very vascular and there was a certain number of small polypoid excrescences or granulation tissue in the air spaces, particularly in the antrum. I scraped them out with a small, sharp spoon, cleaning especially the antrum, pushing the spoon into the periphery of the tympanic cavity.

After irrigating the wound with a $\frac{1}{1000}$ solution of bichloride of mercury, I united the skin by sutures in its upper part, and inserted a perforated silver tube into the lower. The patient lost his pain from the moment of the operation. He had a good night. The next day his pulse and temperature were normal. There was some oozing from the wound. The region of the wound kept moderately swollen and there was slight sanguinolent discharge for the next three weeks, and in the evenings a very slight increase of temperature (99° F.). The patient felt comfortable all along and was discharged Jan. 6, 1890. The swelling in the mastoid had almost disappeared, the membrana tympani was less bulging, $V = \frac{20}{60}$ as before. The drainage tube was removed. At home he had occasional milder returns of his headache, and the skin of the mastoid continued swollen. Feb. 11th fluctuation was felt, the wound was opened with a probe in its lower part, and pressure on the upper part brought out a few drops of thick pus. He had had more pain in mastoid and head. The discharge soon stopped and the exploring probe felt smooth

bone. The bulging and redness of the drum-membrane slowly diminished. Five months after the operation there was no pain, no swelling of mastoid, membrana tympani still somewhat bulging, $V=\frac{20}{60}$.

At my request, the patient came again for an examination on Sept. 15, 1891. He had severe headache at long intervals, no pain in or around the ear, his hearing and general health had been good. The mastoid was normal, the membrana tympani in proper position, no more bulging in upper part, the membrane somewhat dull, that of the other side being pearly, translucent, and distinctly sunken. The hearing was the same on both sides, viz.: $H=\frac{4}{24}$ and $V=\frac{20}{20}$.

REMARKS.

This case was one of congestive mastoiditis interna, which, when protracted, leads to sclerosis. The most conspicuous symptom of these cases is obstinate, more or less intense headache, with moderate tenderness and swelling of the mastoid region, and bulging and hyperemia in the postero-superior part of the drumhead. Though the symptoms are never alarming, yet the headache in some instances is so distressing and persistent, making the patients unfit for any kind of work, that a number of such cases are on record—I remember two of my own practice—in which the mastoid has been opened and nothing was found but more or less compact, very vascular bone substance. The headache, starting from the mastoid region, and the occasional swelling and tenderness over the process, point to this place as the seat of the trouble, and the operation, though disappointing by the absence of the expected pus, has most satisfactorily relieved the patients of their headache and aprosexia. In a former publication (Arch. of Otol., X., p. 369, 1881) I declared the intentional opening of the

mastoid in sclerosing mastoiditis to be a justifiable operation. "The indication would chiefly lie in the persistent pain, centering in the mastoid and thence radiating over the head." Another (unpublished) case and the one under consideration can be cited in support of this statement.

MASTOID CASES.

By Clarence J. Blake, M. D., *Boston, Mass.*

The attention which has been given to the question of operation in cases of mastoid disease and the increase of the literature on this subject, especially during the past ten years, are evidences both of its importance aud of the proper recognition thereof. Whatever may be the difference of opinion among writers as to the method of effecting the simple purpose in hand, all seem to agree that whatever the difficulties of the operation itself may be, they are less than is the judicious solving of the question as to the limit between simple anti-phlogistic measures and the need of surgical interference. The history of long lists of fatal results following mastoid disease not operated upon, on the one hand, and the steadily augmenting reports of successful results in operative cases, on the other, are growing arguments in favor of surgical treatment in the early stages of inflammation of the mastoid cells.

When we consider that the initial inflammation occurs, in the majority of cases, in that portion of the mastoid cavity most remote from its outer surface and nearest to the brain, and that carefully prepared sections of innumerable temporal bones show that in by far the larger number this region is made up of minute cells with thin and easily destructible bony walls covered with highly vascular membrane, the blood supply of which is in more or less direct communication with that of the cranial cavity, the argument in favor of forestalling the effort of nature, which involves the often slow extension of the inflammatory process outward, is very much strengthened.

The efficacy of the Wilde's incision as a purely anti-phlogistic measure has led to its being depended upon in many cases where it should have been but the first step in a mastoid operation; indeed, there are cases, not by any means common, it is true, in which the drilling of the mastoid, under proper antiseptic precautions of course, has seemed to be the only measure which would sufficiently meet the demand for a considerable and rapid depletion, and has been of the greatest service. In my own experience with the use of leeches and cold applications as preliminaries, I find it a good rule never to make a Wilde's incision, so called, without both expecting and being prepared to go further.

A review of recent publications on the subject of artificial perforation of the mastoid process, and the inspection of any of our large aural clinics having interchangeable services, show considerable differences of opinion among surgeons as to the indications for and the method of procedure in the mastoid operation, and the extent to which interference should be carried.

Setting aside these minutiæ and viewing the operation from the standpoint of a simple surgical procedure, it may be said to be called for under the following conditions: Firstly, as a means of phlebotomy; secondly, to check an inflammatory process in the mastoid and ward off its possible serious results; or, thirdly, to remove the consequences of the inflammatory process in the form of retained pus and necrotic bone.

In the first of these three instances, the operation need be carried only far enough to secure free depletion; in the two latter instances, it will have failed of its true purpose as a surgical procedure unless the removal of the diseased parts is made as thorough and as complete as is consistent with the immediate safety of the patient, it being by no means overlooked that while this region bears very

hazardous relations to other important parts, recent experience has shown that their invasion is by no means so serious or possibly fatal a matter as was at one time supposed.

With the present community of knowledge in all scientific matters, one of the great values of personal experience is its use for purposes of comparison, since, where the general course of procedure in any given direction may be the same, the minor opinions as to methods are often greatly increased in value when subjected to comparison and discussion.

The ordinary routine of practice includes many experiences which would be very valuable for reference and comparison, were they more clearly defined, and this is an argument in favor of, and an excuse for, those detailed reports of cases which sometimes seem burdensome, — especially so if they have been selected and set aside for the illustration of some particular point; but it is the daily practical experience, including both success and failure, which is most valuable for purposes of criticism.

This is, in one sense, the reason for presenting the thirty consecutive cases of mastoid disease which have come under my personal care during the present year, twenty-three of which required operation.

In reference to the general course of procedure in the operative cases it may be briefly stated that all the operations, with one exception, were done under ether and that in all of them the simplest antiseptic precautions were observed, the mastoid region being first shaved carefully, then scrubbed thoroughly and douched with hot water, and the hairy portion of the scalp covered with tightly stretched rubber tissue.

The instruments which would probably be required during the operation, and which preferably had been previously boiled in soda solution, were placed in a shallow, cloth-

covered tray and submerged in a 1 to 20 carbolic solution one-half hour before the operation, when possible; these instruments consisted of scalpels, one with a very slender, narrow blade; one-half dozen or more of ordinary nippers, two broad curved retractors, large sized Bowman probes, a fine steel probe, a curved steel explorer, hand drills, three sizes, three, four, and six millimeters wide respectively; gouge-shaped chisels, and large, medium, and small, sharp spoons; other instruments which might, in addition, be possibly required were placed in a similar tray. Just before the operation, these trays, with the instruments, were flushed with boiling water; boiling water was also poured into the irrigator used for flushing during and for final douching after the operation, and into a bowl containing previously boiled and carbolized sponges. The hands of the surgeon and his assistants were thoroughly cleansed, and the neck and shoulders of the patient, and portions of the bed or table with which the instruments might come in contact, were covered with moist antiseptic towels.

The incision was always intended to be a little larger than might ordinarily be required for working purposes, was made with as few strokes as possible to secure clean surfaces, and its lower end was cut upon the slant, to favor subsequent drainage. Hemorrhage from the flaps was ordinarily controlled by means of nippers and sponging with very hot water, and by the use of the broad, smooth retractors, which were used also to expose the bone freely in order that its surface, in default of any special indication of disease, might be carefully searched by means of the explorer and fine probes for the purpose of determining, if possible, the existence of any small sinus which might otherwise escape detection.

The first opening into the bone, when this was still imperforate, was usually made by means of the smallest

hand drill, enlarged by the larger drills, and then further extended by means of the gouge and chisel, the chiselling being done preferably with a small light mallet striking short frequent blows, cutting done in this manner being rapid and with the least shock to the parts.

Within the mastoid cavity the operation was continued so far as possible solely by means of sharp spoons, the drill and the chisel being used to supplement them only, and the curetting being continued in whatever direction might be indicated as a general rule, until the diseased bone was entirely removed; in three of the cases hereafter reported the removal of a portion of the inner wall, and in one of almost the entire mastoid being necessary.[1]

At the conclusion of the operation, which had been when needed and, therefore, in a great majority of cases, immediately preceded by incision of the membrana tympani, the wound and the ear were thoroughly douched with warm water, an effort being made to secure a free passage through the antrum, except in certain of the acute cases with very considerable swelling of the mucous membrane in that region, previous experience having shown in some of such cases that recovery was more rapid without this interference.

The ear itself was carefully dried, plugged with a pledget of cotton or baked gauze, and baked gauze dressings applied over the mastoid region and the ear, in some few cases corrosive being used instead of the baked gauze; in no case were drainage tubes or gauze introduced into the wound, and no stitches were used. Twenty-four hours after the operation, unless previously required, the wound was reopened and explored by means of a probe and syringed with weak corrosive or, preferably, weak per-

[1] The handles of all the instruments used are preferably of metal, smooth finished, and with a smooth gouged or undulated surface in place of the usual serrations, the maker's name even being omitted.

manganate solution, subsequent drainage being insured sufficiently in all cases by the daily probing, the wound being allowed to close from within and above as rapidly as possible, care being taken to preserve, however, by use of the probe at the daily dressing, a sufficient external opening to permit of free drainage and to allow the use of the curette should any smaller spiculæ of bone, detached subsequently to the operation and detected by the probing, require removal. With the cases thoroughly curetted this was rarely necessary.

The best results as to time of recovery, including complete healing of the wound to the surface, were, of the twenty-three cases, one in six, one in seven, one in nine, one in eleven, and three in thirteen days after the operation.[1]

Case I.—Boy, six months of age, was first seen Jan. 15th, 1891, on account of suppurative otitis media with free discharge, and with some redness behind both ears. Ordered syringing with weak bicarbonate solution. (Child nursed well and was well nourished.) Jan. 19th, redness and swelling had both disappeared, and the discharge had decreased. Jan. 22d, post-aural swelling on both sides had returned with fluctuation and increase of muco-purulent discharge and operation was evidently necessary, and was done without ether. An incision was made one-half

[1] There are two points in the cases here reported, to which attention may be directed. First, the location and character of the preliminary incision in the membrana tympani; free, following the curve of the periphery from the short process, very nearly backward, and affording not only free drainage but an opportunity to carry the incision within the tympanum upward and backward to the antrum, through the thickened reduplications which have been shown to exist in the great majority of cases, and, second, the free use of sharp spoons made with a considerable convexity and a long anterior lip, the handles of the spoons being gouged on the side toward the cutting edge of the spoon and smooth finished.

inch behind each ear with free discharge of pus; bare and crumbling bone was found to the full limit of the incision on the right side, while on the left side there was a comparatively small surface of bone of the same character. In both instances, the diseased bone was thoroughly removed by means of the sharp spoon, and weak corrosive sublimate solution was syringed from the meatus to the wound behind the ear in both directions.

The subsequent treatment consisted in syringing the ears and wounds until the latter began to close in with firm granulation tissue. Recovery was slow, both wounds having closed at the end of two months. After the first three days the permanganate solution was substituted in syringing and dressing, and the syringing was omitted and a probe only used daily, after the appearance of laudable pus, with other evidences that the wound was healing from the bottom. General treatment consisted in administration of small quantities of iodide of iron and, later, of cod liver oil emulsion.

Case II.—Woman, single, 25 years of age, slender, fair complexion, well nourished, and in good health until a little more than a year ago, when she had nervous prostration in a mild degree, recovered, and relapsed a year later. On December 26th, the patient was attacked by a severe pain in the left ear, following a very hard cold contracted in the latter part of November. This pain had continued with periods of spontaneous relief until recently, when it had increased and extended to the mastoid, the left side of her head, the left eye, and had made sleep without opiates impossible. The diagnosis being inflammation of the middle ear of slow progress, and periostitis with mastoid complications, operation was done under ether on Jan. 31st, 1891. The membrana tympani was first incised, with free bleeding but no purulent discharge. An incision was

then made about an inch and a half long, three-fourths of an inch behind the line of junction of the external ear and the surface of the mastoid process. By means of the drill, chisel, and gouge, the mastoid process was perforated and curetted along the line indicated by inflamed bone, but no pus was found until the antrum was reached: the wound was then syringed out with a solution of corrosive sublimate, 1 to 1,000, and an antiseptic poultice was placed over the whole mastoid region.

The subsequent dressing and care of this case was under direction of Dr. Van Hoosen of the New England Hospital for Women, where the operation was done, the ear was douched twice daily and the wound once daily. Several small sloughs were removed in this way, though comparatively little pus was seen. The patient had no pain in the mastoid region or head after the operation, slept well without opiates, and made a complete recovery in seven days.

Case III.—Woman, 26 years, single, slender, and well nourished. Was first seen March 3d, 1891, with recurrence of old suppuration of the left middle ear, with very considerable swelling of the mucous membrane of the tympanum and with mastoid tenderness. A free incision in the posterior portion of the membrana tympani was followed a few days later by hernia of the mucous membrane, resembling a hard mucous polyp. This was snared with considerable relief to the sense of fullness in the head, and lessening of the mastoid tenderness. Temperature, 98.4°. March 12th. The relief afforded by the use of the snare continued until last night, when the pain in and behind the ear recurred with much increase of mastoid tenderness, the opening in the drumhead remaining free.

March 13. Operation. Vertical incision over the centre of mastoid, bone of cortex clear and hard but oozing freely under drill, no pus found until the small drill had been passed well in towards the antrum, upward and for-

ward; after enlarging the opening in the cortex by means of the chisel, the sharp spoon was freely used until all apparently affected bone had been removed. Syringing from wound through the antrum was impeded by the considerable swelling of the mucous membrane at that point and was not, therefore, persisted in. On the following day, the patient was entirely free from pain, and had slept well. The temperature, which had been 100° at the time of the operation, was normal, and the appetite was good, the discharge from the ear had nearly ceased and was slight from the wound. The subsequent treatment consisted merely in syringing the ear with weak permanganate solution, in the daily probing of the wound to insure drainage, and in general treatment in the way of diet and simple tonics.

March 26th, patient discharged, with the ear dry and wound healed.

Case IV.—Boy, 14 years of age, strong and well developed. Three weeks since, as the result of measles, he had, while away from home at school, an acute suppurative inflammation of the left ear. This had resulted in implication of the mastoid, and when seen, March 17th, 1891, there was a free muco-purulent discharge from the left ear, and considerable swelling, especially over the posterior portion of the mastoid surface, including the region of the digastric fossa; the swelling was principally œdematous, but at the point last mentioned there was marked fluctuation and, correspondingly, indication of spontaneous perforation at this point; the pain in and tenderness of the mastoid region were considerable and the temperature was 101.2°. Under these conditions immediate operation under ether was decided upon, the first step, as usual, being a free incision in the posterior superior portion of the membrana tympani, following the curve of its periphery. The

incision behind the ear was made rather longer than usual in ordinary cases, and was carried backward in its lower portion very nearly to the limit of the mastoid outline, in order to include the point of greatest swelling and probable spontaneous opening, and to permit entrance into the mastoid from below, should that seem necessary. This incision liberated at the point of fluctuation, previously mentioned, one drachm of pus. The soft parts were very much swollen and firm, and but for the length of the incision would have rendered retraction and a clear field for operation difficult of accomplishment. The bone, which was found to be oozing freely, especially in the neighborhood of a minute sinus, just above the upper limit of the digastric fossa, was perforated by the small and then by the large drill, and this opening was considerably enlarged both upward and forward wherever the cortex was found to be soft, the use of the drill and chisel being followed up by small and large sharp spoons until there was no further evidence of diseased bone remaining as appreciable by either spoon or probe; the operation included the establishment of a free passage through the antrum, and syringing through from the wound to the ear was freely accomplished. The temperature the day after the operation was normal, and the patient was free from pain. The subsequent treatment consisted in the syringing of the ear and wound with weak permanganate solution and daily probing of the wound to insure drainage; the syringing was omitted at the end of a week, and at the end of two weeks probing was no longer necessary. The patient made a good recovery, both as to hearing and freedom from subsequent trouble as to mastoid symptoms.

Case V.—Woman, 35 years of age, married, stout, but not strong, and with a nursing baby five weeks old, was first seen in consultation March 31st, 1891.

The patient had a previous history of an acute suppurative inflammation of the middle ear of seven weeks' duration and an existing condition of considerable œdema of the posterior superior wall of the canal, and swelling and tenderness of the mastoid region, especially in the neighborhood of the digastric fossa.

She was sent at once to the New England Hospital for Women and operated upon under ether the following morning.

The opening in the membrana tympani was first enlarged and a long semi-lunar incision was then made behind the ear, extending backward at its lower end as far as the posterior mastoid outline.

The bone at this point was somewhat congested, broke down freely under the chisel and gouge, and gave exit to about one drachm of pus.

The mastoid cavity was curetted until only hard bone was felt and a stream of water could be passed freely through the mastoid antrum.

The relief afforded by the operation was considerable, and the patient, notwithstanding the general unfavorable circumstances, was discharged from the hospital April 17th, in good condition, her treatment after the operation, syringing and probing, being in the hands of Dr. Van Hoosen, to whom I am indebted for careful attention to, and the reports of, this case and one of the preceding cases.

Case VI.—Woman, 26 years of age, married. The patient had trouble with the ears for the five or six weeks preceding, with much pain and a very profuse discharge. She was delivered of a healthy child five weeks before and was still flowing when first seen, May 7th, 1891. She was anæmic and very nervous. There was no discharge from the right ear. The left canal was filled with discharge and no perforation could be seen on account of the

œdema of the walls. There was also a red, hot, non-fluctuating swelling over the mastoid and pain shooting down the neck and up over the side of the head. Operation was advised after leeching, Leiter's coil, and other means had failed to relieve the symptoms.

May 10. Operation under ether included the usual incision, followed by the escape of a considerable amount of pus. A sinus was found at about the centre of the outer table of the mastoid, at which point the drill entered the bone easily and liberated considerable pus. The operation was continued by means of the gouge, mallet, and curette, and free communication was established with the antrum and the parts were thoroughly flushed by hot water irrigation. Bleeding from the flaps was checked by means of hot sponges, as in similar cases. Dry baked dressing. Paracentesis of the posterior fold of the membrana tympani preceded the mastoid operation.

May 11. There has been no pain since the operation. When dressed there was very little discharge from the wound and none from the meatus. The wound was syringed with permanganate solution from this date.

May 20. No discharge from meatus or mastoid since last dressing, but some sloughing of the edges of the wound in consequence of the water having been too hot when used at time of operation. No syringing for several days. Iodoform to edges of wound. No bone felt for several days.

May 23. Wound of operation closed with granulations, no bone felt with probe. Canal wall slightly swollen; no perforation in membrana tympani. $W = \text{R } \frac{12}{60}$, $\text{L } \frac{1}{60}$.

Discharged to out-patient department Massachusetts Charitable Eye and Ear Infirmary.[1]

---

[1]Last seen in O. P. D. about middle of June. $W = \frac{60}{60}$ right ear; $\frac{20}{60}$ left ear. Hearing was steadily improving but patient did not return again.

Case VII.—Man, 30 years of age. Short, stout, and florid; moderate smoker and occasional drinker.

November 10, 1890. Patient first seen in consultation with a local practitioner. There was from the left ear free purulent discharge, which came through a nipple-shaped opening in the posterior superior portion of the membrana tympani. The degree of swelling of the tympanic mucous membrane and the œdema of the canal indicated the advisability of a free incision in the drumhead; this was accordingly done and supplemented by divisions of the swollen mucous membrane, upward and backward.

The incision was subsequently repeated with good results, and the discharge from the ear nearly ceased, but on April 4th, 1891, the patient reappeared with free muco-purulent discharge, considerable swelling of the canal, and swelling, redness, and tenderness of the mastoid, with, at one point, over its centre and backward, evidence of fluctuation; the pain, which had been considerable for two days and was referred principally to the mastoid region, having however decreased within twenty-four hours. Temperature was 101.8°. Local symptoms indicated spontaneous perforation of the cortex, and an operation was decided on for the following day.

April 5. Operation, under ether. Patient etherized badly, and there was, consequently, much venous oozing from the swollen and engorged tissues, which prolonged the operation. The bone was found to be softened for a considerable distance about the small opening, through which the pus had made its exit, and broke down readily under the use of the gouge, and even under the knife at the first incision; the cavity of the mastoid, which was filled with pus, needed to be very completely curetted out, both backward and downward, as well as in the direction of the mastoid antrum. Syringing through from the wound to the ear was effected in this case, as in many

others of a similar class, only under considerable pressure, on account of the swelling of the mucous membrane in the tympanum, and despite the very free incision made through the membrana tympani, as usual, as a first step of the operation.

Subsequent treatment consisted in the usual probing for maintenance of drainage and in syringing with permanganate solution, and the superficial use of dry baked dressings; the only other treatment required being attention to diet and the occasional administration of a cathartic, as the patient slept well without opiates the night after the operation, had no subsequent pain except at the time of dressing, and returned home at the end of ten days with the ear completely, and the wound all but superficially, healed.

Case VIII.—Boy, 4 years of age, slender, but well nourished. First seen April 9th, 1891, in consultation with his father, who was a physician. There was a free muco-purulent discharge from the left ear, much œdematous swelling over and behind the mastoid, and a history of pain in the mastoid region beginning five days previously. Operation was evidently demanded, and performed under ether the same afternoon, and included, in addition to the enlargement of the opening in the membrana tympani, an incision something more than one inch in length through the region of the greatest mastoid swelling. The outer surface of the mastoid gave no evidence of an attempt at spontaneous perforation beyond slight oozing at the upper portion of the exposed bone under examination with a steel probe; this point, therefore, was chosen for opening with the drill, subsequent enlargement downward with the chisel, if necessary, being easily provided for. No pus was found until the antrum was reached, and then only a few drops, but the passage through the mastoid cells and the process of reaching the

antrum showed the bone to be considerably softened and readily breaking down; a sharp spoon, therefore, was freely used through the opening in the cortex, enlarged by means of the chisel for the purpose, and all crumbling, and a few pieces of loose bone, removed down to a smooth surface. Subsequent treatment consisted in probing and syringing as in the cases previously mentioned, and the child progressed favorably, with a closure of the wound some time within four weeks after the operation, the exact date not being known, as the child had recovered sufficiently at the end of a week to be taken home.

Case IX.—Man, 56 years of age. This patient was first seen in consultation June 16th, 1891, with acute inflammation of the right middle ear and with a mucopurulent discharge through a perforation in the posterior superior segment of the membrana tympani; the discharge was free and the previous pain in the ear had ceased with this occurrence; there was no mastoid tenderness, and the patient was improving in general condition from the consequences of an attack of la grippe. Upon syringing with weak bi-carbonate solution, the discharge from the ear decreased, and finally ceased, during a convalescent trip to Norfolk., Va., upon his return from which the ear was found to be clear, dry, with the perforation healed and hearing improved.

The patient again left the city for a visit to New Haven, and while there, had renewal of the pain in the ear, extending into the mastoid, was very kindly seen by Dr. Carmalt, and subsequently returned to Boston and was again examined, July 17th.

The right membrana tympani appeared clear, except for a slight reddish tinge showing through the posterior superior portion, and the hearing was somewhat better

than when last seen: over the centre and upper portion of the mastoid was a deep-seated, tense, fluctuating swelling. The pain for the two previous nights had been severe and the temperature was 99.8°.

Operation upon the mastoid was advised and was done under ether on the afternoon of the following day, the first step being a semi-lunar incision in the membrana tympani, running from the short process downward and backward to below the median horizontal line.

The incision behind the ear followed the curve of the auricle from the line of its upper margin to the tip of the mastoid; neither ligatures nor forceps were required, broad retractors and sponging with very hot water being sufficient to control the bleeding, as in the majority of cases. From the upper end of the cut, about one-half drachm of pus escaped, and here was found a small, rough depression of the bone, which, below this point, was firm, hard, and clear.

Careful searching of the rough depression by means of a fine probe and explorer failed to reveal any sinus opening into the mastoid, but the symptoms and conditions pointed so conclusively to the existence of some such opening, however microscopic, and recalled the experience of presumably similar cases where a sinus from the upper portion of the mastoid had been traced downward and inward, that the opening was made with a drill in this case also, about one-half inch below this rough spot.

The opening made with a small and large drill passed through firm bone and was enlarged upward in the cortex by means of the chisel and mallet, the soft bone searched for being found only when close into the antrum.

The operation, which was unusually long, lasted one hour, and was concluded by dry dressing, without syringing.

July 19th. Patient slept well; temperature 88.9°; pulse

66; no pain, soreness about the wound only; syringing the ear and through the wound into the ear with corrosive sublimate solution brought away some pus, a little blood, and such masses of desquammated epithelium as might come from an epithelial plug in the antrum.

July 20th. Less discharge from the ear, slight from the wound, free drainage, temperature normal, no pain.

July 21st. No discharge from the ear, still less from the wound.

July 22d. Ear dry and perforation healed, wound behind the ear rapidly closing in from the bottom.

July 26th. Patient discharged; no further probing necessary.

This, and the following case, are especially fortunate in illustrating the value of free incision of the membrana tympani in such position as to afford the best opportunity for drainage from the antrum in one direction, and of the very free and complete curetting of the mastoid cavity, which makes a similar provision in the other.

This having been provided, the use of the probe, and, for a time, of the syringe, daily, to a sufficient extent to ensure the maintenance of the drainage (a method of dressing which need not be painful or harassing to the patient), is as a rule all that is subsequently necessary.

In the following case, as will be seen, an accidental occurrence suggests the possibility of abandonment, at a much earlier period than might otherwise seem advisable, of the probing and syringing after operation.

Case X.—Man, 30 years of age. Musician. Slender, of nervous temperament. Had, after a prolonged period of over-strain from work and exposure to cold, an acute congestion of the right middle ear, characteristic in the character of its onset and the severity of its symptoms, of those acute congestions in which there is a suspense of vaso-motor inhibition as the intrinsic cause.

The membrana tympani was clear, transparent, congested at its posterior superior periphery, and somewhat œdematous in the same region, below which could be seen the pinkish color of the injected tympanic mucous membrane; there were the usual symptoms of the sense of fullness, impairment of hearing, tinnitus aurium, and pain in the middle ear, extending forward and upward; this pain was only partially relieved by an incision through the swollen parts of the membrana tympani and the free serosanguinolent discharge which followed and which was encouraged by the use of dry drainage wicks.

The serous discharge continued for several days, the pain gradually decreasing until, a muco-purulent discharge having been fairly established with a nipple-like projection at the point of incision, pain in the ear recurred with some severity, and was referred not only to the ear but also to the mastoid region.

An incision of the nipple gave partial and temporary relief, and was repeated, but the mastoid symptoms—especially localization of the pain and tenderness, and a slight blush over the spot corresponding to the position of the antrum—continuing, together with a rise of temperature and extension of pain to the vertex, a mastoid operation was evidently decidedly advisable.

February 24th, 1891. Under ether a free semi-lunar incision was made in the right membrana tympani, a further cut with a curved spatula knife being carried upward toward the antrum, dividing the swollen folds of mucous membrane.

The incision over the mastoid one-half inch back of the auricle, and one and one-fourth inches long, revealed clear, firm bone, with the exception of a small reddish area toward the upper and anterior portion of the mastoid.

An opening made with a small and then a large drill, one-fourth of an inch below this point, was enlarged

upward with the chisel and carried inward by means of the sharp spoon, supplemented by careful use of the drill.

No pus was found until the antrum was reached, although there were evidences in the portion of the mastoid traversed, of softening of the bone to an extent which required very free curetting of that cavity.

After operation, syringing with corrosive sublimate and, subsequently, with weak permanganate solution, passed freely through between the ear and wound, and the drainage of the latter was further assured by daily probing.

On the fourth day after the operation, however, when the case was progressing most favorably in all respects, even the use of the probe was put a stop to by the supervention of the accident alluded to; namely, the appearance of a slight erysipelatous blush in the right parietal region, accompanied by rise of temperature, slight chilliness, and other usual concomitant symptoms.

At the end of twenty-four hours the erysipelatous inflammation had spread over the mastoid and right ear, and was beginning to invade the temporal region and face; probing of the wound or any meddling with it being inadvisable, especially since it was dry and clean, weak corrosive sublimate dressings were continued and attention directed to the requisite general treatment of the patient.

At the time of the appearance of the erysipelas, the wound had already begun to close satisfactorily from the bottom, there was but a minimum of discharge, the patient was entirely free from pain, and had a very nearly normal temperature. At the end of ten days, with a cessation of the active symptoms of erysipelas, the wound behind the ear had entirely healed, there was no discharge whatever from the ear itself, and the hearing was steadily improving.

At the time of the present writing, the hearing is so far

restored as to make its use for professional purposes perfectly satisfactory.

In this case, therefore, the efficacy of very complete removal of all diseased tissue was accidentally illustrated by the fact that the demand for drainage facilities was so far reduced as to give a favorable result within only three days after treatment.

Case XI. — Woman, 19 years of age, single.

May 12. This patient came to the out-patient department of the Massachusetts Charitable Eye and Ear Infirmary in January with otitis media acuta and mastoid symptoms. She made one visit then and did not appear again until May 10th, 1891. For the week previous she had great pain in and back of the ear, and entered the hospital with a red, hot, fluctuating swelling over the left mastoid, œdema of the left canal with purulent discharge. No perforation could be detected in the membrana tympani on account of the swelling in the canal. Operation was advised and accepted by the patient.

Operation under ether. The usual incision was followed by escape of pus and very free bleeding, and a sinus was found at the level of the external meatus (although the external swelling was high up). Entrance of the drill through the cortex gave free exit to pus and free communication with the antrum, which was further ensured by free curetting. Hot water irrigation followed the operation, which was preceded by free semi-lunar incision of the posterior portion of the membrana tympani.

May 20. No discharge from ear or mastoid since the second day. Slight sloughing of edges of wound from effects of hot water. Wound nearly closed.

May 23d. Condition much the same as at last note. Discharged with collodion dressing, to report in out-patient department.[1]

[1] Patient only reported to out-patient department once after discharge from the house, and was then in good condition.

Case XII.—Man, 17 years of age. A good history could not be obtained from this patient, who first had ear trouble on the steamer, coming to this country, where he landed three days before his appearance at the Infirmary. His general health was reported as good. There was purulent discharge from the right ear, the canal was swollen, and there was a large, fluctuating swelling over the right mastoid, very tender on pressure. Operation under ether was advised and done April 21, 1891. The usual incision showed the tissues to be very thick and vascular over the mastoid. The bone was opened by means of the drill, liberating pus from the cells. The gouge and mallet, followed by the curette, were also used, as the mastoid was apparently subdivided by a perpendicular wall of bone, the removal of which was necessary to effect the opening established with the antrum. Dry dressings, no drainage tube.

April 23. No pain since operation; almost no discharge from ear, from the mastoid very slight. Œdema of canal wall gone. Daily dressing.

May 1. No pain or discharge from either ear or mastoid for the last five days. No œdema of canal. The membrana tympani has a normal lustre and appearance; there remains a small sinus leading to the bone in the mastoid, but no discharge. Collodion dressing.

Discharged to out-patient department.

May 9. Wound tightly closed. *W* after catheterization $=\frac{12}{60}$. No subjective symptons. Patient never returned to out-patient department after this date.

Case XIII.—Man, 35 years of age. Has had ear trouble for four weeks previous to date (May 28, 1891), and entered the out-patient department of the Massachusetts Charitable Eye and Ear Infirmary on account of chronic suppurative otitis media, with a brawny digastric

fossa and tenderness over the mastoid, and was admitted to the house. The canal was filled with a sero-purulent discharge, there was some œdema of the canal wall, a nipple in the posterior superior portion of the membrana tympani, and the mastoid tip was tender on pressure. Ordered douche every two hours. Leiter coil, cold. One leech to mastoid.

May 30. Less pain since entrance, nipple resolving, discharge increasing. Has slept well without opiates.

June 2. Since last note, the swelling in the canal had remained about the same. In the neck it had steadily increased, until it reached a point about half way to the clavicle but was neither fluctuating nor tender. Operation under ether was advised and accepted by the patient. A very long incision was made on account of the great length of the mastoid, the drill opening was made at a point about opposite the external meatus and followed by use of the gouge and curette, and a considerable quantity of pus was found in the cells. In this case also the mastoid was apparently subdivided by a bony partition which had to be removed before communication could be established with the antrum. The nipple in the membrana tympani was freely incised before the mastoid was opened.

June 6. No pain since the operation and no discharge from the mastoid wound since the day following it. The wound was kept open by daily probing, and was not syringed. The discharge from the canal decreased and the nipple resolved. Temperature normal.

June 12. The membrana tympani was clear and there was no discharge from ear or mastoid.

June 15. Slight muco-purulent discharge from ear; wound dry and nearly healed.[1]

---

[1] Last seen in out-patient department about middle of July: membrana tympani clear and transparent, except at lower posterior segment, where there is the scar of the old perforation. $W=\frac{2}{60}$ and hearing steadily improving.

Case XIV.—Man, 52 years of age. The left ear first began to trouble the patient when at sea four weeks since (May 23, 1891). He had two chills, violent pain in the ear, not relieved by the occurrence of discharge, and was unable to do his work. Paracentesis of the membrana tympani and leeches to the mastoid failed to give relief and on May 23 he had more pain, mastoid tenderness without redness or swelling except on the posterior wall of the canal, and a pulse of 100 and temperature of 99.8°. A Leiter coil was ordered and hot douche every two hours, also opiates as needed.

May 24. Had a chill during the night, and rise of temperature to 103.5°, with complaint of great pain in the head, the pulse was 56, strong and full, other symptoms as before. The left pupil was slightly larger than the right. but both reacted well. On account of pain and the chill, immediate operation under ether was advised and accepted by the patient.

The usual incision showed the mastoid cortex to be firm and clear but the drill released a few drops of pus, which came out apparently under great pressure. The cortex was very thick and the chisel was freely used, especially as this mastoid was also divided by a vertical wall, which was by this means broken down and free communication established with the antrum. In this case, as in the previous cases, the curetting constituted the second stage of the operation. Hot water irrigation. Dry dressing. Free incision of membrana tympani before operation.

May 26. The patient's condition was much the same as before the operation, except that the pain behind the ear was less. Left pupil not so large as before, pulse 56–64, strong and full. Daily dressing. Temperature 99°–100°; but during the night it rose to 102.5° without chill.

June 1. Wound nearly closed. Less discharge from the ear. No bone felt with the probe. Still complained of pain.

Temperature normal. Able to be up and about the ward four hours daily.

June 5. Wound firmly closed with granulations. Still complained of some pain in the left side of the head at intervals. Resolving nipple in the canal.

June 6. Some pain last night; no opiates.

June 7. Complained of pain. A sinus was discovered behind the ear which did not lead to bare bone. Syringed with permanganate solution.

June 14. Was up and about the ward. Complained of great pain at all times and that it kept him awake at night, but he has shown no outward signs of pain in the day time and certainly sleeps well at night.

July 14. Still complained of constant pain in the head. Sinus closing in slowly. No bone to be felt at bottom, slight purulent discharge. No discharge from meatus.

Discharged to out-patient department.

July 24. Pain is reported to have increased last night; this morning paracentesis of the membrana tympani liberated bloody serum. The sinus remains the same as before.

July 30. Sinus as before. No pain at all for last two days.[1]

Case XV.—Man, 50 years of age, tall, slender, and showing evidences of overwork and poor health. The patient reports a past history which confirms these appearances and, furthermore, that in April last he had severe pain in the right ear, followed by discharge. During the last week in June he reported at the aural out-patient department with tenderness over the mastoid and tragus and with a nipple on the membrana tympani; he was relieved by leeches and incision of the nipple, but on July 4th he

[1]Seen in out-patient department once in August. Sinus closing in, no discharge from meatus. Complains of pain in temporal region. Has been at work since discharge from the house.

was much disturbed by the noise in the street, which gave him a peculiar sense of discomfort in the ear, followed by nausea and vomiting. These symptoms continued to increase until he was unable to move his head upon the pillow without exciting vomiting, and as the pain in the head and the mastoid tenderness also increased, an operation under ether was decided upon and performed July 7th, 1891, consisting of the usual longitudinal incision and drilling of the firm cortex, followed by curetting upward and forward into the antrum; the nipple in the membrana tympani having been previously incised, a free passage for irrigating fluid was provided from wound to ear. Dry baked dressing; no tube or sutures.

July 8. Pain, nausea, and vertigo much relieved, discharge from ear less.

July 10. Mastoid wound granulating well from bottom.

July 12. Able to sit up; no pain; no nausea; slight vertigo and tinnitus only.

July 16. No discharge from either wound or mastoid.

August 1. Has been kept as house patient on account of general weakness and slight vertigo. Discharged to out-patient department.

Case XVI.—Boy, 16 years of age. For ten days the patient has had constant pain in his left ear and has for four days been seen in the out-patient department. Was admitted to the house June 5th, 1891. Mastoid had a constant tender spot over the spot corresponding to the antrum, with free discharge from the ear and swollen canal. Temperature 101.2°. Ordered Leiter coil and douche of warm water every two hours to the canal.

June 6. Passed a good night; slept five hours. Temperature this morning 99°; last night, 102°. Still had a tender mastoid. Operation was advised, and accepted through an interpreter by a brother of the patient.

Ether. Usual incision, gouge, chisel, and curette. Extensive caries of mastoid and of posterior wall of the canal. Nearly the whole of the posterior wall of the canal was removed and the mastoid cavity curetted as thoroughly as possible. Dry dressing.

June 7. Much discharge from the ear and mastoid. Pus very fœtid. Dressing with permanganate syringing twice daily.

June 9. Up and about the ward. Wound clean and granulating in well. Discharge very fœtid.

June 12. Canal swollen, granulations in middle ear, discharge from ear and mastoid diminishing.

June 19. Wound nearly closed.

June 25. Wound firmly closed. Some swelling of the canal and profuse fœtid discharge. Syringe four times daily.

June 27. Condition the same. Discharged to out-patient department.[1]

Case XVII.—Girl, 18 years of age. The patient was first seen June 13th, with a history of otitis media acuta of the right ear in March last, and of discharge from the ear ever since. Two weeks ago she also had pain in the mastoid extending over the side of the head, and has entered for operation.

Operation. Ether. Pus came through under the knife. Outer walls thin. Chisel, gouge, and spoon removed all carious matter and opened through the posterior inner wall. Hot water irrigation, baked dressing. Operation was of forty minutes' duration. A long curved incision of the membrana tympani posteriorly was made before the mastoid operation.

---

[1] Aug. 27. Still had discharge from meatus. Stump of small polyp which was snared about August 1st. No mastoid symptoms since discharge. Otorrhœa no longer fœtid. Syringe once daily.

June 17. Discharge from the ear very slight, from the wound practically none.

June 20. Wound thoroughly granulated in, no bone felt, slight discharge from granulations behind the ear, no discharge from canal.

June 25. Membrana tympani clear and transparent, slightly retracted.

June 29. Discharged to out-patient department, collodion dressing to mastoid.

July 3. In out-patient department a. d. $W = \frac{24}{60}$ after catheter. *V* nearly normal.

July 12. Slight redness over mastoid with tenderness, relieved in one day by cold compress and catheter. No fluid in tympanum.

July 30. Treatment discontinued, good recovery.

Case XVIII.—Boy, 2 years of age. This child is well nourished, had history of ear trouble for some time past and had also had a small incision made over the mastoid by the family physician. Entered for operation June 2. The canal was filled with purulent discharge and there was œdema of the canal wall and considerable swelling over the mastoid, with a sinus, remnant of the previous incision, leading to bare bone.

Operation. Ether. Usual incision, free bleeding. The bone seemed perfectly sound except at one spot, where there was a slight, deep depression detected by the small probe, although the whole surface of the bone appeared roughened. The curette readily broke through at the spot mentioned and showed that the mastoid was a mere shell filled with very fœtid pus. The inner wall of the process was entirely removed for a considerable space, leaving the membranous wall of the sinus exposed. Free communication was established with the antrum and the wound and the ear flushed by irrigation. Dry dressing.

June 3. Free discharge of very fœtid pus from the ear

and mastoid. No pain. Dressing twice daily. Sy. ferri iodid. twice daily.

June 6. Wound granulating in quite rapidly. General condition good. Up and about ward.

June 12. Free discharge from ear and through mastoid.

June 19. Dressing once daily. Discharge much less. Slight amount of bare bone.

July 2. Condition same. Wound probed once daily.

July 25. Much less discharge from ear and wound, and less offensive.

August 8. Mastoid wound closed in.

Case XIX.—Boy, 2½ years of age. The following case illustrates the inefficiency of the simple Wilde's incision in cases of this class and is reported in full from the records of the aural department of the Massachusetts Charitable Eye and Ear Infirmary, where it was admitted May 12, with the following history:

"The left ear has discharged for a long time, and has been treated by a general practitioner. The patient came to the out-patient department with profuse purulent, offensive discharge, filling the left canal, large swelling over the mastoid, and paresis of the left facial nerve; was very anæmic and had a rising temperature. On account of the serious condition, immediate operation was advised, and performed under ether by Dr. F. L. Jack, assistant aural surgeon in Dr. Blake's service. The usual incision was followed by the escape of much pus, accompanied by free bleeding, and further exploration showed a large carious sinus involving almost the whole mastoid process. This was freely curetted in all directions and then syringed with permanganate solution, a drainage tube inserted, and dry dressing applied.

"May 20. Rallied well from the operation, and has had daily dressing since. Did well until within two days, when nausea, vomiting, and diarrhœa developed, with

temperature of 103° and intermitting pulse. Facial paresis better.

"May 25. Condition better. Very free, somewhat offensive discharge from the ear and mastoid. Permanganate syringing passes freely from the mastoid to the meatus. Dressing twice daily.

"June 2. General condition improved. Wound closing in; still very free, offensive discharge. Very little bone felt with the probe. Dressing twice daily.

"June 8. General condition improved, ear as at last note. Goes out of doors every pleasant day.

"In the interval between June 8 and June 29 the discharge from the ear increased with the appearance of a polypus springing from the posterior portion of the tympanum, which was repeatedly snared until July 29, when, on account of increase of the discharge and its very fœtid character, together with the fact that abundant bare bone could be felt forward in the mastoid and that the recurrence of the polyp in the region of the antrum persisted, a secondary operation was thought advisable and was performed under ether on the latter date by Dr. Blake. The external canal was found to be nearly filled by a polypus springing from posterior inferior wall of the tympanum, below a spot of necrosed bone leading up toward the antrum. The fistulous opening behind the ear was enlarged by the knife, upward and downward, and division of the cicatricial tissue within the mastoid was effected by the narrow knife, followed by free curetting downward and forward in the direction of the mastoid antrum, and upward where the incision had revealed spongy necrotic bone. Two sequestra were removed, one inward and downward, the other downward and forward. The polypus was removed by means of the small sharp spoon, through external auditory canal, and the posterior portion of the bony tympanic wall was thoroughly scraped. Warm

douching resulted in free passage of water from the mastoid opening down the throat and out at the meatus. The operation lasted twenty-eight minutes and was well borne. Pulse, 130–150. Enema of milk and brandy.

"August 1. Child in good condition, temperature 99.6°. No pain. Profuse discharge from wound and meatus. Dry dressing thrice daily.

"August 3. Free drainage from mastoid through middle ear and meatus; wound showed little sign of granulating. Child up and about ward.

"August 8. Abundant discharge; otherwise as before.

"August 16. Discharge somewhat less, general condition much improved. Began to play about ward for first time since entrance.

"Sept. 7. The condition has been much the same until to-day, when persistent nausea and vomiting again set in. There was no headache and the temperature was normal until —

"Sept. 12. Temperature 99.5°, child much weaker, at times comatose, and vomiting more persistently. From this date the temperature rose slowly until —

"Sept. 14. Temperature 105°, comatose. Cheyne-Stokes breathing at times during the night, and one opisthotonic convulsion, with at times tonic spasms of whole of the right side. Died 3 P. M. No autopsy."

From the history of the preceding case, with its evidence of the establishment of a necrotic process, the progress of which could not be checked by the thoroughness of the first operation, and which rendered the second operation necessary as a forlorn hope, two inferences are permissible, — one, that the constitution of the patient was one which would have rendered any surgical interference nugatory when the suppurative process had once been established, and the other, that, had the surgical interference in

the very beginning been as thorough as it should have been and the mastoid operation subsequently performed by Dr. Jack been done in place of the simple superficial opening, the final result might have been different.

The two following cases also bear evidence of the importance of early operation, and both illustrate the consequences of extension of the suppurative process downward from the tip of the mastoid.

Case XX.—Woman, 46 years of age, single. This patient was admitted to the Infirmary Jan. 28th, having had an acute inflammation of the right middle ear, with mastoid symptoms, for about two weeks previously. The mastoid was red and tender, the canal clear. There was a perforation in the posterior inferior segment of the membrana tympani and a sero-purulent discharge.

The mastoid symptoms disappeared under leeching, douching, and cold applications, but returned again three weeks later, together with an enlargement of the glands on the right side of the neck, which latter condition pertained at the time of my first examination of the case, April 4th.

The canal was somewhat closed by œdematous swelling, there was no perforation of the membrana tympani visible on this account, and there was a very profuse purulent discharge. The mastoid was tender only on deep pressure and there was a large brawny swelling in the region of the digastric fossa extending down into the neck.

From the history of the case and the present discomfort of the patient, operation under ether was advised, consented to, and performed the same afternoon.

With the long persistence of the mastoid disease it was to be expected that the bone would be found to give evidence of the prolonged inflammatory process to which it had been subject, as was found to be the case.

The parts having been shaved and scrubbed and the rubber head band having been applied, an incision about four inches in length was made rather far back over the right mastoid. The tissues, which were thickened and very vascular, were retracted and the bone exposed, revealing roughness over nearly the whole mastoid outer surface, with a small penetrating sinus about the level of the centre of the meatus. This sinus was enlarged with the drill and a large opening then made with the gouge and chisel, giving vent to a considerable amount of pus from the cell spaces of the mastoid. By means of sharp spoons, following a probe, a free opening was established with the tympanum, so that fluid could be syringed from the meatus through the mastoid opening.

August 5. Patient weak but much better than before the operation. Very much less pain. Wound dressed daily.

April 13. Sat up nearly all day. No swelling of neck for several days past. Mastoid opening granulating. Dressing daily.

May 24. Condition during the interval of record has been much the same as before until last night, when the swelling of the neck suddenly reappeared without pain or rise of temperature. For some time past a sequestrum had been felt in the mastoid and this had been curetted without ether. A secondary operation was advised, on account of the further extension of the necrotic process.

Under ether a long cut was made near the scar of the first operation, with very little bleeding. The tissues were retracted and with gouge and mallet a large opening was made in the mastoid and the diseased bone was thoroughly curetted out. Much carious bone was found in all directions but especially toward the tip of the mastoid, the greater part of which portion of the process was removed.

June 1. Ends of wound closed in; mastoid granulating. Very free discharge, daily dressing.

June 7. Mastoid granulating quite rapidly. Very slight pain in forehead.

June 15. Syringing fluid will not pass from the mastoid to the meatus.

June 29. Mastoid wound nearly granulated. Very slight amount of bare bone to be felt.

July 7. Condition about the same. Middle ear syringe used twice daily. Discharge from mastoid slight.

July 18. Wound firmly closed in, tissues movable over mastoid. Discharge from ear much less. Syringing of ear thrice daily.

July 20. Perforation in the membrana tympani forward of the malleus and in about the middle of the membrane was enlarged by paracentesis in order to secure a better drainage. Discharge from ear less, and patient free from pain.[1]

Case XXI. — Woman, 52 years of age, married. This patient was admitted to the Infirmary May 23d, but had been seen four days previously at her home in the suburbs by the Aural Interne, Dr. E. A. Crockett, at my request. She had pain in the right ear, followed by slight discharge, eight weeks previously. The pain in the ear and the discharge soon ceased but the pain in the mastoid continued and four weeks later she began to have swelling in the neck and an increase of pain, but no chills. When seen she was in fairly good general condition, thin, active, and energetic, with a fair appetite and able to be about the house. She had a temperature of 100° and a pulse of 80. The right membrana tympani was clearly visible, and was somewhat opaque but not sufficiently so to prevent visible evidence of fluid in the middle ear; there was no swelling

[1] July 25. Discharged to out-patient department with the mastoid wound closed and only slight discharge from the ear. One week later the opening in the membrana tympani had closed.

in the canal. Paracentesis of the membrana tympani in the posterior inferior segment gave exit to a few drops of limpid serum.

The mastoid was tender at the tip only, and there was a hot, non-fluctuating swelling extending from the tip of the mastoid half way to the clavicle. A leech was applied over the mastoid, followed by cold applications, which relieved the pain, but the swelling continued to increase and the patient was admitted to the Infirmary on the date above mentioned for operation under ether, which was done on the following day. The history of the case and the deep seat of the swelling in the neck seemed to indicate spontaneous perforation of the mastoid at the inner side of the tip, or low down in the digastric fossa, with burrowing of pus below the fascia, and under these conditions an opening terminating far back, at its lower portion, would be advisable.

May 24. After the usual preliminaries, an incision was made from a point above the upper limit of the auricle, downward and backward over the line of the digastric fossa, and then curved slightly forward. At the lower part of the incision in the digastric fossa, and at the tip of the mastoid, bare bone was found and the drill was entered at this point and carried upward and forward, with the escape of but a small amount of pus, the major part of the secretion in the mastoid having evidently already drained itself down into the neck. The drill was followed by the use of the chisel and sharp spoon until a communication with the antrum had been established and the diseased bone at the tip and back of the mastoid had also been removed, which having been effected, attention was next turned to the condition of the neck.

Here an incision was first made along the anterior border of the sterno-cleido-mastoid at a point about equi-distant between the tip of the mastoid and the clavicle and a simi-

lar opening on the posterior border of the muscle and a little higher up; these openings gave exit to from five to six drachms of pus, and were then enlarged so that the finger and a spoon could be passed in all directions between the three openings and the pus cavity thoroughly scraped, undue interference downward being carefully avoided. Pus and the injected fluids passed freely through the openings in both directions. The sinus from the mastoid opening to both the lower incisions was well dilated, and flushed with a 1–5,000 corrosive solution, and medium size rubber drainage tubes were introduced. Dry dressing. Duration of operation one hour and a quarter.

May 26. Better, no pain, no stiffness in neck, normal temperature, free drainage.

May 30. Large tubes removed and replaced with smaller by inserting the ends of the smaller tubes in the upper ends of the larger, fastening them by a single catgut suture, and drawing them through.

June 5. Improving; catgut drains, previously soaked in tannin solution, inserted in place of the tubes, in the same manner.

June 12. Catgut drains came away, free drainage. Discharged under care of her family physician.

June 26. The patient was readmitted to the Infirmary with pus burrowing in the neck below the two lower openings. On account of the evident tendency of the pus to burrow downward, an operation for drainage at a lower level and for general improvement of the condition of the pus cavity was advised and done under ether on the day but one following.

June 28. Under the usual preliminary precautions, the upper and lower anterior drainage openings were enlarged and a new opening made midway between the two lower openings and an inch or more below both of them, adhesions were broken up, the cavity carefully explored and

the pyogenic membrane scraped away, so that a permanganate solution passed freely from all the openings under very slight pressure; the tissues below the lower opening were perfectly firm. No drainage tubes, dry dressings.

Following this second operation, the patient complained of shoulder tip pain but this was at no time severe and she steadily improved under simple permanganate solution syringing until —

July 4. There was considerable suppurative discharge for the first time since the operation, coming apparently from a sinus above and behind the posterior drainage opening. This was successfully controlled by pressure pads and the case progressed favorably.

Case XXII. — Woman, 19 years of age, single. In the following record of a secondary operation it should be mentioned that the original operation had been done a year before for extensive and rapidly progressing mastoid disease and that the patient had made a good recovery with the exception of a slight continuous purulent discharge from the posterior portion of the middle ear and, recently, indications of facial paralysis. A small sinus remained, and there was a tract of rough bone in region of the antrum to be felt with a probe in the middle ear. Entered the house for operation under ether, July 25th.

July 25. Following the usual incision and reopening of the mastoid, the road to the antrum was found to be blocked by cicatricial tissue, which was first cut with the small knife. Careful examination showed extensive bare and carious bone about the antrum. This was removed by the sharp spoon and by small middle ear curettes, as also some hard spiculæ of bone at the bottom of the mastoid, and drainage was established from the mastoid to the middle ear.

July 26. Patient rallied from ether slowly, was very

drowsy, had persistent vomiting, and no appetite. There was complete paralysis of the left side of the face and considerable vertigo.

July 27. The patient was still drowsy but the vomiting was checked; the dizziness, however, continued and the patient was unable to sit up.

July 28. General condition better; not drowsy; dizziness less; able to eat liquid food; eye could be closed better and mouth controlled so that liquids would not run out. Slight serous discharge from mastoid and meatus. Dressed twice daily and syringing fluid passed through freely after probing.

July 29. Facial symptoms better. Swelling of the posterior superior wall and a small polypus in the canal.[1]

The value of conclusive operative interference in the early stages of mastoid disease is as well illustrated in the following case as in those of speedily successful results which have preceded it in this report, and the recurrence of the mastoid symptoms, with the necessity for operation upon that cavity after an apparent recovery, not only points the moral which is the text for this communication but also that enunciated by Schwartze[2] in regard to distrusting a mastoid recovery so long as any suppurative process in the middle ear remains or is imminent.

Case XXIII.—Woman, 32 years of age, single. May 14, 1891. Following an acute inflammation of the right middle ear of five weeks' duration, with very profuse serous discharge, the patient had, when first seen, pain and swelling over the mastoid of three days' duration. Examination showed tenderness of the tragus and mastoid, the latter being especially sensitive over the region of the antrum and back-

[1] Subsequent history showed a gradual improvement in the facial symptoms and the swelling in the canal and the polypoid swelling also disappeared.

[2] Archiv für Ohrenheilkunde Bd. xvii. H. i. p. 116, 1881.

ward. The canal was filled with purulent discharge and there was great œdema of the posterior wall, to such an extent that the membrana tympani could not be seen. Ordered Leiter coil to mastoid region and syringing the ear every hour; two leeches were also applied to the mastoid and one to the tragus.

May 17. Still pain in the neck, tenderness of the mastoid, and profuse discharge from the ear. On account of continuance of the mastoid symptoms, operation under ether was advised. On examination, after thorough syringing, the œdema of the walls was found to be entirely gone and the membrana tympani could be clearly seen. A long incision was therefore made from the lower segment to a point above the short process and through the posterior fold, including a cut through œdematous mucous membrane which was nearly two millimeters thick. This was followed by free bleeding and serous discharge. Drainage wicks every hour.

May 23. The mastoid tenderness had gradually grown less and less since the operation, until there was but very little, and neither redness nor swelling, and the œdema of the canal had not returned. General condition was much improved.

June 3. Had been slowly convalescing since last note. Three days ago, for no ascertainable cause, temperature rose to 103°, with some nausea but no other indicative symptoms. Two days ago had more pain in the tip of the mastoid and in the right neck, which has continued since. Yesterday morning the temperature was normal. At 5 P. M. had a very severe chill, with pain in the left side and a cough which increased without expectoration. Temperature 104°, pulse 120. Respiration only slightly accelerated. Examination of the lungs and abdomen revealed nothing. One slight chill last night. This forenoon pain had gone and the cough was slight; temperature 102°.

June 5. Chill on the night of June 4th, with temperature of 104.4°, with vomiting. Some pain in the ear, much pain in the neck.

June 6. Last night had a very severe chill, temperature 104.6°. Some vomiting, but not so much as on the day before. The pain in the neck continued and there was a slight, deep-seated swelling. The external canal showed no œdema or other change and the mastoid was not tender, except at the tip. On account of the bad general condition and the mastoid tip tenderness, operation was advised and done under ether on the same day. Shaved, usual incision with but little bleeding. The drill entered the mastoid easily and one small pocket of pus was found. There was no caries of the tip and the cancellated structure there was in good condition. The opening in the cortex was enlarged with the gouge and this was followed by the use of the curette. Hot water irrigation. Dry dressings. The operation was hurried on account of the bad condition of the patient, whose pulse ranged from 140 to 180 and was irregular. Under ether about forty-five minutes. Rallied from ether slowly.

June 7. Very slight discharge from ear, none from mastoid. No pain in the neck. Complained in the morning of pain in the right eye, the first symptom of a suppurative irido-choroiditis which eventually destroyed the eye and prolonged the stay of the patient in the Infirmary long after the mastoid was healed.[1]

In contrast to these operative cases there are here appended short reports of the seven remaining mastoid cases in which operation was not necessary.

Case I.—The patient, a man 34 years of age, had

[1]Since this case has an important bearing as illustrating the path of septic infection from the mastoid, it will be reported in full with a history of the eye complication, later.

acute inflammation of the right middle ear, beginning about three weeks before the time of his first visit, May 5th, which was made on account of recurrence of pain in the ear, extending to the mastoid and occasionally towards the vertex. There was a muco-purulent discharge from the middle ear, coming through a nipple-shaped projection in the posterior superior portion of the membrana tympani; there was also slight mastoid tenderness and a temperature of 99.6°. The patient was ordered a cocaine ear-bath, bromide of potassium internally, and cold applications over the mastoid to be continued as required. Between the date of the first visit and June 16th, when the mastoid symptoms had entirely disappeared, there were occasional recurrences of pain, relievable by local applications.

Case II.—Man, 45 years of age, had an acute inflammation of the right middle ear one month before the date of his first visit, May 23d. The external auditory canal was clear, the membrana tympani opaque and slightly reddened posteriorly and superiorly, and there was some mastoid tenderness.

The patient was given bromide of potassium internally and was ordered to rest as much as possible and to make cold applications to the mastoid. Under this treatment he improved and the pain in and tenderness of the mastoid became less, recurring, however, at irregular intervals until the latter part of June, and at all times readily controlled by cold applications.

Case III.—Woman, 31 years of age, was first seen July 5th, with acute congestion of the upper portion of the right tympanic cavity, as indicated by redness and swelling of the posterior superior portion of the membrana tympani and the inner end of the canal. The pain, which was very severe, had begun forty-eight hours before the time of the

visit and now extended towards the mastoid antrum, toward the vertex, and forward into the temporal region. There was mastoid tenderness, especially over the point corresponding to the antrum and in the region of the digastric fossa; the temperature was 100.2°. A long curved incision was made in the posterior superior portion of the membrana tympani, following the posterior fold, with a resultant free bleeding and sero-sanguinolent discharge. With the use of dry drainage wicks in the canal and cold applications to the mastoid, together with bromides internally, the congestion gradually subsided and the patient made a good, though slow, recovery.

Case IV.—A woman, —years of age, was first seen April 5th, 1891, with a history of pain in the right ear of six weeks' duration, without aural treatment. Two weeks before the date of the visit a discharge from the ear had occurred but without abatement of the pain, which had finally extended into the mastoid. There was considerable œdema of the posterior wall of the external auditory canal, which was filled with a muco-purulent discharge; there was a well marked nipple on the membrana tympani and much tenderness and some redness of the mastoid.

The treatment consisted in the application of the cold Leiter's coil and in douching the ear with a warm corrosive solution every two hours.

April 7. No pain for the past twenty-four hours, œdema of the canal wall less, tenderness of the mastoid much less. Leiter coil discontinued.

April 15. Very slight discharge from the ear, no œdema of canal wall, and the nipple had nearly disappeared. There was no tenderness of the mastoid and the general condition was much improved.

July 2. The patient, who had not been seen in the interval, reported at the Infirmary with the symptoms of chronic periostitis of the mastoid.

Case V.—A woman, 40 years of age, was admitted to the Infirmary, April 6th, 1891, with a history of severe pain in and about the right ear, together with tinnitus and deafness of three weeks' duration.

Examination showed a profuse muco-purulent discharge coming through an opening in the anterior inferior quadrant of the membrana tympani, œdema of the posterior superior canal wall, tenderness of the tragus and mastoid region, and some redness of the latter. A leech was applied to the tragus and the cold Leiter coil to the mastoid.

April 7. Tenderness of the tragus entirely, and of the mastoid region quite, gone, with exception of a small spot near the canal.

April 10. The œdema of the canal wall had slightly increased and the use of the warm douche in the canal was ordered in addition to the Leiter coil.

April 13. Slept well all night without opiates, for the first time since the ear trouble began; the discharge from the ear had decreased and all tenderness had disappeared, and by May 1st the discharge had ceased also.

Case VI.—A woman, 30 years of age, was seen April 16, 1891, convalescent from influenza and with acute suppurative inflammation of both middle ears, which began five days previously and had now become complicated by acute mastoid trouble on both sides, with severe pain extending toward the vertex and down into the neck. There was œdema of both canals, tenderness of both mastoids, and a temperature of 102.5°.

The treatment consisted of rest in bed, the cold Leiter's coil to both mastoids, warm douching of both ears as often as once in three hours, and a leech to the left tragus.

April 17. Pain in the right mastoid nearly gone, temperature 100°.

April 18. Pain and tenderness in both mastoids nearly

gone, discharge from the ears and œdema of the canal walls very much less; temperature 99°.

The Leiter coil was omitted April 21st and five days later the patient was discharged from treatment.

Case VII.—The patient, a sailor, 32 years of age, had an acute inflammation of the left middle ear five months before the date of his visit, May 13, 1891, with discharge which had continued. For a period of four months he had, at irregular intervals, pain so severe as to keep him from sleeping. This pain had latterly increased and he was admitted to the Infirmary with the left mastoid evidently larger than the right, reddened and tender on pressure. The left external auditory canal was filled by a large fibrous polyp. This growth was removed to its base and syringing and alcohol instillations were ordered.

May 14. Mastoid region more tender, especially near the tip. The syringing and warm alcohol instillations were continued and in addition two leeches were applied to the mastoid and followed by the continuous cold Leiter coil.

May 15. No pain in the mastoid and no tenderness except at one point over the antrum.

May 23. Discharged from treatment with the left mastoid still larger than the right, but neither red nor tender.

NOTES ON OPERATIONS ON THE MASTOID PROCESS.[1]

By E. Gruening, M. D., *New York, N. Y.*

At the Aural Department of the Mt. Sinai Hospital, forty-seven operations of opening the mastoid process have been performed since January, 1889. This number exceeds that of any triennial period, the increase being due to the prevalence of influenza. The cases operated on may be classified as follows:

First. Acute caries or empyema of the mastoid with profuse purulent discharge through the middle ear — thirty-nine cases;

Second. Caries of mastoid with cortex intact, without purulent discharge through the middle ear — two cases;

Third. Chronic otitis media purulenta with presence of cholesteatomatous masses in the antrum and tympanic cavity — three cases;

Fourth. Chronic otitis media purulenta with sclerosis of the mastoid cells, thrombosis of lateral sinus, and pyæmia — two cases;

Fifth. Chronic otitis media purulenta with sclerosis of mastoid and abscess of brain — one case.

Of these forty-seven cases, all the acute cases — forty-one in number — recovered completely and were discharged cured; of the chronic cases, the three complicated with a formation of cholesteatomatous masses were improved, but not cured; while the remaining three ad-

[1] Read by abstract.

mitted to the hospital with thrombosis of the lateral sinus and abscess of the brain, respectively, died.

The method of operation which I had employed in the Mt. Sinai Hospital up to 1889 was strictly that of Schwartze. Küster and von Bergmann criticized Schwartze's method unfavorably because the cases required a lengthy after-treatment by frequent syringing. Küster proposed another mode of procedure, in which the opening of the mastoid is systematically combined with the removal of the posterior wall of the osseous portion of the external auditory canal, and the introduction of a drainage tube through the mastoid incision and the canal. The strictures made by these gentlemen are justifiable from a surgical but not from an otological standpoint. My operations demonstrate that, by an extension of Schwartze's method, the prolonged after-treatment becomes unnecessary and the function of the ear is respected. This was particularly noticeable in the forty-one acute cases mentioned in this series.

The modification of Schwartze's method as practiced by me during the past three years consists in the systematic removal of the whole external wall of the mastoid process. I begin my operation through the soft parts with an incision extending from a point situated two centimeters above the linea temporalis and carry it to a point below the apex of the mastoid. The periosteum is then lifted from the whole extent of the mastoid process, and the tendinous attachments of the sterno-cleido-mastoid muscle are divided. The outer surface of the bone is thus completely exposed, and, if found diseased, opened with a sharp spoon at the point affected. If the bone is found firm and apparently healthy, the opening is then made with chisel and mallet on a level with the spina supra meatum. Thus far I follow Schwartze's directions. The next step in my operation is the removal of the whole cortex by means of the bone forceps, or rongeur. I use for this purpose an instru-

ment especially constructed with a view to the dimensions of the field of operation. Removal of the cortex brings into view a number of cavities filled with granulation tissue, for the dislodgment of which a sharp spoon is used. These small cavities are thus generally converted into one large cavity whose bony walls may be found softened in many spots. Again the sharp spoon is used to clear away the softened and diseased bone. Now the large cavity thus made can be fully explored and the site of the lateral sinus in its relation to the antrum determined. The importance of this localization was shown in one of my cases where the sinus covered the path to the antrum into which I intended to penetrate. In some cases the sinus was found behind this path; in others, below that level. It is evident, then, from my experience in this series of operations, that localization of the sinus is generally possible, and thereby the subsequent step of entering the antrum rendered absolutely safe. After the operation the cavity is packed with iodoform gauze and a bandage applied.

Of the forty-one acute cases, forty remained aseptic during the entire process of healing, which on an average lasted four weeks. Throughout that time neither the wound nor the ear was syringed. The packing was removed every fourth day and replaced by fresh gauze. The profuse discharge from the middle ear ceased immediately after the operation in every case. It is obvious, then, that in these cases we have not to deal with a disease of the osseous walls nor ossicles of the middle ear, but with an affection of the mastoid process. The pus formed in the mastoid is discharged through the middle ear. Furthermore, I have learned from these operations that the large incision over the mastoid may be immediately closed after the operation in many cases. This I intend to do in the future.

The fact that very extensive disease may exist in the

interior of the mastoid process without the presence of any of the outward signs demanded by our text-books, is shown by the two cases of central caries without apparent disease of the middle ear. Tenderness of the mastoid was the only symptom present at the time of operation. In fact, this local tenderness is the only symptom that is common to all cases of mastoid disease. Redness and swelling of the soft parts, local pain, headache, and high temperature may or may not be present. Tenderness, however, is a constant factor in this variety of possibilities, and if, in spite of the employment of the ordinary means to combat it, this symptom persists, there is an indication for operative interference.

INFLUENZA-OTITIS IN 1891.[1]

By Dr. B. Lœwenberg, *Paris, France.*

The influenza epidemic of 1889–1890, which has spread over nearly the whole extent of our planet, has struck the profession, not only by the immense number of persons affected, but also by the special character it has communicated to many other diseases, for instance, to otitis media purulenta. As early as in my first paper on this subject, a short note published on the 8th of January, 1890, and inaugurating a long series of publications on the matter, due to authors from all countries, I have insisted upon the enormous percentage of cases of middle ear inflammation observed during the great epidemic of influenza, as well as in the peculiarities this ear affection has shown under the then reigning genius epidemicus. Later on, I have completed my communication by another paper on the same point, read before the Society of Public Medicine and Professional Hygiene (Paris, 22d January, 1890).

It results from these publications, and from the extremely numerous other communications on the subject, that otitis media has presented a different character in France from what it has in the east and the north of Europe. In these latter parts, otitis media *hæmorrhagica* and myringitis *hæmorrhagica*, hitherto nearly unknown forms of disease, had prevailed, whilst they were rare in France. Hæmorrhagic character being an aggravating circum-

[1] Read by title.

stance in these diseases, influenza-otitis has presented out of France an extraordinary number of severe cases and trepanation of the mastoid has been frequently resorted to. I have not been compelled to practice this operation during the epidemic, first of all, because only two among the great number of cases I have seen have been complicated with mastoiditis, and, last, not least, because, as I have declared in a former paper read before the International Otological Congress in Basle, 1884, I use patiently to try comparatively gentle means; for instance, large incisions in drum-head, frequent air-douche, and the abundant resources of antisepsis, before coming to trepanation. I feel obliged to declare, notwithstanding opposition from many aurists, that I firmly remain on my standpoint with regard to the necessity or unnecessariness of trephining the mastoid in most of the cases. Great perseverance often succeeded, in my practice, in curing, in a really surprising manner, cases seeming most alarming; for instance, such ones where, besides a strong and lasting fever, there existed brain complications (as persistent vomiting, with intense and continuous headache), abscesses on points distant from the mastoid, for instance, as far as on the inferior insertion of the sterno-cleido-mastoidian muscle, the opening of which gatherings, by the by, on account of the vicinity of the great blood vessels, necessitated special precaution.

With regard to the *aural complications of the influenza epidemic of 1891*, they have been much rarer here than a year ago. This fact results from my personal experience as well as from the practice of other specialists and practitioners. The difference is an absolute one and a relative one. As to the absolute difference, we must take into account that influenza this time has spread much less widely than a year ago. The relative diminution is certainly due to the fact that, whilst last year's epidemic had caused an immense number of complications in the first

aerial and digestive passages, which easily spread to the middle ear, influenza this year has affected these regions much less frequently than in 1889 and 1890.

Nevertheless, these aural complications, though comparatively rare, have enabled me to state *two remarkable facts* concerning certain anomalies in the course of these otitis. We shall consider them separately.

I. Acute otitis media terminated by sudden cure.

We have here several cases of the kind, which have shown a rather surprising course, absolutely the same in each of them. The patients were mostly children, and the disease set in almost suddenly, with acute pain in one, seldom in both ears, deafness, fullness, and a sensation of heat in the affected organ. Fever existed from the very beginning. Several grown-up patients complained of tinnitus, whilst children, as usual, did not mention this symptom.

Examination showed in all these cases the same aspect: The drumhead was of a uniform dark red hue and bulged outside in its postero-superior part. There was no demarcation line showing the existence of sero-mucous fluid in the drum. Tuning-fork, hearing for words, watch, etc., revealed nothing different from the usual signs of acute otitis media.

Well, upon one inflation of air, Politzerizing in children, catheterism in adults, all these symptoms vanished as if it were by enchantment, pain, deafness, and tinnitus immediately ceased, and the very fever disappeared rápidly.

Several cases were thus definitively cured by one air-douche; in a small number only, this had to be repeated one or more days following, as the morbid symptoms, though considerably reduced, had a tendency of reappearing.

The observation of a series of such cases in a comparatively short space of time struck me and I recollected I had observed quite a similar one last year during the first epidemic of influenza. The patient, a strong boy of about fifteen, was suddenly seized with acute pain, now in one ear, then in the other. Each time the affected organ showed the above-mentioned aspect and symptoms. Politzerizing effected an immediate cure, but relapses were so frequent that I finally felt obliged to trust the boy's father with the air bag and thus enable him to cut short each attack, and, lastly, to operate a definite cure.

It is to be noted that this boy had adenoid growths of a medium size. As they did not hinder nasal respiration, nor had, up to that date, caused any aural trouble, their removal had been declined. One of the above-mentioned children had the same disease, but had already undergone an incomplete operation several months previously. In one of my previous publications on influenza-otitis, I have mentioned the fact that, amongst nearly a hundred cases of influenza-otitis which I had observed in the preceding epidemic, only two had presented a severe nature and a protracted course, and these were precisely cases with adenoid growths. Surely this fact is more than a simple coincidence, and enhances, in my opinion, the necessity of operating upon these growths, even in cases where they give rise to no special trouble.

With regard to the *nature* of these cases of influenza-otitis setting in in such an alarming way, and, nevertheless, so quickly and so easily cured, I think *we must consider them all as beginning otitis media acuta.* Influenza first had caused inflammation of pharynx or nasal fossæ and then invaded the Eustachian tube and the drum. In this cavity, consequently, a small quantity of liquid was secreted and began to bulge the tympanum, causing intense pain by its tension. Air-douche cured by a multi-

farious action: it opened the tuba Eustachii, swept away the liquid, and rendered to the drum the necessary quantity of normal air instead of the rarefied and disoxygenized one it had enclosed before. At the same time, it gave the drumhead its normal tension and effected on the mucous lining of the middle ear a pressure capable of diminishing, at least temporarily, its infiltration and vascular injection. It, finally, swept away the liquid accumulated in drum and Eustachian tube, and, at the same time, perhaps, dangerous bacteria it contained, and which would have been capable of setting up suppuration in the place of simple secretion.

With regard to the final fate of this liquid, it may be driven back into the pharynx by the reflux of the inflated air, or, the Eustachian tube now being opened, gently flow back into this cavity, or pass into the lymphatics of the drum, which, according to Kessel, open into it.

The whole of the symptoms in the above-mentioned cases is very much like certain cases of acute otitis media, so frequently met with in spring, especially in children. Nevertheless, they are remarkable on account of their numerous apparition in the midst of an epidemic of influenza and in winter (February), as well as by their alarming appearance, and, last, not least, by their instantaneous cure by a single air-douche. We sometimes note, it is true, after inflation, a real recurrence in children with regard to the local state and to the general health, but the effect is mostly only temporary and the operation has to be repeated during a certain time.

These observations, moreover, peremptorily prove the sovereign efficiency of air-douche in acute otitis media, and I beg to insist upon this fact, on account of several specialists, in Germany especially, having a tendency of repudiating its use in the treatment of this disease. The above-mentioned results, on one hand, and the facility of

Politzerizing, on the other, which render it accessible even to the public, induce me energetically to protest against the tendency of depriving us of so valuable a remedy in so dangerous a disease. In my opinion, on the contrary, by impressing on the profession the necessity of employing air-douche on the very outset of otitis media, we would lead to a rapid cure in an immense number of beginning cases, due to influenza or not!

Moreover, I firmly believe that the opposition of the above-mentioned specialists arises more from theoretic reasoning than from real observation. (By the by, I consider in the same way the rejection of boracic acid treatment in otorrhœa, the which I esteem one of the most valuable methods, having never met with the slightest inconvenience in its use when scientifically applied and watched—and even when not.)

II. Suppurating otitis media with peculiar form of tympanic perforation and course.

Besides the cases which have been described in the preceding chapter, I have observed, in the epidemic of 1891, two others which strikingly contrast with those. They were two cases of otitis media, in which suppuration rapidly set in, soon assuming a chronic course contrary to what generally happens, when the disease is conveniently attended to, as had been the case here, and when no general affection aggravates its character.

Moreover, a special and hitherto not noticed form of perforation came to observation in both cases.

I shall first describe the course of the disease in these two cases, and afterward examine their nature and character.

1. Mrs. X., actually 47 years old, delicate looking but usually healthy, and with no particular precedents in her family, had been sent to me by my lamented friend, Dr. Johnston (of Paris) in 1874.

When four years old, she had earache, "but had been completely cured." When she first came to consult me (1874), she had been deaf in the right ear for some time. Examination showed a simple catarrh of middle ear, which was rapidly cured. Six years afterwards, she had deafness on both sides, caused by plugs of cerumen, after removal of which hearing was normal R and L.

The 11th of February, 1891, I was called to see Mrs. X., whom I found very ill. She had had influenza and suffered dreadfully in the right ear (the one which had been affected when she was four years old). I found the following state:

My watch, which a normal ear hears at five meters in a silent room, is not heard at all, even when pressed upon the right ear (left one normal). Drumhead of a dark red hue. Postero-superior segment bulged outward. On the antero-inferior part there exists an elliptic layer, the longer axis of which is directed perpendicularly. It is of a brilliant red hue and seems to consist of liquid blood. Politzerizing slightly improves the hearing: watch perceived at one inch. Instillation of luke-warm glycerine during the day and of cocaine at night; saline purgative and Politzerizing practiced to perfection by Mrs. X.'s husband.

The next day Mr. X. tells me that a bloody discharge comes from the meatus. Watch 0. The red spot is changed into a coagulum of blood preserving the former oval shape. No perforation yet. Air passes badly, even by the catheter, which, nevertheless, slightly improves the hearing. Syringing removes the clot. On its former place there exists a flat, bloody erosion of oval shape. Less pain, no *fever*, *which has never existed during the whole disease* (temperature never exceeded 36.1° Celsius=96° Fahrenheit).

The 13th of February the drum is found spontaneously

perforated. The opening does not occupy the place of the coagulum, but is situated farther behind. It extends to the handle of the malleus, the posterior rim of which it goes along. Watch 0, no improvement of hearing after inflation of air. General health still precarious. Permanent pain. 120 pulsations. Bad nights. The mastoid region begins to swell and to pain spontaneously and on pressure. Instillation of 90% alcohol, containing 20% of finely powdered boracic acid (the super-saturated solution I proposed ten years ago).

To be short, the further course of the disease was as follows: At first the pain lasted night and day, without an interruption, during a fortnight, afterwards with interruptions during the same length of time. It finally diminished gradually. The bloody discharge persisted during a month and then stopped under Politzerizing and inflation of boracic acid. The microscope showed the discharged matter to consist nearly exclusively of unaltered red corpuscles with very few white ones. Mastoid healed without operation.

Notwithstanding the hearing was slowly gaining, the perforation increased in size and took quite a peculiar form, which I should call pyriform. It was large and round beneath and terminated above in a long and narrow linear point running (Fig. 1) *along the posterior rim of the handle.*

FIG. 1.
a. Handle of malleus.
b. Pyriform perforation of drum-head.

The place where the oval layer had existed has become quite normal.

18 March, 1891. No change. Watch heard at two inches (five centimeters). Perforation the same; rest of drum seems normal. All kinds of treatment: alcohol containing various antiseptics, etc., have been employed without any success.

The 4th of July I learned that the discharge, as above

mentioned, has suddenly ceased, no more to return. Watch six inches (fifteen centimeters).

I saw the patient the last time the 24th of July, and found that the longish upper part of the perforation ("the stalk of the pear") (Fig. 1 b) was entirely cicatrized, and the round inferior part even, seemed slightly diminished in extent.

2. A boy of 11 years is brought to my office for the first time, the 28th of June, 1889, for bilateral deafness. At first sight, it strikes me that both his corneæ are dim. This phenomenon being somewhat characteristic of *hereditary syphilis*, I questioned the boy's mother, a widow since long time, and learned that the child's father had, in fact, been syphilitic. She herself seems uncontaminated, but looks very delicate and is subject to frequent hemicrania.

The boy's teeth show one of Hutchinson's shapes. The superior central incisors are conical and have semi-lunar notches.

Before having examined the ears, I therefore was convinced that we had to deal with Hutchinson's "triad": interstitial keratitis, teeth affection, and deafness, arising from internal and middle ear affection. But inspection at once disabused me: there was on both sides common suppurating otitis media, with a round perforation of the size of a lentil on each drumhead.

The history of the case was, in short, as follows: When three days old, he had enteritis and remained between life and death during a whole year. He never had specific coryza, eruptions, or ulcerations. Double keratitis set in in 1881. In 1888 the eyes improved and ear troubles began. The youth is rather thin. His skin is of a dull gray hue, which contrasts with the ruddy complexion of his mother. His forehead is arched (and bumped), with a deep perpendicular depression in the middle. The skull is symmetrical. Nose flat but not sunken in.

The treatment of the aural affection consisted in syringing, Politzerizing, and inflation of boracic acid or instillation of the above-mentioned super-saturated alcoholic solution. It quickly led to a complete cure, but from time to time, and without any appreciable cause, relapses appeared in one or the other ear. The drums then were again perforated, always at the same spots, discharge reappeared, and finally the same treatment led to cure.

With regard to the nature of these otitis, we must consider them as having no specific character and being simple middle ear suppurations *in syphilitico*. In fact, we know that deafness arising from hereditary syphilis does not offer the symptoms here mentioned, but distinguishes itself by a slow and insidious course, without genuine inflammation or suppuration. (I here omit, as having nothing to do with the present case, the serious cases of deafness due to *acquired* syphilis, which generally sets in with surprising suddenness.)

In February last the boy is again seized with otorrhœa in the left ear. The drum shows a round perforation at the usual place. The ordinary treatment is resumed and, shortly after, the opening begins to shrink, discharge diminishes, and everything forebodes the usual rapid cure, when the boy, in March, catches influenza. I saw him a fortnight after the onset of this new disease and noticed a considerable change for the worse in his ear. Perforation had become larger and was now *pear-shaped*, the same as in the preceding case. It is round beneath and ends upward in a kind of stalk, a long and narrow slit running along the posterior rim of the handle of the malleus (Fig. 2).

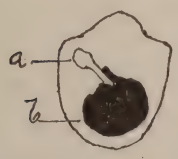

FIG. 2.
a. Handle of malleus.
b. Pyriform perforation of drumhead.

Since then, treatment has not been able to effect a perfect cure. I saw the boy again the 2d of July, and found that, whilst the discharge had really been stopped,

the perforation was very much the same. Nevertheless, hearing for the voice was surprisingly good, a fact I have often noticed in children, notwithstanding the presence of a large perforation. We know that such is not the case with grown up people. I incline to think that the difference is due to a greater power of the (very little known) *accommodation* of the ear, the same as the accommodation of the eye is greatest in childhood and diminishes as life advances.

The patient left Paris shortly after his last visit, for a foreign watering-place. On the 16th of July I received from a physician friend of mine residing at that place, a letter in which he informed me that the mastoid process of the boy's sick ear had suddenly become tender and swollen. Temperature was 40.3° C. (101.2° Fahrenheit). These symptoms persisted for two days, then there was a local improvement, but the fever lasted. Afterwards, apparent cure during two days, but on the third, temperature was again 39.3° (104.8°); inferior part of mastoid tender and swollen.

Conformingly to the above-mentioned manner in which I use to treat these cases, I quieted my friend, who already talked of trephining, and advised boracic alcohol, Politzer's douche, syringing, etc. In fact, the 29th of July, Dr. M. writes: Young X. is all right, air passes well during inflation. The ear discharges freely. Pain and fever are gone. Excellent general health and appetite.

REMARKS.

To the experienced aurist the two preceding cases offer an unusual course and character. Simple acute otitis media, after natural or artificial perforation of drum, nearly always heals in a short time under convenient antiseptics and frequent air-douche. If it should be necessary to furnish fresh evidence for this assertion, it would precisely result

from the description of a great number of similar cases radically cured by me during the influenza epidemic of 1889–1890, the same as from the cure of all previous attacks in Case No. II. itself. This rule admits an exception only when patients suffer from a serious general disease or diathesis (tuberculosis, diabetes, etc.), or when local complications aggravate the situation, voluminous adenoid growths, for instance, are present.

Nothing of the kind exists in these two cases, if not syphilitic antecedents in No. II. But even there this grievous circumstance had not prevented all the previous attacks of otitis from healing in the ordinary space of time in which relapses of purulent middle ear inflammation use to heal under ordinary conditions.

In the two cases, it is true, otitis purulenta had befallen ears which had been affected previously, but as I have exposed in a former paper, this certainly aggravating circumstance has not prevented in 1889–1890 from completely healing all my cases of influenza-otitis, concerning ears that had been affected before, and even without trephining, those attacked with mastoiditis during that epoch!

The Case No. I. (Mrs. X.) shows a peculiar phenomenon, — the lasting bloody discharge. Now, if this peculiarity, according to many special papers, has been extremely frequent in northern and eastern Europe during the epidemic of 1889–1890, it has been such an exception in Paris that I have noticed it only once among one hundred cases, and Mrs. X. was the only patient in whom I observed it in 1891. In fact, influenza-otitis seems, accordingly to this circumstance, to have had a much severer character in the above-mentioned regions than with us. Thus the protracted course of the disease and the insufficient success of treatment in Case No. I. may be due to its hæmorrhagic form, but even this complication is failing in the second case; on the other hand, no new sign of

hereditary syphilis having been noticed in the boy for long years, it seems impossible to explain the bad success of treatment by ascribing it to this diathesis. Therefore, the influenza complication seems the only cause to be invoked in order to account for this anomalous course.

The most striking feature in both cases is the *peculiar shape of the perforation*. The opening was identical in the two ears with regard to its seat, form, size, and course. I do not recollect to have seen anything like it before, and all the researches I have been able to make in the special literature have given no better result. In all the various text books, pamphlets, etc., I have looked over, every design of a perforation showed roundish outlines, that is, circular, oval, or kidney-shaped ones, except traumatic perforations, which often are angular or pointed, but even among these, nothing approaches the here-mentioned *pear shape*. Exceptions were only found in Gruber's second edition of his Lehrbuch der Ohrenheilkunde. He there represents a nearly similar form, equally behind the handle (Tab. I., 13), and a somewhat longish and pointed cicatrix at the same place (Tab. II., 21 and 22).

How are we to account for the origin of this peculiar form of perforation? I propose the following explanation: When a perforation of drumhead is forming, the two layers of this cuticle are, as a rule, destroyed parallelly, that is, over the same extent of surface of the membrane. Now in our case the upper part of the perforation extends along the posterior rim of the handle where precisely the circular fibres fail more or less completely and only the radial ones exist. Reflection on the cause why perforations of tympanums always have roundish contours — a point which has not yet been investigated, as far as I know — leads me to the conclusion that this shape is due to the following circumstance: The two layers being destroyed parallelly, the slight degree of elasticity which

is proper to the annular fibres and which the radial ones do not possess, effectuates that the two separated ends of the former shrink to a certain extent, thus changing a slit or an irregular hole into a round one.

On the contrary, it is easy to understand that a different shape must result when perforation happens in the neighborhood of the handle where no annular fibres exist and the radial ones alone are present. Therefore, retraction, which in my opinion renders the opening round on other places of the drumhead, is not possible here and the perforations forcibly remain longish.

In the two cases, it seemed to me, besides, that the posterior rim of the handle was as if denudated by the ulcerating process.

With regard to this peculiar form of perforation, it is to be wished, my cases being only two, that other specialists would declare if they have observed similar ones.

PARIS, 15, Rue Auber.

THREE CASES OF ACUTE SUPPURATIVE OTITIS WITH COMPLICATIONS AND ONE DEATH.[1]

By Dr. F. M. Wilson, *Bridgeport, Conn.*

Case I.—I. H., aged 50. Jan. 2, 1887. Never had ear trouble before. Four weeks ago, while recovering from a cold, commenced to have pain in the right ear. The pain was not severe but continuous, and kept him awake part of every night for a week or more. Pain in the ears then ceased and has not returned. R. e. w. $=\frac{P}{40}$, L. e. w. $=\frac{40}{40}$. B. C. best in right. A. C. in left. No improvement in right after inflation. He now complains of obscure feelings of discomfort, referred to right side of head. Membrana tympani red and slightly bulging at upper part. He is already using the hot water bag and gets relief from the discomfort in his head while using it.

Jan. 5, 1887. Paracentesis right membrana tympani; no pus.

Jan. 9, 1887. Entire relief from head symptoms. R. e. w. $=\frac{P}{40}$.

Jan 23, 1887. A relapse. He has now shooting pains along the branches of facial nerve and what he describes as a "deep dull pain" in whole of right side of head. No redness or tenderness over the mastoid. No pain in the ear. Slight redness membrana tympani.

Jan. 26, 1887. Anodyne drops. Anodynes subcutaneously. Leeches and hot applications, without complete

[1] Read by title.

relief. Another paracentesis right membrana tympani. No pus.

Jan. 30, 1887. The second paracentesis gave no relief. Continuous heat gives more comfort than anything else, and he prefers hot sand bags. The temperature has been taken at irregular intervals; 99.5° F. was the highest record.

March 18, 1887. On Feb. 5th, without consultation with me except to tell me that he was going, he went to Southern Florida with the idea that the hot climate would relieve him. He tells me that he spent most of his time on the shores of Biscayne Bay. There the temperature averaged 80° F. by day and 70° F. at night. After the first week he had no pain and led an active outdoor life during the rest of his stay; was, in fact, in the water most of the time after sea weeds, being an enthusiastic botanist. But that four days ago, just before reaching New York on the return voyage, he was again attacked with pain. Now he has pain, redness, swelling, and tenderness over and back of the right mastoid, the most tender spot being one inch posterior to tip of mastoid. Prescribed close confinement in a uniform temperature of 80° F., poultices to mastoid and an anodyne for temporary relief.

April 1, 1887. Relief from all pain in twenty-four hours.

The history from March 18 was that of external mastoid periostitis with suppuration. About a drachm of pus was evacuated through a small incision. The pus seemed to be behind the mastoid.

April 15, 1887. Discharged well.

Case II.—S. F. R., aged 45. Feb. 3, 1890. Six weeks ago attacked with the so-called "grip" and during convalescence about three weeks ago left ear began to ache.

Never had ear trouble before. Has now a small perforation behind and a little below the end of malleus, with profuse discharge and severe paroxysmal pain, following branches of facial nerve. Has been taking morphine and is nervous and hypochondriacal; no pain in the ear or back of it. Temperature normal, pain worse at night. Local treatment, dry cleaning. Peroxide of hydrogen and inflation. For facial pain, hot applications and antipyrin.

Feb. 22, 1890. Have seen the case daily. The amount of pus from the middle ear is less, removed one small granulation from edge of perforation. Have twice given him a single injection of morphine for pain at night. For a week he got almost complete relief from a mixture of antifebrin and caffeine. The temperature continues normal. Up to date he has come to the office for all treatment. To-day I ordered close confinement in a uniform temperature, 75° F.

March 15, 1890. Discharge from tympanum continues, as does the shooting pain along facial nerve. Temperature normal. On March 26, 1890, patient went to Florida, where he died, April 16, 1890, and Dr. R. H. Gillen, of Deland, Fla., has kindly furnished the following notes:

"Five days before death he had a violent rigor, followed the next day by another, and temperature, which had been subnormal, rose to 104° F. and continued high, with slight delirium and occasional vomiting; lost the power to express ideas in proper words to some extent; answered questions unwillingly and very slowly. No paralysis, except ptosis on day of death. Passed into a stupor, which on day of death deepened into coma. No autopsy. Cause of death, cerebral abscess."

Case III.—A. B. C., age 44. Jan. 8, 1890. Never had ear trouble before. Is just recovering from an attack of the so-called "grip," of several weeks' duration. Com-

plains of slight pain and sense of fullness in right ear. Membrana tympani normal. R. e. w. $=\frac{40}{40}$. To stay in the house, wear cotton pad over the ear, and steam it if the pain continues.

Jan. 11, 1890. On morning of the 9th he left off the cotton pad and returned to business. To-day he has slight pain and fullness in right ear again. Same treatment.

Jan. 15, 1890. The treatment on 11th relieved his pain; on 12th had no pain, and on 13th he returned to business again. To-day pain has returned and for the first time membrana tympani is slightly red.

Jan. 20, 1890. During past five days he has had more pain, usually relieved by heat, but twice, at night, during that time has had morphine subcutaneously. To-day, without perceptible increase in redness of membrana tympani, pus appeared, coming through perforation in membrana flaccida.

March 1, 1890. The history from Jan. 20 has been one of persistent discharge. The treatment has been mainly cleanliness and disinfection. Twice during that time I enlarged the perforation downward. For past week has had slight redness, pain, and tenderness over mastoid, relieved by leeches and poultices. From March 3d to March 22d he was under the care of Dr. H. D. Noyes, but was irregular in his attendance. (Under the title "Aural History of a Syphilitic Family," I reported the specific history of this man in Knapp's Archives, Vol. XIV., p. 27.) Dr. Noyes tells me that in addition to the local treatment he gave him large doses Hg. and KI.

March 26, 1890. Patient went to Florida. Some pain and tenderness over mastoid.

March 31, 1890. He went still farther south, to Havana, Cuba.

April 14, 1890. He returned north. While away the right canal was packed with boric acid powder for a few

days. The pain and tenderness over mastoid increased and on one day temperature rose to 100.8°. These symptoms subsided on leaving off the powder, and by April 5 all pain and tenderness ceased, and during the last week of his stay in Havana, the discharge from the tympanum was very slight.

April 30, 1890. Since his return home I have seen him every day. The amount of pus from tympanum has gradually increased, but he has no pain and attends to business as usual.

May 8, 1890. Dr. Roosa saw him in consultation. The floor of the external auditory canal has been red and swollen, especially near its inner end, for several weeks. Dr. Roosa advised incision through this swollen tissue down to the bone.

May 9, 1890. With a large Græfe's knife, I made a cut three-fourths of an inch in length, and down to the bone in centre of cut. No pus.

May 13, 1890. No pus from tympanic cavity since yesterday.

May 14, 1890. A scab has formed over perforation in membrana tympani. No pain, temperature normal, cut in external canal healing kindly.

May 20, 1890. Pain, redness, and swelling over mastoid. Temperature 100° F.

May 23, 1890. Temperature 101° F. After consultation with Dr. Bacon, of New Haven, incision over mastoid. No pus.

May 24, 1890. Pus appeared in the wound and by pressure got out about a drachm.

June 8, 1890. Discharged. Mastoid wound closed. No perforation membrana tympani. R. e. w. $=\frac{20}{40}$.

These three cases have several points in common. Their ages were 50, 45, and 44. They were all men and exceptionally robust. None of them had had ear trouble before. Each of them went to Florida for relief.

There is no doubt in my mind of the good influence of a warm climate on two of the cases, followed by prompt relapse on their return home before warm weather.

It is equally plain now that it would have heen better to have allowed the second case to die at home. Case I. seems to me a very suggestive one. A subacute inflammation of the tympanic cavity brought on by cold, an extension of this subacute inflammation to the surrounding periosteum. Hot applications the most successful means of relief. Immediate cessation of symptoms on arrival in Southern Florida. Complete relief for five weeks, prompt relapse on the first exposure to cold again, on the voyage home. A second relief from pain on close confinement in a warm room, with finally the usual suppuration, incision, and recovery. The symptoms of Cases II. and III., before the journey to Florida, were similar to those of Case I., except in one important detail, viz., discharge of pus from tympanic cavity, there being none in Case I., moderate in Case II., and profuse in Case III.

One point in the history of Case III. was of interest to me. From Jan. 8th to May 9th (four months) there had been constant discharge from the tympanic cavity, and during all that time, except the two weeks in Cuba, the discharge had been profuse, and this in spite of the most assiduous attention.

In three days after the incision in the floor of the external auditory canal, this discharge entirely stopped.

Incision through the floor of the external canal, to stop suppuration in the tympanic cavity, is new to me. At the time he advised the incision in this case Dr. Roosa spoke of another case of obstinate middle ear suppuration, in which such an incision had been of great benefit.

I do not wish to be understood as advocating warm climate for any considerable number of cases of suppurative otitis, but this experience has fallen in my way and it seemed to me worth reporting.

ACUTE SUPPURATION OF THE MIDDLE EAR —MENINGITIS—DEATH—AUTOPSY—NO INVOLVEMENT OF THE TEMPORAL BONE.[1]

By Dr. J. Morrison Ray, *Louisville, Ky.*

The opinion has been frequently expressed that meningitis, of a mild and distinctly circumscribed type, due to direct extension, accompanies all cases of acute inflammation of the tympanic cavity. It is common to see violent muco-periosteal inflammation of the middle ear, accompanied by strong evidences of brain complication, and yet no lesion develop; on the other hand, serious meningeal inflammation may show itself in cases where the ear symptoms have not been alarming. A case recently under my care, of meningitis of a fatal nature, rapidly developing upon what seemed to be a mild form of acute suppuration of the tympanum, is offered as evidence in favor of the last statement.

Hattie G., aged 47, was admitted to Louisville City Hospital, Feb. 27, 1891. She had been a patient on a former occasion, suffering from chronic rheumatism, and giving a history of syphilis. She now complained of pain in the right side of the head, the ear, and the shoulder, and had old anchylosis of the knee joint. When admitted she had a temperature of 98.6°, respiration 20, and pulse 96. She was given the formulæ used extensively in the institution for chronic rheumatism, composed of potassium iodide and salicylate of soda. Bromidia was given to induce rest.

[1]Read by title.

March 2d, I was asked by Dr. Neal, the Interne in charge of the ward, to examine her right ear, as she complained of great pain. I found a reddened drumhead and all the evidence of acute middle ear inflammation. Hot water and leeches were ordered.

March 5th, at my next visit, the membrana tympani had ruptured and pus was flowing freely from the middle ear cavity. The pain was still severe in the right side of the head. Temperature 99°. Pulse 100. Inflated the ear and forced out a quantity of pus. The ear was ordered to be syringed out with a hot carbolic solution, 1 to 40.

March 7th, the suppuration was going on freely. Pain still persisted in the head, and I ordered five grains of calomel and morphine at night.

March 9th. Pain in head persists. Temperature 100°. Pulse 98. Delirium at times. No swelling of the canal or tenderness over the mastoid. Pus flowing freely from the perforation in the membrana tympani. Ophthalmoscope showed no optic neuritis, but meningitis evident.

March 10th. Temperature 104°. Pulse 108. Pain in the ear not so great, but continuous in the head. Delirium at times.

March 11th, 8 A. M. Temperature 103°. 4 P. M. Temperature 104°. Antifebrin in five grain doses added to the treatment.

March 12th. Temperature 102.6°, delirium constant. About noon the nurse discovered the patient in a comatose condition and I saw her soon afterwards. Temperature 97°. Pulse 108. There was muttering delirium, ptosis, divergent squint, dilated pupil, and profound coma. The external canal still full of pus, no swelling or œdema about the ear, no optic neuritis. Dr. Enright was called in consultation, and it was decided that it was a case of "diffuse purulent meningitis." The patient died eight hours later in coma.

Autopsy by Dr. Marvin. Only the brain was examined. As soon as the calvarium was removed a purulent meningitis, confined to the frontal lobes, was exposed. The pia was opaque and the sulci filled with a greenish pus, which accumulated about the base. The brain contained no abscess. The temporal bone was examined carefully, and only a small spot of discoloration, immediately over the tympanic cavity, was discovered. No evidence of necrosis or communication with the cranial cavity was present. The meningitis was most apparent over the convexity of the anterior lobes, while over the region of the tympanic cavity no pus was present, yet the dura mater was thickened and the blood vessels were distended. The roof of the tympanum, which proved not to be exceptionally thin, was removed and the cavity found to contain blood-stained pus. The autopsy, therefore, showed the case to be one of purulent meningitis, following rapidly upon acute suppuration of the middle ear, and produced not by rupture of the tympanic roof, but either by transmission through the small blood vessels that perforate the bone at this point or by septic infection through the general circulation. Since the meninges overlying the tympanic cavity were not the focus of the purulent process, it seems most reasonable to suppose that the pyogenic microbe was carried by way of the general circulation, rather than through small perforations in the tympanic roof.

A CASE OF SUPPURATION, EXOSTOSIS, AND OTITIC EPILEPSY; MASTOID TREPHINING FOLLOWED BY FATAL SEPTIC MENINGITIS:

WITH CONSIDERATION OF SOME SPECIMENS ILLUSTRATING THE VARIED AVENUES OF COMMUNICATION OF OTITIC INFLAMMATION TO INTRA-CRANIAL STRUCTURES.[1]

By B. Alex. Randall, M. D., *Philadelphia, Pa.*

In February of this year I saw, in consultation with Dr. James Hendrie Lloyd, a young man of 30, who gave a history of nearly incessant otorrhœa on the left, since scarlatina in childhood. The discharge was generally scanty and at times did not flow out, and syringing was generally able to keep the ear free from odor. The hearing had long been practically lost; but with full use of the other ear was little missed. There had recently occurred, with increasing frequency, attacks in which he had fallen unconscious; the only one carefully observed commencing with a sudden spring to the feet, clasping his hand to the left ear with the exclamation, "O God, my ear," reeling two or three times to the left, and falling unconscious. Recovering shortly, no discomfort of the ear was present, nor had he any recollection of the attack or of any aura.

Examination showed the hearing normal on the right for voice, watch, and tuning-fork, with slight retraction of the drum-membrane and undue injection of its vessels. On the left, the canal was almost closed about half way in by an exostosis arising by a broad base from the lower posterior wall, and the narrow chink was filled with

[1] Read by abstract.

muco-pus, partly inspissated. Syringing brought away considerable epidermal debris from behind the exostosis, but more was seen to remain and could be but partially dislodged by probing and renewed use of the syringe. The patient flinched badly at any touch, and the surface of the bony nodule seemed hypersensitive. On the following day, after boric insufflation, the chink was less narrow, cleansing was more complete, although increased sensitiveness was complained of, and granulations could be seen in the region of the short process. No perforation was visible, but fluid passed into the pharynx in syringing, and inflation blew out the boric powder without whistle. He had long been able to blow smoke out through this canal. I communicated my finding to Dr. Lloyd, with the suggestion that ether might be necessary to complete the cleansing and exploration; and that if cholesteatoma were present, operation would be indicated.

He returned two months later with further increase of his epileptiform attacks, in the two latest of which he had rotated three times to the left before falling, and had distinct convulsive movements of the face, arm, and leg of the right side, occurring in the order named. While still unconscious, he picked constantly at the left ear. He made no complaint of the ear, which showed an epidermal flake closing the chink, and a little more epithelium beyond. The small red granulations were still present above. Mastoid trephining was advised as an exploratory measure, to be pressed further, if indications appeared. The patient was an inebriate, and had for several years been incapacitated from business; but his temper and mental condition seemed to be growing worse.

Operation was agreed to by the patient and his friends, and he was admitted to the Polyclinic Hospital for a week of abstinence and watching before the trephining. No further attacks occurred, his temperature and functions

were about normal, his eye-grounds and fields showed no decided abnormality, and his hearing remained the same. Loud voice was heard with difficulty; the tuning-fork at 2 cm.; Rinne negative, but the sound lateralized to the left from the vertex only when the canal was closed. The diagnosis was: Disease of the attic and antrum, probably cholesteatomatous, with slight involvement of the labyrinth and adjacent meninges.

The operation was done under ether on April 25th, with the assistance of Dr. John B. Deaver and in the presence of Drs. Lloyd, Roberts, Morton, Freeman, and others. The side of the head had been shaved, thoroughly washed, and a bichloride moist dressing worn for twenty-four hours, as there was a scar in the temporal region, caused by severe cutting from the explosion of a bottle of gunpowder in boyhood, which might also require exploration. Investigation showed this to be so superficial, however, that it was deemed needless to explore it. The mastoid was freely uncovered by a three-inch curved incision half an inch back of the auricle, and, as its surface proved very hard, a 15 mm. trephine was used to penetrate the outer table. Previous measurements of the head had proved the patient decidedly brachycephalic (187 : 153, with an inter-mastoid breadth of 140); so, although the operation was on the left side, a low middle cerebral fossa and an anterior sinus were to be expected, according to Kœrner. The trephine had been placed higher than desired, by reason of slipping; so it was laid aside before the button was loosened, and the removal completed with the chisel. No pus or pearly mass was found in the apparently healthy and slightly pneumatic mastoid, and the wound was carried deeper with the gouge until the antrum was freely opened. Here bare bone was felt in all directions, but no collection was present; irrigation passed freely into the canal and somewhat to the throat; and as no indication for further

penetration could be found, the wound was packed with bichloride gauze after dusting with aristol, the canal packed with boric powder, and a bichloride dressing applied with firm pressure.

No decided reaction followed; there was little pain to disturb rest by day or night, the dressings were but slightly stained with bloody serum, the packing was generally odorless and gave ready exit to all secretion, and irrigation passed freely. I left him on the eleventh day to attend the American Medical Association, directing that the dressing should be changed in forty-eight hours and could then remain the forty-eight hours until my return. His condition seemed entirely satisfactory, except that the uncovered bone in the wound seemed very slow to granulate.

Returning on the fifteenth day after the operation, I found my patient not so well. He had suffered quite severely with a colicky attack, for which no indiscretion could be found as a cause, and change of dressing revealed a moderate quantity of pus in both canal and wound. That afternoon there was a sudden rise to 101° of the temperature, which had been about 99° for several days, and the next day he complained of great tenderness at the angle of the jaw on the left, with pain greatly increased by any swallowing. There was some redness and swelling, and the mouth could not be opened wide enough to show the condition of the tonsils. No mastoid tenderness or change in the wound, and on deep palpation no evidence of jugular involvement. The bowels were confined, the tongue was coated, and the patient restless and anxious. Calomel was given every hour in one-fourth grain doses, ichthyol ointment used freely over the painful region, a fever mixture given, and sulphonal, as a sleeping draught. The temperature fell to normal and the neck grew less troublesome; but severe headache set in and the bowels could not be evacuated. Dr. S. Solis-Cohen kindly saw him in consultation

with me, and found some gurgling with tenderness in the iliac fossa, and a few atypical rose spots; but doubted if it were typhoid. Dr. Lloyd also saw him, and agreed that the mischief was probably meningeal. On May 12th, there was subnormal temperature, without notable rigor, followed by a rise to 101°, then a fall to normal on the following evening, as the bowels were at last moved by repeated doses of croton oil; but from this time the rise was higher each day, with marked fluctuations. There was little nausea, but the tremulousness of the preceding days increased to marked subsultus, the headache was as much complained of when the patient was aroused, but restless stupor grew more heavy and unbroken. The eyeballs were rolled up, but had good movement in all directions, the pupils were equal and mobile, and the eye-grounds showed only some fullness, and, perhaps, tortuosity of the veins. On the 14th, slight facial palsy of the left side appeared, with ptosis, unequal pupils (5 : 4), and conjugate rotation of eye and head to the left. All evidence of trouble below the mastoid had disappeared and only some stiffness of the left sterno-cleido-mastoid remained; there was also rigidity of the muscles of the back of the neck, with slight opisthotonos. The delirium and convulsive twitching were incessant, the stupor heavy, and the temperature shooting above 105° at times, in spite of the steady application of the ice bag to the head and frequent cold or even iced spongings of the arms. Milk was well taken from a glass, his fever mixture and calomel given without difficulty, and the sphincters were under full control. The pulse was full and strong, rising above 110 only as the result of severe convulsive disturbances; the respirations irregular, but little hurried. Desperate as his condition was, the strength seemed great and recovery not utterly hopeless. The wound was doing well, with only a trace of pus, and the superficial portion healing nicely. Brief snatches of quiet sleep were also gained.

From this time, however, the decline was rapid. From the afternoon of the 16th (twenty-one days after operation) there was unconscious evacuation of the bowels, slight convergence due to paresis of the right externus appeared, with increased nystagmic motion, and some vomiting of his medicine began. During the night his free fluid stools became blood-streaked; so the calomel was replaced by mercurial inunction; but the bleeding continued sufficient to stain every cloth with bright red clots or spots. The temperature rose to 106°, partially controlled by cold spongings, coma deepened, the respiration grew more irregular and labored, with increased frequency of the pulse, and he died on the afternoon of the 18th, the twenty-third day after the operation.

The autopsy was made four hours after death, with the assistance of Drs. Lloyd, Lincoln, and the resident Dr. Baldwin. The body muscular, well nourished, and with little rigor mortis. The scalp showed intense engorgement and oozed many ounces of dark blood during the examination. The skull-cap was normal, rather strongly adherent, with no lesion at the site of the old scar in the temporal region. The dura seemed normal at every point, the meningeal sinuses rather gorged but free from clots, and the arachnoid fluid little increased. There was marked sub-arachnoid purulent effusion and some œdema over the entire convexity and, to a less extent, at the base of the cerebrum, with no other gross lesions. The brain was firm, its ventricles moderately distended, its vessels full; but no notable lesions, recent or old, could be found in Dr. Lloyd's careful study, except the purulent effusion of the surface. The temporal bones seemed normal, without even discoloration of the dural covering; there was no trace of thrombosis of lateral sinus or jugular; and dissection proved the surfaces everywhere normal, except at the canal and at the site of the open wound. The pos-

terior half of the attic, with the antrum, was denuded and slightly eroded. The malleus handle was lost and the stapes freed by destruction of the shank of the incus. The round and oval windows seemed normal, and slight accidental violence dislocated the stapes into the vestibule. The external canal was nearly closed by the broad-based exostosis of eburnated tissue (Fig. 1); and only a little epidermis was found beyond it on clearing away the soft tissues from the surfaces. The drum-membrane was occupied by a large round central perforation, the upper margin of which was new formation (Fig. 2). The mastoid wound



FIG. 1.



FIG. 2.

showed healing of only its upper superficial part, the bone-sinus being but imperfectly covered with granulations. The antrum was opened completely by the operation, without injury to the facial canal or labyrinth; but the trephine opening, having been placed too high, was dangerously close to the cerebral fossa, and not far from the lateral sinus. The right lateral sinus was more anterior and external than the left, making a much more dangerous bone than the one which I opened. The thoracic organs showed old lesions, the pleuritic adhesions being extensive and strong, and the

apices filled with marked contracted cicatrices, apparently the result of the healing of cavities. The heart was apparently normal, with perfectly closed septum — he had been a "blue baby" for months after birth. The abdominal organs seemed healthy, as far as studied; but the examination had to be cut short before the intestinal tract was laid open and the source of the bleeding determined.

Several points received little light from the operation or the autopsy. The evidences of localized brain lesion were uncertain up to the time of the trephining, since the temperature and functions were generally nearly normal, with only such abnormality as would be accounted for by the chronic carious process in the tympanum. Bromide was given in small doses during the week before operation and to a less extent afterward, and to this may be due his immunity from further epileptiform seizures, none of which occurred while he was in the hospital. The pressure of the exostosis, or of collections beyond it, does not seem to afford adequate cause for such attacks, since there was little evidence of such pressure at the time when they occurred; so the labyrinth would seem the seat of the irritative process, were it not for the convulsive movements, which seemed to point to the cerebral cortex. At the autopsy, the recent meningeal process totally masked any preëxisting cortical lesion, and nothing to indicate previous involvement of the disturbed motor centres could be found of older date than what appeared on most of the brain surface. The labyrinth, so far as investigated macroscopically, did not furnish any explanation of the symptoms; but I hope by microscopical investigation to determine its condition more fully and accurately than was possible by simple dissection.

So far as the case is open to my present comprehension, the epileptiform attacks were due to localized carious inflammation in the tympanum, reflexly irritating the laby-

rinthine and cerebral structures. As to the fatal issue, which seemed in no way imminent before the operation and for which the uncovering of bone in the tympanum does not furnish adequate explanation, I can ascribe it only to septic absorption through the open bone along the trephining track. Yet I fail to see what further precaution should have been taken in order to avoid such a result.

It has seemed not uninteresting, as a supplement to this individual case, to review my experience in cases at all similar, and to bring before you some of the post-mortem results which I have met. Looking back over my records, I find fifteen deaths noted among about five thousand ear cases seen in the last six years, although others dropped out of sight in such desperate condition as to suggest that my death rate is really larger. Several of these cases were comatose, with pronounced intra-cranial mischief, when first seen; while others had made more or less good recovery from all ear trouble or had passed out of my care before death. Yet it seems best to group them all together, as each capable of affording some information bearing on the question of the paths by which aural inflammation is propagated to the brain or meninges.

The most important case, in many respects, was that of an elderly lady who consulted me in March of this year, with a history of severe pain and some deafness on the left side since a slight cold-taking three weeks previous. There was slow gain in hearing and less pain under counter-irritation and tonic measures, she could hear the distinct voice with some difficulty, though not a whisper, the tuning-fork better by bone and lateralized to the left from the vertex. The mastoid integument was altered by iodine-painting, but revealed no œdema, and the bone was but little tender to firm pressure or percussion. The drum-membrane showed some retraction as on the right, with slight pinkish injection along the manubrium and at

the posterior margin. As she was improving, continuance of mild measures was advised, with care of the naso-pharynx. Nine days later I noted: "Slow gain, flitting pains; mastoid resented iodine, replaced by oil and turpentine; continue hot syringing if pain recurs." I did not see her again; but learned from her attending physician that after slight further gain, she had an accession of serious symptoms, with high fever and occasional chills for several weeks and died of a large brain abscess. The autopsy showed an opening from the mastoid beneath the lateral sinus, communicating with the abscess, which must have been cerebellar, from the location of the opening, as the specimen shows. Tympanic involvement was very slight when I saw her, indicated merely by faint injection and impaired hearing; and, so far as I know, the clinical and autopsy data coincided in proving that the suppuration was limited to the mastoid cells and the adjacent intra-cranial structures. Such primary mastoid abscesses are rare.

Another recent case I was able to follow through the kindness of Dr. J. Hendrie Lloyd. He invited me to an autopsy similar to the first cited in this paper, in the case of a patient at the Home for Crippled Children. I was surprised to find that it was a former patient of mine, whose record is as follows: Helen R., admitted to the Children's Hospital, April 6th, '88, with incipient coxalgia, soon after came under my care for suppuration of the left ear. There was persistent polyp formation and caries at the upper margin of the drum-membrane, with no perforation of the membrana tensa. After repeated removals of polyps and gentle curettings with merely temporary benefit, all possible dead bone was thoroughly removed, under ether, on June 28th, '90, opening the attic and antrum by removal of part of the upper and posterior walls of the canal. Marked improvement followed, with remission of suppuration, and

she was transferred to the Home on Feb. 18th, '91, walking a little, but with eversion and dragging of the left foot. A month or two later she grew worse, developed meningitic symptoms early in June, and died July 1st. There was, toward the end, paralysis of the right arm, convergent strabismus from paralysis of the right externus, and double protophthalmos.

At the autopsy on July 2d, marked purulent meningitis of the entire brain surface was found, with a superficial abscess in the Rolandic fissure. There was septic thrombosis of the left inferior petrosal, of both cavernous sinuses, and of the transverse sinuses uniting them. Caries was evident at the sella turcica, involving the sphenoid and the tip of the left pyramid, and, on dissection, a similar area below the internal auditory meatus. The tegmen tympani and its dura were normal, as was also the entire inner aspect of the bone, except at the points mentioned.

An interesting series of specimens were obtained from another case at the Children's Hospital, — Marie W., aged 4, who was admitted Aug. 22d, '88, suffering with mastoid abscess on each side and strumous suppuration of the thumb and elbow joint. Left facial paralysis was complete, with considerable fœtid discharge from both auditory canals and from small sinuses behind each. When I first saw her in October, both temporals showed marked caries, the canal on each side was nearly filled with polypoid granulations, more marked and obstructing on the left, and dead bone could be felt in all directions. Successive crops of polyps were snipped off, the ears kept clean by free syringing and boric insufflation, and a number of sequestra, some as large as could be extracted through the meatus, were removed from each side. These were generally black and friable and their exact character and origin not recognizable. The discharge soon decreased in quantity and was less offensive, granulation was slightly

redundant only on the left, and, although the loss of substance evidently involved the left labyrinth and seemed almost as great on the right, the child had undoubtedly some hearing and recovery seemed possible. Hectic fever was now apparently due to the joint lesions, so she was transferred to a colleague for the required excisions. Healing progressed fairly; but the child lost ground and died at the close of the year. An hour before death several ounces of very fœtid pus suddenly gushed from the left ear. No paralysis had been present except that of the left facial, and when, in the middle of December, I undertook an ophthalmoscopic examination, the unremitting movements of the child and the rolling of the eyes completely foiled me, in spite of dilated pupils and a persistence as long as justifiable in view of the child's weakness.

The autopsy was made by the Resident, Dr. Eckman, in my absence. The body was much emaciated, the meninges apparently normal, except over the left tegmen, where the dura was destroyed around a ragged opening in the bone. An organizing clot occupied the outer part of the left lateral sinus, but was loosely attached to the apparently healthy wall, beneath which the bone was normal. The convexity of the brain appeared normal and there was little exudation about its base. A large abscess cavity in the left spheno-temporal lobe had evidently burst, and evacuating itself through the gap in the roof of the tympanum, had given rise to the gush of pus at death. Further laceration of the softened tissues took place in the removal of the brain and a communication of the abscess with the left lateral ventricle, which probably did not exist during life. The internal auditory meatus was full of pus, with no trace of either seventh or eighth nerve. Both seemed normal on the right, as did the right hemisphere, the cerebellum, and the medulla. The lungs were full of cheesy nodules, more numerous on the left, where some had

broken down into cavities as large as a big pea in the apex and elsewhere. The heart, kidney, spleen, and other organs seemed normal. The optic nerve sheaths were not distended, but there seemed swelling of the nerve margins.

In the temporal bones, as laid before you, the mastoid sinuses remain, and section of the right bone shows the large cavity nearly healed, with only some carious areas near the stapes, which preserves its place.

A fourth case leaves a doubt as to whether the meningitis was of otitic origin. A boy of thirteen months was referred to me at the Children's Hospital in June, with chronic suppuration of the left ear and total facial palsy of some weeks' duration on that side. The carious malleus was at once removed, and the bare incus, a week or two later; but the uncovered promontory and rough upper tympanic margin remained firm. The discharge improved slightly, the facial palsy disappeared, the child grew heavier and ruddier but more irritable, somnolent, and weak. He became worse, with slow, difficult breathing and occasional vomiting, and died on August 24th, with slight convulsions for the last day. The autopsy, five hours after death, showed the dura rather abnormally adherent, but internally normal, the sinuses full of dark clots, the brain gorged, but with little œdema or excess of arachnoid fluid. There was marked distension of the ventricles, the choroid plexus was studded with gray tubercle-like nodules, and there was abnormal adhesion in the longitudinal fissure. In the middle of the second frontal convolution was found an indurated girus; a hard mass at the outer margin of the right corpus striatum seemed a breaking down gumma; and a similar solid mass was buried in the centre of the left lobe of the cerebellum. There was no ante-mortem clotting, and the inner surface of the temporal seemed normal; but on reflecting the dura, a

honey-combed area of the tegmen was found, with a villous pachymeningitis sealing the gaps. A similar involvement of the bone was present on the outer surface of the mastoid, which had given no recognizable symptom to careful study during life. Microscopical study shows the nodules to be tubercular.

In this case, the aural condition seemed to be mending, and the cause of death an internal hydrocephalus of tubercular or possibly syphilitic origin; but it may be that more thorough study of the specimen will reveal a more unmistakable channel of communication.

An interesting case in this connection I reported to the Philadelphia Pathological Society, May 14th, 1885 (Transactions, Vol. XII.), where there was extensive destruction of tegmen and honey-combing of the wall of the sinus, without any involvement of the inner surface of the greatly thickened dura. There was tough, thick, purulent exudation covering the pons, medulla, and adjacent portions of the base, with some œdema of the convexity, and the channel of infection was evidently the internal meatus, the lining of which was detached, ulcerated, and, with the nerves, thoroughly infiltrated with pus. In life, the empty oval window and the open facial and horizontal semi-circular canals had been recognizable through the external meatus and the extensive mastoid sinus, and gave full explanation of the total facial palsy and the fatal termination. The specimen has been unfortunately mislaid, and I can only show a poor photograph of the inner surface, with its deflected dura.

Another fatal case had meningitic symptoms for three weeks before aural symptoms appeared and then had suppuration of each antrum, apparently due to extension of suppuration outward. There was copious exudation over the entire base of the brain and throughout the spinal column. The convulsive symptoms so long preceded the

aural as to render the extension of inflammation inward almost incredible, and no channel of communication was discovered; so the coincidence remains unexplained.

NOTES ON THE USE OF THE LEITER COIL IN THE EARLY STAGE OF MASTOID DISEASE.

By Gorham Bacon, M. D., *New York City, N. Y.*

On looking over the standard works of Otology and the literature published in this country, I find but little if any mention made of the employment of cold, whether by means of the ice bag or the Leiter coil, in the early stage of mastoid inflammation when the symptoms are very acute.

On the other hand, in Europe, more especially in Vienna, the use of cold in such cases is considered by many of the greatest importance.

Politzer says: "The results which I have recently obtained by the use of Leiter's apparatus in cases of acute inflammation of the mastoid process have been most favorable, as the inflammation completely subsided without local bleeding. I am convinced that by the timely use of this apparatus the termination of many cases in abscesses and caries can be prevented."

According to Thomas Barr of Glasgow, "this method of treatment (cold) is now being adopted in this country. By this mode of treating mastoid inflammations at an early stage and when the symptoms are very acute, great relief is usually obtained, the inflammation being not unfrequently cut short and suppuration prevented."

It has been my practice for several months past at the New York Eye and Ear Infirmary, to apply the Leiter coil in all cases of mastoid disease, if seen in the acute stage

before suppuration has commenced. The pain is usually greatly relieved. It is highly important, however, to note carefully the pulse and temperature of the patient. If any rise in temperature occurs in spite of the application of the coil, although the pain is relieved to some extent, I should be inclined to adopt other means at hand, as I would not be understood to prefer this method of treatment to the exclusion of all others.

After the use of cold, I believe the next most important means at our command to be the local abstraction of blood by means of the scarificator and wet-cup. Should the latter not suffice to cut short the inflammation, a Wilde's incision should be made at once, or if necessary, the mastoid should be trephined.

I have not as yet had an opportunity to try this method of treatment very extensively, but in all cases where the coil has been applied, the results thus far have been most satisfactory.

DISCUSSION.

Dr. McKay:—I have nothing particular to say with regard to Dr. Knapp's cases, except that I think that free leeching in such cases will avoid an operation,—repeatedly leeching, if necessary; such has been my practice, and I have not had occasion to cut the bone more than a few times.

Dr. Burnett:—I would like to ask Dr. Knapp why he did not make an incision into the membrana tympani in the case of so-called sclerosing mastoiditis when he first saw the case.

Dr. Knapp:—The affection in this case pointed very much to a mastoiditis, but the bulging of the drumhead was nothing more than what we frequently see in aural disease, especially in disease of the attic. I admit

that paracentesis might have been done, but whether or not it would have relieved the patient very much I was in doubt.

Dr. Sutphen:—I would like to refer to one case which is very similar to the second case reported by Dr. Knapp. Six months ago a man came to me with acute otitis media, and I incised the drumhead. The ear discharged for about two weeks, and then the opening closed. Four or five days after this he returned, complaining of excessive pain. The drumhead was purple and somewhat bulging. I incised the membrane and let out only a drop or two of thick pus. The man was relieved for a few hours, but then began to have excessive pain located in the mastoid. He came to my office, but not finding me in at the time, went to his family physician, who gave him large doses of morphia without any benefit. When I next saw him he had had for twenty-four hours the most excruciating pain, with some nausea. The opening was still existing in the drumhead. There was no swelling over the mastoid, but pain, on very deep pressure, increased when the mastoid was "thumped." As no relief could be obtained in any way, I concluded to open the cells. After doing so, I was surprised not to find any pus, but in its stead a serous fluid. The man had no pain following the operation, and there was no discharge of pus from the middle ear, nor from the mastoid. The case went on to a rapid recovery. Apparently the liberation of the fluid confined in the cells afforded the patient immediate relief.

Dr. F. M. Wilson:—I was much impressed in listening to Dr. Knapp's article on two cases of pus in the temporal bone, as it was a reflection of my average experience and of my opinion upon cases of this kind, viz., the uncertainty of them. If you will remember, two years ago the statement was made in one of the discussions that we were all at sea in regard to these cases. I took exception to

that statement at that time, and I take exception to it now. At the same time, I would take equal exception to any absolute rule in these cases. I take it from my own experience, and from the experience of men with whom I have talked, that these cases are uncertain; that they bother us; that we cannot rely upon any single symptom. I think it would be as useless as to rely upon one sympton in sympathetic ophthalmia. It is the combination of symptoms, the whole history of the case, which makes us do one thing or the other.

One point in Dr. Blake's paper struck me quite forcibly, I having within three months seen two cases of pyæmia, in which the line of extension of the purulent process was from the mastoid down the sterno-cleido-mastoid muscle, leading in one case to superficial abscesses, with recovery; and in the other, to abscesses of the lung, and death. It seems to me an important point not to enter the muscle if you can get at the parts that you wish to reach without it. I think if you cut into the sterno-cleido-mastoid muscle you are more apt to have pus burrowing into the neck.

Dr. Gruening:—As to the point mentioned by the gentleman who just spoke, I said that a symptom which is constant in these cases is that of tenderness, and that I would be willing to operate on a mastoid if only this symptom were persistently present.

Secondly, this gentleman said that it is indiscreet to cut into the muscle. I said that I cut tendinous attachments of the muscle away from the mastoid in every case, exposing the mastoid so that the bone is denuded everywhere, and an inspection of its surface can be had.

Dr. Burnett:—In several cases where the only objective symptoms have been the redness and protrusion in the upper posterior portion of the membrana tympani, with some pain in the mastoid, I have found that an incision into the swollen and reddened membrana tympani relieved

the patient, whether it gave vent to pus or not; so that my experience in very many cases has been similar to that of Dr. McKay.

Dr. Knapp: — Of course — for such has been my experience — I have made successful perforations where there has been persistent pain, but no pus found.

I would like to make some remarks on the papers read by Dr. Gruening, Dr. Blake, and Dr. Bacon. Dr. Gruening mentioned that Profs. Bergmann and Kuester said that aurists were not surgeons, but I think we may reply that surgeons are no aurists. They simply cut away, with the object of saving life without much regard to the preservation of the function of the auditory organ. The element of uncertainty in diagnosis is what puzzles us mostly.

With regard to the points raised by Dr. McKay: I use leeches most freely; if I did not speak of them in my paper, I will do so now. It relieves the patients very much; so does cold: but another element which I think is more important than leeches, is rest. If an acute case of tympanic disease coming from sea bathing or any other cause, with the sodden appearance of the drumhead and trouble in the attic or lower, comes to you and you put these people to bed without doing anything, you will almost always find a surprising improvement.

With regard to the perforation of the tympanic membrane, I dislike doing anything that might damage the tympanal apparatus and refrain from all operative procedures as long as I can help it. As regards the rapid recovery after artificial perforations of the mastoid in acute inflammation, I reported a case to this Society about twelve years ago, which is mentioned in the Transactions,[1] where I opened the mastoid, found and evacuated the pus. In two weeks the membrana tympani, and in four weeks, the open-

[1] Vol. II., No. 3, p. 350, 1879.

ing in the mastoid, were permanently closed. As to interference with the tympanic portion of the auditory apparatus, I try to avoid this as much as I can. I remember one case where I simply incised the upper portion of the tympanic cavity, — in a chronic case, — and the symptoms were so alarming that for six or eight weeks the man had to lie in bed.

I think that in the majority of cases of tympano-mastoid inflammations, there are excrescences and swellings of the normal folds of the mucous membrane lining the pneumatic cavities of the middle ear. In the case I had for operation they were pedunculate and distinctively swollen. On the whole, I consider the mastoid a safer and more effective outlet of morbid material than the tympanic membrane. Less rigidity of the ossicles and less destruction of the tympanal membrane will be left behind. If you pierce the drumhead in a case of congestive or simple catarrh, you open the door for the germs, and in a day or two the catarrhal inflammation may become a purulent one. In all doubtful cases I therefore withhold paracentesis of the membrana tympani as long as I can.

Dr. Burnett: — My question applied to acute cases in which the membrana was entirely intact and the ear previously normal. I understood that Dr. Knapp's case, the last one, was entirely such an acute case of so-called sclerosing mastoiditis. My remarks had reference only to such cases. So far as the mastoid is concerned, I would be willing to take the risk of germs perhaps more readily with the opening in the drum-membrane than in the mastoid. Certainly, if the mastoid process is open and communication established between it and the drum cavity, germs can get into the drum cavity as well as if it were opened through the membrana tympani. Perhaps, however, reference was made in these cases to chronic diseases, and my remarks had reference to acute cases.

Dr. McKay:—I would like to dwell a little more upon the point which I referred to in my former remarks. I simply want to say that repeated leeching often relieves cases, without operation; at least, that has been my experience.

Dr. Burnett:—I think that in the abstract Dr. Randall gave, he failed to touch upon a prominent and important matter, which Dr. Blake may have met with in his experience, namely, cases of chronic tympanic disease, in which there is long continued pain in the ear, well marked necrosis of the inner wall of the drum cavity, and sometimes facial paralysis, but no mastoid symptoms. I have seen three such cases lately, but I do not like to take the time of the Society in describing them. Two of them proved fatal and one recovered. I am not aware that any of the gentlemen who have read papers have touched upon this matter. I wish to know the opinion of the Society upon these cases of tympanic disorder, giving no indication whatever of disease in nor indications for perforation of the mastoid.

Dr. Randall:—One of those cases covers to some extent the point raised by Dr. Burnett. There was uncovering of the promontory and the upper margin of the tympanic bone, with exfoliation of malleus and incus, without indication of mastoid inflammation. The child had internal hydrocephalus and tubercular lesions throughout the brain; and, on dissection, caries of the tegmen and mastoid surface was revealed, without any direct extension of the otitic inflammation to the intra-cranial structures. The child was thirteen months old, and could give no certain location of pain, if any were experienced. The facial paralysis grew steadily better, and the child, from an otological point of view, gradually improved under rather expectant treatment. Death took place of tubercular meningitis; and the examination, while it showed caries of the tegmen and caries of the exterior of the bone, showed also

that there was no communication between the temporal bone and the brain cavity. Death was due to intra-cranial disease, which was probably common to both affections, and the large masses of tubercular deposit had probably no direct dependence upon the tympanic lesion.

Dr. Knapp: — Some years ago a case came under my notice which struck my attention very much. It was a severe otitis media purulenta, terminating fatally. At all times the mastoid region and vicinity had been normal. At the post-mortem, I found the whole external cortex healthy, the inner cortex broken down and communicating with a large collection of pus in the sigmoid sulcus. The very instructive case is reported in the Archives of Otology.[1]

Dr. Burnett: — Of the three cases alluded to, two died, one of advanced phthisis, the other of pyæmia. The remaining one, a child, had not much pain, but necrosis of the inner wall was present, which finally healed, and the child got well.

---

[1] Vol. XII., p. 44, 1883.

EXCISION OF THE MEMBRANA TYMPANI AND NECROTIC MALLEUS IN FOUR CASES OF CHRONIC SUPPURATIVE OTITIS MEDIA.[1]

By Charles H. Burnett, M. D., *Philadelphia, Pa.*

This paper gives an account of four cases of chronic purulent otitis media, in the first three of which all forms of rational routine treatment were pursued for long periods before resorting to the surgical procedure. In the last case, as long continued treatment of the suppurating ear, at the hands of other physicians, had failed to give relief, I at once resorted to excision of the remnant of the membrane and carious malleus. The caries of the malleus was not recognized, though it was suspected before the operation, in the first two cases. It was known to exist in the last two before the operation. In all of the cases, the patients were etherized and the ear illuminated by the electric head-lamp during the operation. The cases were all in the private practice of the writer.

Case I. — Mr. W. H. R., aged 30 years, was first seen April 11th, 1889, in consultation with his physician. The patient was in bed, where he had been for some days. It was stated that he had had chronic purulent discharge from the right ear since childhood, but that nothing had ever been done for it. Four days previous to the consultation, he was suddenly attacked in the street with nausea and dizziness, attended with a sudden discharge of bloody serum from and pain in the ear. The hearing was reduced to zero; the tuning-fork on the vertex was not heard

[1] Read by abstract.

in the affected ear; the Eustachian tube was pervious to Valsalva's inflation. Examination of the ear revealed a large perforation in the membrana flaccida, covered by a polypus. The malleus was maintained in an upper posterior white remnant of the thickened membrane. Anteriorly, stretching from the anterior portion of the annulus tympanicus to the promontory over the tympanic mouth of the Eustachian tube, was a thick, red, denuded, and secreting diaphragm, perforated in its centre, through which air and a little mucus would pass, upon Valsalva's inflation.

Treatment. The ear was at once regularly cleaned and antisepsis maintained by injections and instillations of carbolic acid solution (2.50%). The vertigo gradually ceased in ten days after I first saw the patient, and he was able to leave the house. The polypus was then removed by a wire-snare without pain or hemorrhage and the pedicle touched with a minute quantity of chromic acid. A powder of iodoform and boric acid (1–7) was insufflated into the ear, and antisepsis maintained for some weeks by insufflation of this powder and injections of the carbolic acid solution named above. The discharge diminished and the polypus did not reappear. Upon sudden motion and muscular exercise, as at lawn tennis, the patient would feel considerable dizziness and he therefore desisted from the game for some weeks. By July 1st, two months from the time of the first examination, the discharge from the ear had become very slight and the patient went on a journey for two months, using during this time daily instillations of alcohol, but no syringing. By September 1st, when the patient returned from his vacation, the discharge was slight, but offensive in odor, coming from the attic of the tympanum. However, the use of peroxide of hydrogen and antiseptic injections with the tympanic syringe, into the attic space, several times a week, failed to check the

purulency. Neither these, nor careful antiseptic instillations by the patient every day at home, continued for months, succeeded in checking the annoying and ill-smelling discharge. Necrosis in the attic was suspected, and the operation subsequently revealed it, as the cause of this obstinate discharge.

Therefore, on June 17th, 1890, over a year from time of the first examination, the patient was etherized, and the remnant of the membrana tympani with the malleus was excised. The hemorrhage was inconsiderable. The head of the malleus was partly destroyed by necrosis. Dense synechial bands were attached firmly to the neck of the malleus and granulations covered the inner surface of the membrana tympani. A probe passed into the attic revealed an ample space without trace of incus or stapes. There were some granulations in the attic, which were broken up by the probe. Antisepsis by means of peroxide of hydrogen and a solution of carbolic acid (2.50%), preceded by syringing thrice daily, was kept up by the patient at home. The discharge began to diminish greatly now that necrotic tissue was removed and drainage improved, and in a few weeks the antiseptic treatment was applied only once daily; then every other day, as the discharge diminished, and, finally, only when the discharge was perceived in the ear, which occurred at longer and longer intervals. By March 7th, 1891, the ear was entirely free from suppuration or discharge and has remained so. The attic space is dry and white; the diaphragm in front part of tympanic cavity is pale pink and dry, being covered with epithelium. Air passes through the perforation in it, without mucus.

The attack of vertigo, pain, and discharge of bloody serum from the ear, which first lead the patient to give serious attention to his running ear, was due, in the writer's opinion, to an irruption of the chronic purulent disease into the vestibule through the stapes. This would cause

the sudden vertigo and pain, and the presence of the polypus, which bled readily, would stain the serum which had escaped from the labyrinth. The cure of the discharge in this case, due entirely to the operation, proved a great benefit to the health of the patient.

Case II. — Helen S., aged 13 years, a full blonde, who has not yet menstruated, was brought to me for treatment, May 5th, 1890. Her father stated that his child had been afflicted with chronic purulent discharge from the right ear for five or six years. The disease had come on originally without any known cause, and had seemed to vary with the child's health, especially being worse with a cold in the head. Periods of six months had elapsed during these years without any discharge from the ear. Several years ago, following an attack of ear-pain, an abscess formed behind the ear, and was opened by a well known surgeon, giving vent to considerable pus.

The treatment of the ear had been done at home, and consisted in instillations of a solution of boric acid and, latterly, in insufflations of boric acid powder. Examination of the patient revealed a sunken cicatrix behind the auricle, over the region of the mastoid antrum. The membrana tympani was sunken and macerated by a little pus at the fundus of the canal, and there was a perforation in it, below and in front. There was a small polyp attached to an exostotic elevation near the upper posterior quadrant of the insertion of the membrana tympani. The hearing was reduced to one inch for the large tuning-fork, *per aer*, and for isolated words about six inches. The polypus was removed by the wire snare and its pedicle touched with a little chromic acid. Boric acid was then insufflated and antisepsis maintained by occasional syringing and daily instillations of a bichloride solution,[1] for

[1] Hydrarg. bichlor. gr. ¼, acid tartaric gr. x, aquæ *f*℥ iii.

three weeks, but this treatment seemed to increase the discharge.

Knowing of the long treatment with boric acid, and also perceiving that local treatment at my hands seemed to make the discharge worse, and that the perforation in the membrana tympani was too small to permit good drainage from the tympanic cavity, with its swollen mucous membrane, nor the entrance of medication to the diseased drum cavity, I proposed excision of the membrana tympani and the malleus.

The patient was etherized June 11, 1890, and the membrana and the malleus were excised. Granulations were found blocking the drum cavity, on the promontory and on the inner surface of the membrana tympani. The hemorrhage was considerable and the operation tedious on this account and also as the malleus was adherent to the inner wall of the drum cavity. The head and neck of the malleus were not necrotic but granulations were attached to the neck. The lower end of the manubrium was destroyed by necrosis. The incus could neither be seen nor felt.

From this time the discharge became very slight, not enough to appear at the meatus. Antisepsis was kept up by iodoform and boric acid powder (1–7) and syringing every few days. In two weeks the hearing was found to have advanced from *ten inches* to *four feet*. During the following two months the ear was syringed once or twice a week with alcohol and water (half ounce to the pint). In September, three months after the operation, the ear was found to discharge with a cold in the head, but to be quite dry in the interim.

Since then, *i. e.*, for a year, the ear has generally been entirely dry part of each month, to begin again to discharge. The discharge seems to come from the Eustachian region, the anterior part of the inner tympanic wall

being red and granular at times. The upper posterior part of the drum cavity is dry and white like the front part of the cavity, part of each month. Air is forced from the Eustachian tube by Valsalva's inflation. As the menses have not been established, the patient being in her fifteenth year, the alternating conditions in the drum just mentioned suggest a vicarious action.

At present the treatment consists in daily instillations of peroxide of hydrogen, the syringing with salt and water (5%), and then an instillation of a solution of sulphate of copper (gr. i to ℥i). The hearing is at present ten feet, measured in the presence of her father.

Case III.—Miss F. D., aged 48 years, has been annoyed with suppuration in the left attic for years, the discharging pus coming from a perforation in the membrana flaccida, the rest of the membrana tympani being intact. At times there would be collections of cholesteatomatous scales in the attic, which would stop the perforation and mechanically check the discharge. This was invariably attended with pain, disagreeable head symptoms, and depression of spirits. The hearing diminished to nothing. I had seen the patient at long intervals during ten years previous to her visit to me in April, 1890. She then stated that she had been annoyed for some months by a slight, offensive discharge and that she had removed some flakes (cholesteatomatous) from her ear. Latterly, the ear had grown sore and painful, and there was some dizziness. She had heard of excision of the membrana tympani and asked to have it performed on her, if I approved of it. Examination revealed a large perforation involving the membrana flaccida and the segment of Rivinius, in which a large, tough, whitish plug was seen protruding from the attic space. Some of this was picked away and some more worked its own way from the perforation, after instil-

lations of a solution of bicarbonate of soda, glycerine, and water. The discomfort in the ear ceased, and it was now seen that the attic space was entirely clear of any ossicles, but its mucous membrane was rough and granulating. The membrana vibrans with the manubrium, was seen to form with the inner tympanic wall, a pocket, in which cholesteatomatous masses had collected, probably at each attack of pain and dizziness. The hearing was nil. Therefore the patient was etherized May 7, 1890, and the membrana tympani with the manubrium mallei was excised. The hemorrhage amounted to about half an ounce. The membrana tympani was very much thickened, its outer surface white and shining; its inner surface was studded with granulations, as was also the mucous membrane on the promontory. The head, neck, and short process of the malleus were destroyed by necrosis. A little iodoform and boric acid powder was blown into the ear and the ear let alone for a day or two. By May 19, twelve days after the operation, the ear was entirely dry; the mucous membrane of the drum cavity, dry, white, and shining. Hearing=12 in. for isolated words. June 6, hearing=18 in. isolated words. The ear has remained in this healthy condition to the present time.

When this case came to me in April there was and had been for some time numbness in the tongue on the left side and a subjective metallic taste. This continued for nearly six months, gradually diminishing and finally disappeared. It was doubtless due to severance of the chorda tympani, by the same process as destroyed the incus and the head and neck of the malleus.

Case IV.—Mrs. G., of Idaho, 35 years old, consulted me July 14, 1891, for chronic purulent discharge from the right ear, and deafness. She is affected with chronic

catarrh of the middle ear on the left side. She had scarlatina at four years of age, since which the right ear has discharged. This ear has been treated by others in some way, within the last few years. The patient has always worn cotton in her ear. Examination revealed a large central heart-shaped perforation, with the stump of the malleus, round and red, looking like a polypus. The probe revealed necrosis of the lower end of the hammer handle. Hearing in the right ear=6 inches. Hearing in the left ear = 18 inches.

I at once advised excision of the membrana and necrotic malleus and the operation was performed, with patient under ether, July 17, 1891.

The malleus handle was found destroyed by necrosis as far up as the short process. The articular surface of the head of the malleus was carious. No trace of incus could be found and the caries of the malleus head leads to the supposition that the incus had been destroyed by the same process as destroyed the malleus head.

Immediately upon recovery from ether the patient heard sounds and voices in the room and in the corridor of the hospital, previously unheard in the right ear.

Examination the day after the operation showed the hearing to be 18 inches for isolated words in the right ear.

The discharge was slight and largely mucous in its nature. The patient was directed to syringe the ear once daily with salt and water (5%) and to instill ten drops of the peroxide of hydrogen into the ear.

On August 4th the hearing was found to be two feet for isolated words in the right ear, being now a better ear than the left one.

Sept. 9, 1891, the hearing is said to be six to eight feet for isolated words in the right ear, without discharge.

In the first case, the suppuration was checked in nine months. The hearing was not improved.

In the second case, the discharge has not yet been checked, after the lapse of more than a year since the operation. The hearing, however, has been improved, rising from six inches to four feet in two weeks after the operation, being ten feet for isolated words at the present time.

In the third case, attic suppuration, the discharge, and cholesteatomatous collections, were checked at once, and there has been no return. More than a year has elapsed since the operation. The hearing has risen from nothing to two feet.

In the fourth case, the discharge has been checked in about two months, and the hearing has risen from eighteen inches to six and eight feet.

The improvement in hearing, wherever it has occurred in the foregoing cases, is certainly due to the removal of obstructions to the entrance of sound waves to the middle ear. Since the operation, these waves have been falling quite directly upon the stapes and the oval window. The progressive improvement in hearing noted in all of them, is due to the gradual overcoming of an anchylosis due to long disuse of the stapes from faulty articulation or discontinuity in the diseased ossicular chain, the latter acting as a mechanical hindrance to hearing.

SOME PARTIALLY SUCCESSFUL ATTEMPTS TO PROMOTE THE HEALING OF OLD PERFORATIONS OF THE TYMPANAL MEMBRANE.

By Samuel Theobald, M. D., *Baltimore, Md.*

Although the healing of an old perforation of the tympanal membrane does not necessarily produce an improvement in the hearing, and although its continued existence does not necessarily involve a periodic recurrence of otorrhœa, there can be no doubt, I think, that, as a rule, it is desirable, if possible, that such perforations should be induced to heal; for, it is at least more than probable that the hearing will be benefited thereby, and it is quite certain that the risk of recurring otitis media will be lessened. Influenced by this view of the subject, which I have held for years, it has been my habit, whenever practicable, to endeavor to bring about a closure of old, as well as of recent, perforations of the tympanal membrane, and from time to time I have resorted to various expedients to accomplish this result. The paper discs recommended by Dr. Blake I have tried repeatedly, but with rather indifferent success. I have also tried, as a substitute for these, discs of various kinds of adhesive and isinglass plasters and of animal tissue (thin gut), but with no better effect. Another expedient which I resorted to not long since, and which at first seemed to promise good results, was the application of nitrate of silver to a zone of the membrane around the perforation, the edges of the perforation being

left untouched, the intention being to excite a slight inflammatory reaction and thus promote the building up of new tissue; but, the outcome of this procedure was in the end disappointing.

Like others who have had experience in the treatment of ear diseases, I have observed that the wearing of an artificial drum-membrane, especially that form which consists of a disc of cotton, occasionally brings about the closure of perforations even of long standing, and it is in this direction that my recent experiments have been made.

The dry, non-vascular condition in which we usually find a perforated tympanal membrane in an ear free from suppuration, is by no means favorable to the growth of new tissue, and under such circumstances even a very small perforation may, and often does, remain unhealed for an indefinite period. The opposite condition, in which a chronic suppurative process attended by otorrhœa is present, is equally unfavorable. If we would place the membrane in the most favorable state for healing, we must endeavor to reach a mean between these two extremes; it must be kept moist and hyperæmic, but suppuration must be prevented. In the artificial drum, and in the judicious use of boracic acid, we have the means for best accomplishing this result.

Formerly, I moistened the cotton pledgets which I use as artificial drum-membranes, with glycerine diluted with two parts of water, but, later, I employed for the same purpose vaseline, which I found less apt to promote the recurrence of otorrhœa and better adapted to bring about the conditions which I have described as most favorable to the healing of old perforations. When the ear is free from inflammation or discharge, the artificial drum thus prepared may be worn with good effect, both as regards the hearing and the healing of the perforation, for six or seven days; after that it is apt to get out of position. If the ear is dis-

charging, a condition which, as a rule, contra-indicates the wearing of an artificial drum, it must be changed daily and not worn during the night. With the little contrivance which I devised some years since, and which I have, heretofore, shown to the Society, patients usually have no trouble in inserting the cotton discs themselves; but, when they can be worn for some days, and the perforation shows a disposition to close under their influence, I prefer to insert them myself, as it is, under such circumstances, of more importance that they should be accurately placed, and especially that they should not be pushed through the perforation. The shape of the artificial drum, especially if it is used with the hope of promoting the healing of the perforation, is, I think, also a matter of some importance. The shape which I have come to prefer resembles, before the vaseline is applied to it, a very small torpedo, such as children use. It is made by taking a bit of absorbent cotton, in which the fibres run mostly in one direction, doubling it over upon itself so that the ends will come together, and then with a twirling motion twisting these between the thumb and finger into a stem. To this stem, close up to the point at which it expands into the little sphere of cotton, a piece of waxed sewing silk (waxed to prevent it from slipping) is attached by means of a running knot, and then the stem and one end of the thread are cut off short. After the vaseline has been applied to the cotton it becomes flattened into a nearly round disc, of about uniform thickness, with the thread attached to its centre. If its shape or size is not just what we desire, we may now trim off the edge with scissors.

If suppuration be present in an ear in which the employment of an artificial drum seems to be indicated, or if it should occur while it is being worn, the ear should be syringed once or twice a day, or less frequently, as may be found necessary, with a fifteen grain solution of

boracic acid, until the suppurative process is arrested. My reasons for preferring to use boracic acid in solution rather than in powder, especially under the circumstances described, have been brought to the attention of the Society heretofore, and I may add that further experience has only served to convince me that they were well-founded.

A brief description of a case of chronic otorrhœa, with a perforation of years' standing, in which the treatment I have described was recently employed, will best illustrate what it is capable of accomplishing: Mr. W., 18 years of age, had had an otorrhœa upon the left side since childhood. Just back of the malleus handle there was a pyriform perforation, the longest (nearly vertical) diameter of which was somewhat less than half that of the tympanal membrane. At the time the case came under observation (Oct. 28, 1889), the discharge was not profuse, but the ear contained a quantity of pus and scabs. A single instillation of a saturated solution of boracic acid, after the ear had been carefully cleansed by syringing with warm water, completely checked the suppurative process, and left the ear in a condition which seemed to invite efforts to induce the healing of the perforation. The patient was, therefore, placed upon a tonic treatment (syr. hypophos. compos. cum quinia et strychnia), as his system seemed to need building up, and local measures designed to promote the closure of the perforation were employed. The patient was persistent and regular in his attendance, and various were the expedients, which, with this end in view, were resorted to during the ensuing fourteen months. Several times during this period suppuration recurred in the ear, but was always promptly arrested by one or more applications of the saturated boracic acid solution, and more than once the perforation diminished so considerably in size as to lead me to suppose that my efforts

were about to prove successful. The application of Dr. Blake's paper discs was the first expedient employed, but after two months' trial without appreciable effect they were laid aside, and in place of them a pledget of borated cotton, moistened at the time of its insertion with a solution of boracic acid, was placed over the perforation, in contact with the membrane. Nothing was accomplished by this expedient, however, and no better success followed the use in a similar manner of a pledget of dry borated cotton and of a disc of thin animal membrane (gut). The meatus was then simply closed with a plug of cotton and the membrane left severely alone, and subsequently this plan was modified by the application of vaseline to the edges of the perforation and the surrounding membrane, but still with only slight effect as regards diminution in the size of the perforation.

I now resorted to the measure to which I have already referred, — the application of nitrate of silver (fused upon the tip of a probe) to a zone of the tympanal membrane surrounding the perforation. The first application, which caused no pain, was followed by slight inflammatory reaction and the appearance, two days later, of a discharge from the ear, which lasted, however, only forty-eight hours. During the next three weeks the ear remained free from suppuration, and nothing was done except to keep it closed with a plug of borated cotton. At the expiration of this period, the perforation, which had been rapidly growing smaller, was scarcely larger than a pin's head, and I confidently expected to find it completely closed at the patient's next visit, which was to be at the end of two weeks. To my chagrin, I found it not closed, as I had hoped, but considerably larger, and, after making several subsequent applications of the silver without observing any decided change for the better in the condition of the membrane, I finally laid aside this method of treatment.

It now occurred to me to try the effect upon the perforation of a cotton artificial drum-membrane anointed with vaseline. The first one was introduced on Dec. 18, 1890. At this time the perforation was about 2 mm. in its longest, by 1 mm. in its shortest diameter. The patient was told to report in a week, but was not seen for eleven days. At the expiration of this time the cotton disc was found to be still in good position, and upon removing it the perforation was discovered to be "decidedly smaller," its edge hyperæmic, and the parts clean and free from discharge. Not to prolong unnecessarily the further history of the case, I may state briefly that after two months' wearing of the artificial drums, prepared in the manner I have described, during which period six of them were inserted at intervals varying from one to two weeks, the perforation finally healed up completely. As a precaution, the artificial drum was worn for a further period of two weeks, when it was permanently laid aside. At this time, inflation of the drum by Valsalva's method moved out the membrane with a non-perforation sound, and with this ear the patient could distinguish words and understand questions in a whisper at 20′, with nearly normal acuteness. Within the past few days I have examined the ears again, finding the perforation still firmly healed and the hearing power of each about normal.

Nothing could have been more satisfactory than the action of the vaseline-cotton artificial drum-membrane in the case just described, but in other cases in which I afterwards employed it, its influence in promoting the healing of the perforation was not so evident, and it occurred to me that if I could add some agent to the vaseline which would impart to it a stimulant action, I might, by exciting a greater amount of activity in the circulation of the tympanal membrane, still further promote the healing process. Two agents, possessing antiseptic as well as

stimulant properties, suggested themselves as likely to accomplish this object — carbolic acid and balsam of Peru. Both have been tried, the former in strengths of half a grain and one grain to the drachm of vaseline, the latter in strengths of two, four, and eight drops to the drachm. Each has been well received by the ear, the balsam of Peru, however, seeming to produce the better effect, and at the present time I have two cases under observation in which I am using it. In each, I began with the weakest strength named and have increased to the greatest. In one case, that of a young man about twenty-two or twenty-three years of age, a perforation of long standing, situated in the posterior half of the tympanal membrane, and extending from its margin to the malleus handle, with a still greater extent vertically, has gradually diminished in size until it is now not more than half as large as it was when first seen, in January last. The carbolic acid was first tried, but since about the middle of June the balsam of Peru ointment has been used. The artificial drums are changed once a week. The membrane, which at the outset showed but little vitality, is now markedly hyperæmic, and the edges of the perforation so vascular that they bleed upon being wiped with absorbent cotton. There has not been from the beginning any suppuration in this case, but there is usually a little watery fluid found in the ear upon removal of the artificial drum, which I mop out with cotton before applying a new one. The progress in the healing process which is taking place in this case, leads me to believe that a closure of the perforation will be brought about at no very distant day.

In the other case, that of a lady about fifty-five years of age, almost absolutely deaf in the right ear from old otitis media, and having a recurrent otorrhœa, with nearly complete destruction of the drum-membrane in the other ear, the vaseline-cotton drums were used in the left ear, not,

at first, with any expectation that they would bring about a re-formation of the membrane, but because of the marked improvement which they produced in the hearing. Much to my surprise, however, a building up of the membrane soon began to be evident, the outgrowth being from the remnant of old membrane in the region of the annulus tympanicus and from the malleus handle, until, at the expiration of seven weeks from the first insertion of the artificial drum, only a comparatively small "U" shaped perforation, about the end of the malleus handle, was left. Unfortunately, about this time there appeared in the ear what seemed to be a fungus growth, probably aspergillus, and after this there occurred a gradual loss of the newly formed drum tissue. A severe cold taken subsequently caused a return of otorrhœa, which, as it proved obstinate, would have led me to omit the wearing of the artificial drum, except for the fact that the patient was so entirely dependent upon it for useful hearing. Boracic acid, nitrate of silver, and other local remedies were used, and the discharge was gradually brought under control, but in the mean time the perforation had grown very much larger. It was at this stage that I began to employ the balsam of Peru and vaseline, hoping that it would promote the growth of the membrane. In this respect, I regret to say, its effect has not been decided, but it has undoubtedly exerted a beneficial influence upon the suppurative process, which, without other treatment beyond a tonic regime and change of air, has been kept in check during the greater part of the summer. From the middle of July to the first of September the patient was away from the city, and during this period she introduced the artificial drums herself without difficulty and with great satisfaction as regards improvement in hearing. Usually she found it practicable to wear them for a week without having to introduce a fresh one. This case is still under observation

and, although the perforation is much larger than it was at one time, it is again diminishing appreciably in size, and I have not yet given up hope, in view of the remarkable behavior of the membrane soon after the treatment was begun, that I may yet have the good fortune to see it close.

As indicated in the title of this paper, I am not warranted in claiming that the experiments which I have tried have as yet been more than partially successful, but I hope in the near future to be able to present more convincing results, and I ask, therefore, that what I have here set forth be regarded as of the nature of a preliminary report.

DISCUSSION.

Dr. McKay: — About thirteen years ago I had a patient, a dentist, a very intelligent man, who had perforations of both drums; in one of the ears, about one-third of it destroyed, in the other almost entirely, excepting the peripheral margin. I treated him in a variety of ways, with Blake's syringe, etc., and, during the course of treatment, Dr. Roosa saw him and was reported to have said that the drum destroyed was useless to treat. I commenced the use of cotton drums. Shortly after he began using these he was able to do something he had not done for fifteen years: he attended meetings of the Dental Society and has been able ever since that time to engage in such work. In fact, he has been like a new man. The perforations have largely healed, the small one very little, the large one very much indeed, but neither quite completely. The patient is getting great comfort from these appliances, has improved in hearing, and is now wearing them, changing them once or twice a week or at longer intervals. The ear that seemed most hopeless is now doing service. I might say

that these drums were medicated with a weak carbolic solution.

Dr. Blake: — In reference to the paper of Dr. Theobald, and his criticism of the paper disc, I want to say that I have found it very necessary to refresh the edges of a perforation of the membrana tympani in order to get the healing effect. One objection which I found to the use of the cotton which Dr. McKay suggests is that the cotton makes, from its volume and elasticity, more pressure on the walls and on the edges of the perforation, and this seems in some cases to cause an enlargement of the perforation rather than the growth desired. The perforation would decrease in size for a time, and then, with a readjustment of the cotton, a possibly slight additional pressure has been sufficient to check the new growth.

Dr. Richey: — It has been my observation that, in these cases of perforation, the desirable thing, if we can only attain it, is something that will stimulate, excite action, without increasing suppuration. I thought a year or two ago I had found that in camphoric acid. It unquestionably acts in this direction to a certain extent; applying it upon the cotton pledget in the same way that you would apply the artificial "ear drum," and keeping it pressed closely, and yet not too heavily, against the drum-membrane, changing it every day or two. My first successes with nitrate of silver made me think that this would control the whole condition. Out of seven cases I got six exceedingly good results, with very marked improvement of hearing. Although my success has not been so great since, I still rely upon nitrate of silver, and think its effect in exciting this increased action in the tympanic membrane itself is most desirable. It has been my experience that the best results are to be obtained in cases with profuse granulation.

Dr. Jones: — In endeavoring to accomplish our object in these cases, it is important that the conditions with which we have to deal, as well as the end we seek to attain, should be kept clearly in mind. We find in these cases of perforation a rounded and cicatrizing edge. We endeavor to produce a similar condition when we incise a canaliculus, preparatory to probing a nasal duct. In a few days there is a similarly rounded edge, from union of the mucous lining of the canaliculus to the incised skin, and it is not expected that union of the incised parts will occur after they have remained open a few days, especially if there be no suppuration or ulceration to keep raw surfaces opposed to each other. We have to deal with analogous conditions in these cases of perforation. To start up such a fresh surface I have sometimes used chlor-acetic acid; and it served a good purpose, being decided in its action and readily controlled by being diluted with a stream of water, thus destroying its further caustic effect and preventing injury to surrounding tissue. It differs in this respect from nitric or chromic acid, if used for such purpose. If the wounded edge be removed, thus producing a fresh raw surface, granulation usually follows. This seems to be the indication for successful treatment of these troubles. Having secured a granulating surface, the prospect of closure of artificial openings in the drum-membrane is materially increased. How that can best be secured must be determined in each individual case. The circumstances attending the occurrence of the opening, and individual preferences of the physician, as well as of the patient, will do much to determine the mode of procedure in each case.

Dr. McKay: — As before stated, I kept my cotton medicated with carbolic acid solution.

Dr. Burnett: — I would like to ask Dr. Jones if he does not find that chlor-acetic acid causes intense pain.

Dr. Jones: — That is always the case, but it is readily controlled by diluting the acid with water, after the cauterizing, and the burning lasts only for a short time. It can be further modified by the use of cocaine prior to the operation.

AN UNUSUAL FORM OF DISLOCATION OF THE MALLEUS HANDLE.[1]

By Samuel Theobald, M. D., *Baltimore, Md.*

Dislocations of the malleus handle, more or less complete, are, of course, of very frequent occurrence, but I have not, heretofore, met with one at all resembling that which exists in the case I am about to describe. Except for this feature, the case is without interest. The patient, a lady, about forty years of age, was decidedly deaf in the right ear from chronic catarrh of the drum, and in the left ear as the result of old otitis media. The right ear presented nothing worthy of note. The left ear exhibited signs of having been at one time the seat of severe inflammation; the posterior half of the tympanal membrane had evidently been extensively destroyed, and, although the membrane had re-formed, the cicatricial portion was uneven, depressed, and probably more or less adherent to the inner wall of the tympanum.

The short process of the malleus was not discernible. The handle, which was completely severed from the body of the bone, was adherent to the tympanal membrane only at its tip and for a short distance above this point, while its upper two-thirds projected forwards and outwards into the auditory meatus, the free end lying nearly in contact with

[1] Read by title.

the anterior wall of the canal. The projecting portion, somewhat curved in form, was very white except at its free extremity, which was of a brownish color, the effect of this peculiar coloring being such as to suggest a resemblance to a diminutive stalk of asparagus. The accompanying drawing renders the description which I have given more intelligible.

As there was no active trouble in the ear, and as it did not appear that any benefit would result from the removal of the projecting bone, I concluded that it was best not to disturb it. The hearing in this ear, equal to words in a loud voice at 20′, improved but little under treatment, although the Eustachian tube was rendered freely pervious to air.

A CONCLUDING REPORT ON THE ANATOMY OF THE ELEPHANT'S EAR.

By Huntington Richards, M. D., *New York, N. Y.*

In a previous paper, discussing and attempting to illustrate and explain the anatomy of the elephant's ear, I deferred a more detailed account of the form, relations, and connections of the ossicles, and also fuller discussion of the labyrinthine structures, "until the issue of still another paper" (vide Transactions of the American Otological Society, Vol. 4, Part 4, p. 599). Circumstances unforeseen, and unexpected by me at the time of writing and presenting that earlier paper, have rendered it difficult for me to study those especial points, and at the very outset of this present report — the last that I purpose offering to the Society on this subject, and, therefore, a concluding report, as far as the writer is concerned — I must apologize for its almost total lack of additional information regarding these points.

The earlier dissection of the specimen, made by Dr. Buck in the preparation of his, the first report, necessarily opened the cavity of the vestibule and cut across two of the semicircular canals. The necessity for exposing these parts at that time arose from the fact that, owing to the narrowness of the tympanic vault and the thickness of its bony roof, it could not be seen without extensive removal of the pars petrosa (vide Dr. Buck's paper, Transactions, Vol. 4, Part 4, p. 586, at top). The vestibule, as now exposed in the specimen before me, is an irregular cup-

shaped cavity, six millimeters deep, and measuring across its mouth nine millimeters in an extero-internal and seven millimeters in an antero-posterior direction. At the entrances of the semicircular canals and at the entrance of the cochlear canals, the membranous structures are still present; elsewhere throughout its cavity they have been removed. The footplate of the stirrup, measuring about five by four millimeters, occupies most of its outer wall. The cochlea is still intact and lies unexamined within its bony envelope. I shall leave its proper investigation in the case of this specimen to some other observer. To him also I leave a more detailed discussion of the vestibule cavity and of the one intact and two mutilated semicircular canals.

To obtain a clearer view of the ossicles and their relations, and to facilitate search for the opening of the fenestra rotunda, I separated the specimen previously described by myself (article "A further report, etc."), into an outer and an inner fragment. This separation was effected by sawing through the anterior inferior wall of the Fallopian canal, thus opening into the back of the tympanic vault, and through the bony structures lying behind and below the tympanum, and then, — following the line of accidental separation of the thick membranous floor of the vault (see preceding paper, p. 603), — by divulsion, along the line of suture running between the periotic bone at the promontory and the squamosal bone. The outer fragment carried the membrana tympani, malleus, and incus; the inner retained the stirrup. This inner fragment was, by accidental divulsion, separated into a larger and a smaller portion, this second line of separation following the occipito-squamoso-periotic suture (vide Fig. 2 in my previous paper and its discussion, at top of page 595, and also Fig. 4 of the present paper) and the two lines of accidental fracture across the bone that intervened between this suture and the antrum

cavity and across the bony septum between this cavity and the Fallopian canal. This separation or divulsion exposed the cavity containing the body of the stapedius muscle,—that cavity lying between the upper part of the Fallopian canal and the antrum. The split through the bone which extended into this cavity is plainly visible in Fig. 2 of the former and in Fig. 4 of this present paper. The forcible divulsion of these three fragments, chiefly, as I recall it, that of the latter two, caused an accidental fracture of both crura stapedis, the footplate remaining firmly fixed in the fenestra ovalis, the crura and head remaining attached to the stapedius muscle. An interesting fact is demonstrated by this disruption of the specimen, viz., that there is in the elephant no complete bony division between the cavity containing the belly of the stapedius and the general cavity of the tympanum, an hiatus in the wall of the former, and one of considerable size, existing on its inner aspect, and consequently on the outer wall of the secondary tympanic cavity. This hiatus, this opening of communication (so far as true bony separation is concerned), lies behind the pars pyramidalis, quite outside of the tympanum proper and at a point in the outer wall of the secondary tympanic cavity, opposite to and on a level with the inner opening of a canal shown in Fig. 3 of the preceding paper and described (see top of page 603, in report for 1891) as that carrying a branch of the stylo-mastoid artery. Further description of the stapedius muscle I leave to the writer of a still further report upon this most interesting anatomical specimen. Of the fenestra rotunda I can discover no trace. A determination of the mooted question of its presence or absence in the elephant (see Dr. Buck's paper, footnote on pp. 582, 583) can, in my opinion be best obtained by dissection of the cochlea and careful tracing of the scala-tympani to its point of termination. The "hooded opening or niche," lying posterior to the

"analogue of the promontory," and therefore in the outer wall of the upper portion of the secondary tympanic cavity, which Dr. Buck suggested as being, but did not believe to be, the niche of the fenestra rotunda, is plainly shown by my further dissection to lie wholly above and behind the vestibule and, consequently, to be in close relation with the semicircular canals and far removed from the cochlea. This hooded niche lies in close relation, also, to the cavity containing the belly of the stapedius. It is the posterior end of a narrow groove, about 8 millimeters long, 2½ millimeters wide, and 2½ millimeters long, which extends in an antero-posterior direction along the back surface of the promontory of the pars petrosa, and which, at its forward end (wholly hidden from view until this final disruptive dissection of the specimen), is separated by membranous structures only from the cavity of the vestibule.

Before proceeding to comment upon the four illustrations presented in this, my own concluding paper, I will make bold to steal a little of the thunder of my successor in calling attention to a curious formation noticeable in the long process of the anvil. At least in the specimen before me, this process is not a solid shaft of bone; its lower (or, rather, posterior) half, where it curves inward for articulation with the head of the stapes, shows a tendency toward the tubular form, the inner wall of the tube or hollow cylinder being absent just above (or, rather, in front of) the articular tip, so that an oval opening with smooth rounded edges is presented at that point of its surface constituting an hiatus in the inner wall of the bony shaft. A like tendency is noticeable in the semi-cylindrical form of the crura stapedis, in apparent obedience to a general rule of formation observable in all the bone structure of the elephant's cranium, viz., such economy of solid bone tissue as to result in a maximum amount of strength and surface

and a minimum of weight. The prevailing feature of honey-comb or cancellar structure is throughout most singularly noticeable and characteristic.

The main object of this paper is the presentation of four illustrations, made by photo-engraving from photographs taken by myself, which I trust may serve as supplements to those already published in Dr. Buck's paper and in my own former paper. A detailed comment upon these new illustrations is unnecessary, hence I shall merely call attention to points shown in them better than they were shown in previously presented views of the specimens, and to things shown from a slightly different point of view, trusting that this new explanatory text and these new pictures may serve to give to such readers as will be at the pains to refer to former views and former explanations a more accurate notion of the peculiar features of the complicated anatomical specimen now so long under discussion.

Fig. 1. In this picture, the specimen is looked at from a point of view similar to, but not quite identical with that adopted in the case of Fig. 3 of my previous report. The top of the specimen is not seen in the illustration; its position is to the left of and beyond the margin of the engraving.

In Fig. 3 of the former paper, the top of the illustration corresponded with the upper end of the specimen; here, this is not the case but the bone is seen lying over to the left, on its forward and outer edge. I present this illustration in order to give a view of the curious drumstick-like osteophyte described by Dr. Buck (loc. cit., p. 579) which will do fuller justice to the subject than did the photograph made for Fig. 3 of his paper, and which will also show the margins of the neighboring crypts better than they were shown in Fig. 3 of my own former paper. The drumstick osteophyte is seen in the right-hand half of the present illustration, close to a copper wire which was bound around the specimen subsequent to the accident described

in the last paper. The crypt mouths lie behind (in the the illustration *above*) the central portion of the specimen. This central portion is the remaining part of the pars petrosa; in it (about three-quarters of an inch above the lower border of the illustration) is plainly to be seen the now exposed cavity of the vestibule. Almost coincident with the lower margin of the illustration may be seen a cross section of one of the semicircular canals. Any

Fig. 1.

careful reader of this paper and of either one or both of those which have preceded it, will at once recognize the large cavity seen towards the left-hand margin of this Fig. 1, as being the upper portion of the secondary or subsidiary tympanic cavity. In the specimen, the parts are about one-fifth larger than they are shown in the illustration.

Fig. 2. This third attempt to show the roof of the tympanum proper is here introduced as supplementary to Fig.

2 of Dr. Buck's paper and to Fig. 4 of my former paper. Be it remembered that in this view the observer is looking directly upwards in a vertical line to the membranous roof of the tympanum and sees the umbo of the membrana tympani projecting inwards like a tent and the handle of the malleus very much foreshortened. The smooth, rounded, lower surface of the pars petrosa, the promontory or analogue of the promontory, occupies the centre of the illustration. If the engraver succeeds in clearly reproducing the photograph, the course of the chorda tympani

FIG. 2.

nerve will be plainly seen to the left, and the mouths of several crypts opening into the subsidiary tympanum will be plainly seen to the right, of this promontory. To one of these crypt mouths, that one which shows most distinctly in the figure and which is triangular in outline, as there seen, I desire to call special attention. At the bottom of this crypt is situated the hiatus in the outer bone wall of the subsidiary tympanum, where membranous tissue alone intervenes between this cavity and that containing the belly of the stapedius muscle. In the illustration, the parts are shown a trifle larger than life size.

Fig. 3. This illustration, engraved from a photograph so taken as to magnify the object, shows about the same points discussed under the head of Fig. 1; but the parts are here seen many times as large as in nature. The point of view is slightly different from that chosen for Fig. 1, and the reader will observe that the wire, which in Fig. 1 crosses

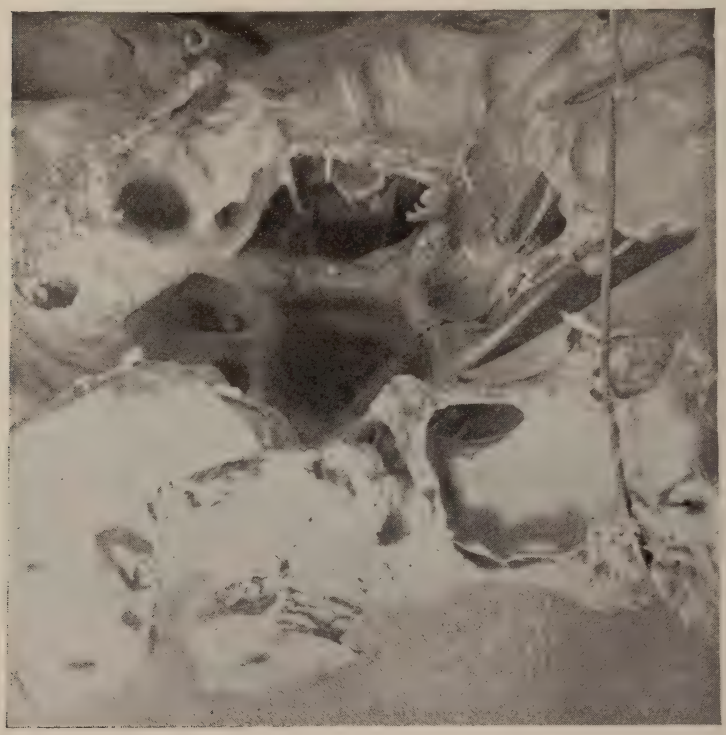

Fig. 3.

the picture above the shank of the drumstick osteophyte, here shows as crossing the knob-like extremity of that bony spur.

Fig. 4. In this illustration, the parts are again shown magnified to nearly twice their natural size. If the engraving succeeds in clearly reproducing the photograph, the

picture will give a good view of the hammer, anvil, and stirrup; of the tendon of the stapedius; of the antrum; of the sutures described in my former paper; and of the accidental bone crack leading from antrum to tympanum and (as explained in the early part of this present report)

FIG. 4.

opening to investigation the cavity holding the belly of the stapedius.

That this, my concluding report on the specimen under discussion, should have presented but little additional information to members of the Society, I sincerely regret. If, however, the latter part, containing the four new illustra-

tions, serve to make clearer what was attempted to be set forth in the two papers already given the Society by Dr. Buck and myself, and what all previous illustrations have, in the opinion of both writers, but imperfectly shown, I shall myself feel in some measure consoled for the shortcomings of its former part, and shall hope that members of the Society will feel that the paper, having subserved a useful purpose, has not been presented wholly in vain.

EXHIBITION OF INSTRUMENTS.

A NEW AURAL FORCEPS.

By E. D. Spear, M. D., *Boston, Mass.*

These combination forceps have been made to afford us instruments for use in the auditory canal and tympanum which may be both delicate and strong.

All operators have found the instruments usually offered for sale wanting in one or the other of these particulars. They have been too weak when made delicately or clumsy and unwieldy when strengthened.

The usefulness of any instrument can be decided at once when the trial is made of removing new growths or foreign bodies from within the auditory canal or tympanum. While there are many factors combining to increase or diminish the facility of their removal, such as a narrow or wide meatus, a sensitive or insentient surface, or other accidental condition, the depth of the objects within offers but little difficulty, because the arms of this instrument always remain parallel.

It happens when a small neoplasm is situated in the upper part (attic) of the tympanum or grows out into the auditory canal above the membrana propria, leaving the surrounding tissues normal in appearance and sensitiveness, that an otherwise tedious case may be shortened, and considerably so, by the painless removal of such growth

when seized and held by the ringed ends of the instrument, which need not be allowed to touch any other part of the ear.

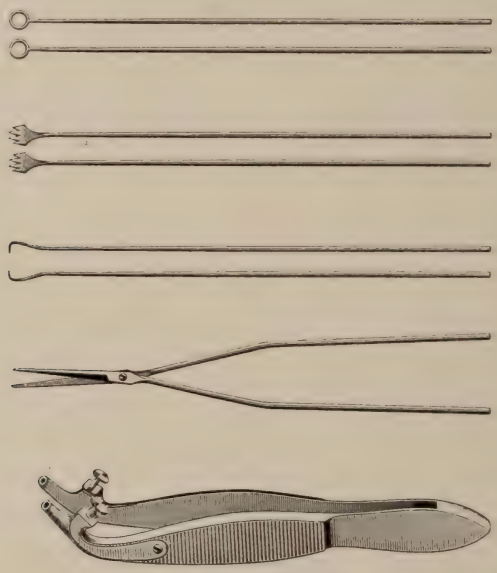

Codman & Shurtleff,
Boston.

The sharpened ends, which resemble sugar tongs, serve when the growths are tough, are useful for foreign bodies which have become impacted, and may also be used for dislodging masses of epidermis or epithelial collections. Hooks may be applied to similar uses.

Scissors, though rarely needed, can be attached to the handles for tenotomy of the stapedius tendon, and, if curved, may serve a similar purpose for adhesions.

A hook may sometimes be used with a ringed end and varying forms of tips may be added at the suggestion of individual operators.

ALPHABETICAL INDEX

OF

OTOLOGICAL LITERATURE, FROM JULY 1, 1890, TO JULY 1, 1891,

COMPILED BY

CLARENCE J. BLAKE, M. D., BOSTON, MASS.

Acal, M. Caso notable de enfermedad de oidos. Gac. méd. de Granada, 1890, IX. 329-333.

Albarracin, T. Mikrophotographien einiger für die Lehre von den Tonempfindungen wichtiger Theile des Ohres. Sitzungsb d. k. Akad. d. Wissensch. Math.-naturw. Cl. Wien. 1890, XCIX. 127–129. 2 pl.

Alberti, Franz. Ueber Schwindel als Symptom von Ohrkrankheit. Halle, a. S., 1890, C. A. Kaemmerer & Co. 20 p. 8°.

Allport, F. Necrosis of the malleus, incus, and stapes. Northwest Lancet, St. Paul, 1891, XI. 274 (Discussion); 282.

Anderson, W. An anatomical note upon the relation of the internal carotid artery to the inner wall of the tympanum. St. Thomas's Hosp. Rep. 1889–90, Lond. 1891, n. s. XIX. 243–245.

Andrews, J. A. Instruments for cleansing and applying medicated fluids and powder to the middle ear. Lancet, Lond. 1890, II. 1321.

Archivos internacionales de laringología, otología, rinología, y de las enfermedades de las primeras vias respiratorias y digestivas. Periódico bimestral. Redactado en español, francés é italiano. Fundado y publicado por el Dr. Ricardo Botey. No. 4, vol. I. Julio-Agosta, 1890, Par. 1890. 8°.

Aschendorf. Ein neues Hörrohr für Schwerhörige. Berl. Klin. Wchnschr. 1891, XXVIII. 416–418.

Ayres, S. C. Primary mastoid periostitis. Arch. Otol. N. Y. 1890, XIX. 95–98.

Ayers, H. Die Membrana tectoria, was sie ist; und die Membrana basilaris, was sie verrichtet. Anat. Anz. Jena. 1891, VI. 219.

Baker, C. H. A case of spurious membrana tympani. Med. Rec. N. Y. 1891, XXXIX. 623.

Bankovski. [Three cases of opening of mastoid process for an affection of the middle ear.] Russk. Med. St. Petersb. 1890, XVI. 279–281.

Baratoux, J. Hémorrhagies périodiques de l'oreille chez les hystériques. Rev. de laringol. etc. Par. 1890, X. 621–629.

Baratoux, J. Hémorrhagies périodiques de l'oreille chez les hystériques. Bull. et mém. Soc. de méd. prat. de Par. 1890, LXXXII. 1281–1288.

Barck, C. Contribution to affections of the petro-mastoid; a report of nineteen operative cases. Tr. M. Ass. Missouri, Excelsior Springs, 1890, XXXIII. 24–44.

Barclay, R. Abscess of brain from middle ear disease. St. Louis Cour. Med. 1890, III. 176–179.

Barclay, R. The use of the paper disc; case histories. Tr. Am. Otol. Soc. New Bedford, 1890, IV. pt. 4, 564–573.

Barclay, R. Abscess of the middle ear. St. Louis M. & S. J. 1891, LX. 18–20.

Barclay, R. Precepts of aural practice; with illustrative cases. Gaillard's M. J., N. Y. 1891, LII. 418–423.

Barclay, R. Abscess of the middle ear. Tr. M. Ass. Missouri, Excelsior Springs, 1890, XXXIII. 203–206.

Barclay, R. Dr. Blake's paper disk; case histories. Boston M. & S. J. Boston, 1890, CXXIII. 113.

Barr, T. Injurious effects of loud sounds on the hearing. Brit. M. J., Lond. 1890. II. 675.

Barrett, J. W. The treatment of chronic catarrh of the middle ear. Intercolon. M. Cong. Tr. Melbourne, 1889, II. 756–760.

Barrett, J. W. The value of redness in the handle of the malleus as a symptom in diseases of the middle ear. Ibid. 794–796.

Barrett, J. W. Abnormal patency of the Eustachian tube. Austral. M. J. Melbourne, 1891, n. s. XIII. 332.

Barth, A. Bericht über die 2. Versammlung norddeutscher Ohrenärzte am 7 April, 1890, zu Berlin. Ztschr. f. Ohrenh. Wiesb. 1890, XXI. 91–113.

Barth, A. Acute Mittelohrentzundung mit ungewöhnlichen cerebralen Erscheiuungen. Ibid. 87–90.

Barth, A. Two new instruments. 1. Palate retractor. 2. Retractors for keeping the soft parts separated during the operation of opening the mastoid process. Arch. Otol. N. Y. 1891, XX. 26–29.

Barth, A. A case of acute inflammation of the middle ear with unusual cerebral symptoms. Transl. by W. A. Holden. Arch. Otol. N. Y. 1891, XX. 116–119.

Bates, W. H. A case of deafness with absence of the drum-membrane: hearing restored by treatment. N. York M. J. 1891, LIII. 242.

Baumel, L. De l'otite chez l'enfant. Montpél. méd. 1891, 2. s. XVI. 399–407.

Baxter, W. E. A case of living larvæ in the ear. Arch. Otol. N. Y. 1891, XX. 11.

Baxter, W. E. The use of electricity in chronic affections of the middle ear. Arch. Otol. N. Y. 1891, XX. 207–211.

Bayer. Un cas de perte de connaissance consécutive à un traumatisme auriculaire; cessation des accidents immédiatement après le cathéterisme de la trompe d'Eustache avec l'insufflation d'air. Rev. de laryngol. etc. Par. 1890, X. 630–637.

Bayer. Un cas de perte de connaissance consécutive à un traumatisme auriculaire; cessation des accidents immédiatement après le cathéterisme de la trompe d'Eustache avec l'insufflation d'air. Presse méd. belge. Brux. 1890, 5. XLII. 671; 683; 702.

Behrens, B. M. Permanent opening of the drumhead and the artificial drumhead. Med. & Surg. Reporter, Phila. 1891, LXIV. 185–188.

Bell, T. Removal of pea after prolonged lodgement in the ear. Brit. M. J. Lond. 1891, I. 637.

Bezold, F. Cholesteatomy, perforation of Shrapnell's membrane, and occlusion of the tubes; an ætiological study. [Translated from the German.] Arch. Otol. N. Y. 1890, XIX. 232–254.

Bezold, F. Ueber das Cholesteatom des Mittelohres. Ztschr. f. Ohrenh. Wiesb. 1890-1, XXI. 252–271.

Bezold, W. von. Urteilstäuschungen nach Beseitigung einseitiger Harthörigkeit. Ztschr. f. Psychol & Physiol. d. Sinnesorg. Hamb. & Leipz. 1890, I. 486.

Bieljakoff, S. A. [Influence of diseases of ear on development and course of hallucinations.] Vestnik klin. i sudebnoi psichiat. i nevropatol. St. Petersb. 1891, VIII. no 2. 1–77.

Bing, A. Ueber Verletzungen des Trommelfelles. [Extr.] Internat. klin. Rundschau. Wien. 1890, IV. 742; 782.

Bing, A. Idiopathische acute Periostitis des äusseren Gehörganges. Wien. med. Bl. 1890, XIII. 579.

Bing, A. Zur Analyse des Weber'schen Versuches. Wien. Med. Presse, 1891, XXXII. 329–375.

Birmingham, A. Some practical considerations on the anatomy of the mastoid region, with guides for operating. Dublin J. M. Sc. 1891, XCI. 116–121, 2 pl. [Discussion] 166.

Birmingham, A. The mastoid region of the skull, with special reference to operations on the part. Tr. Roy. Acad. M. Ireland, Dubl. 1890, VIII. 225–250.

Bishop, S. S. Imperforate auditory canals. J. Am. M. Ass. Chicago, 1890, XV. 430.

Bishop, S. S. Atresia of the external auditory meatus. Times and Reg. N. Y. and Phila. 1890, XXI. 283.

Bistrzycki, A., und K. von Kostanecki. Das Gewicht menschlicher Gehörknöchelchen. Monatschr. f. Ohrenh. Berl. 1891, XXV. 65–68.

Blake, C. J. Reduplications of mucous membrane in the normal tympanic cavity; their clinical importance. Arch. Otol. N. Y. 1890, XIX. 209–216.

Blake, C. J. Otalgia. Boston M. & S. J. 1891, CXXV. 155–165; 173.

Blau, L. Bericht über die neueren Leistungen in der Ohrenheilkunde. Schmidt's Jahrb. Leipz. 1890, CCXXVI. 177; 253.

Boice, Emma L. Chronic suppuration of the middle ear. J. Ophth. Otol. & Laryngol. N. Y. 1891, III. 164–166.

Bolt, M. Drei Fälle von Otitis media acuta mit acuter Caries des Warzenfortsatzes nach Masern. Arch. f. Ohrenh. Leipz, 1891, XXXII. 25–28.

Bonnier, P. Le sens auriculaire de l'espace. Bull. scient. de la France et de la Belg. Par. 1891, XXIII. 1–54.

Bordoni-Uffreduzzi und Gradenigo. Ueber die Aetiologie der Otitis media. Centralbl. f. Bacteriol. u. Parasitenk. Jena. 1890, VII. 695–697.

Bordoni-Uffresluzzi, G., e G. Gradenigo. Sull'eziología dell'otite media. Arch. per le sc. med. Torino e Palermo, 1890, XIV. 263–283.

Botey, R. Instruments pour essais d'otoscopie intra-tympanique. Rev. de laryngol. etc. Par. 1890, X. 681–693.

Botey, R. Experimentos de avulsión del estribo en los animales. Siglo méd. Madrid, 1890, XXXVII. 631.

Botey, R. Expériences d'avulsion de l'étrier chez les animaux. Gaz. méd.-chir. de Toulouse, 1891, XXIII. 19; 28–37.

Boucheron, Surdités héréditaires; prévention: traitement; opération. Bull. Soc. méd. de l'Yonne, 1889. Auxerre, 1890, XXX. 17–21.

Breuer, J. Ueber die Function der Otolithen-Apparate. Arch. f. d. ges. Physiol. Bonn, 1890–1, XLVIII, 195–306. 3 pl.

Bronner, A. On the local use of menthol and oil of eucalyptus in affections of the middle ear. Arch. Otol. N. Y. 1891, XX. 73–75.

Brown, J. M. Persistent suppurative inflammation of the middle ear. Med. & Surg. Reporter, Phila. 1890, LXIII. 444–448.

Bryant, W. S. Observations on the topography of the normal human tympanum. Arch. Otol. N. Y. 1890, XIX. 217–231. 1 pl.

Buck, A. H. A revised description of the anatomy of the elephant's ear. Tr. Am. Otol. Soc. New Bedford, 1890, IV. pt. 4. 574–586.

Burkhardt, B. Bericht über die 10 Versammlung befreundeter süddeutscher und schweizerischer Ohrenärzte zu Nürnberg am 25 Mai, 1890. Ztscher. f. Ohrenh. Wiesb. 1890, XXI. 114–135.

Bürkner, K. Ueber die Statistik der Ohrenkrankheiten. Wien klin. Wchnschr. 1890, III. 751–753.

Bürkner, K. Elfter Bericht über die königl. Universitäts-Poliklinik für Ohrenkrankheiten. Nachr. v. d. k. Gesellsch. d. Wissensch. a. d. Georg-Aug. Univ. Götting. 1889, 286–289.

Bürkner, K. Ueber den Missbrauch des Politzer'schen Verfahrens bei der Behandlung von Ohrenkrankheiten. Berl. klin. Wchnschr. 1890, XXVII. 1013–1015.

Bürkner. Bericht über die im Etatsjahre 1889-90 in der Poliklinik für Ohrenkrankheiten zu Göttingen beobachteten Krankheitsfälle. Arch. f. Ohrenh. Leipz. 1890-1, XXXI. 293–298.

Bürkner, K. Das Aristol bei Ohren-und Nasenkrankheiten. Berl. klin. Wchnschr. 1891, XXVIII. 648.

Burnett, C. H. Permanently good results of excision of the membrana tympani and malleus in a case of chronic aural vertigo; also in a case of chronic suppuration of the tympanic attic. Med. News. Phila. 1890, LVII. 162–164.

Burnett, C. H. Idem. Tr. Am. Otol. Soc. New Bedford, 1890, IV. pt. 4, 609–615.

Burnett, C. H. On the relief of chronic catarrhal deafness by excision of the membrana tympani and the two larger ossicula. Med. News, Phila. 1891, LIX. 14.

Burnett, C. H. Permanently good results of excision of the malleus and membrana tympani in a case of chronic tinnitus and aural vertigo, and in a case of chronic suppuration of the attic due to necrosis of the malleus. Boston M. & S. J. 1890, CXXIII. 112.

Burnett, C. H. Excision of the membrana tympani, the malleus, and incus, as a means of treatment in otitis media catarrhalis chronica, and in otitis media purulenta chronica. J. Am. M. Ass. Chicago, 1891, XVII. 475–478.

Charpentier, A. Recherches sur l'intensité comparative des sons d'après leur tonalité. Arch. de physiol. norm. et pathol. Par. 1890, 5 s. II. 495–507.

Cheatham, W. The Delstanche instrument for massage in certain affections of the middle ear. Times & Reg. N. Y. & Phila. 1890, XXI. 220.

Cheval. Electro-acoumètre. Rev. de laryngol. etc. Par. 1891, XI. 424–428.

Cholewa. Progressive deafness (sclerosis) and its treatment by tenotomy of the tensor tympani. [Transl. by J. A. Spalding.] Arch. Otol. N. Y. 1890, XIX. 151–160.

Cleary, G. The treatment of chronic suppuration of the middle ear. Tr. Colorado M. Soc. Denver, 1890, XX. 72–82.

Colles, C. J. The treatment of chronic purulent otitis media by excision of the carious ossicles and removal of obstructions in the tympanic attic, with a report of three cases. Am. J. M. Sc. Phila. 1891, n. s. CI. 478–485.

Collier, M. Tapping the mastoid cells. Lancet, Lond. 1891, I. 480.

Combemale. Du vertige de Ménière. Bull. méd du nord. Lille, 1890, XXIX. 353–365.

Compaired, C. Tosse auriculaire? Boll d. mal. d. orecchio, d. gola e d. naso, Firenze, 1891, IX. 78–83.

Cooper, R. T. Osmic acid in ear cases. Hahneman month. Phila, 1890, XXV. 805–807.

Corradi, C. Observations sur les résultats de l'examen au diapason relativement aux maladies de la portion mastoïdienne du temporal. Rev. de laryngol. etc. Par. 1890. X. 337; 361.

Corradi, C. Influence de l'excitation électrique du nerf auditif sur la perception du diapason-vertex. Ibid. 568–571.

Corradi, C. Alcune osservazioni sui risultati dell'esame col diapason, specialmente riguardo alle malattie della porzione mastoide del temporale. Riv. veneta di sc. med. Venezia, 1890, XII. 465–497.

Corradi. Influence de l'excitation du nerf auditif sur la perception du diapason-vertex. Ann. de mal. de l'oreille, du larynx, etc. Par. 1890, XVI. 652–654.

Corradi, C. Zur Prüfung der Schallperception durch die Knochen. Arch. f. Ohrenh. Leipz. 1890, XXX. 175–182.

Corradi, C. Le malattie dell'orecchio in rapporto a quelle del naso ed all'éredità. Sordomuto, Milano-Roma, 1891, II. 355–358.

Corradi, C. Ueber die functionelle Wichtigkeit der Schnecke. Arch. f. Ohrenh. Leipz. 1891, XXXII. 1–14.

Couëtoux, L., Thomas, et L. Goguillot. De la surdité chez l'enfant et l'adulte au point de vue médical, pédagogique, légal, tutélaire. Par. 1890, G. Carré, 73 p. Portr. 8°.

Couëtoux, L. Essai d'une théorie des fonctions des sinus de la face, des cellules de l'éthmoïde, et de l'apophyx mastoïde. Ann. d. mal. de l'oreille, du larynx, etc. Par. 1891, XVII. 174–186.

Couëtoux, L. Note sur la migration des abscès tympaniques et sur son mécanisme. Ibid. 393.

Cousins, J. W. New aural probe, with some remarks on the treatment of chronic otorrhea and perforation of the membrana tympani. Med. Press & Circ. Lond. 1890, n. s. L. 57.

Cousins, J. W. The value of artificial drumheads. Ibid. 383.

Cozzolino, V. La chirurgia della mastoide e del cervello per le lesioni auricolari prodotte dall'influenza o aggravate da questa tossi-infezione. Boll. d. mal. d. orecchio, d. gola e d. naso, Firenze, 1890, VIII. 104–115.

Cozzolino. Le ferite dell'apparato uditivo prodotte da armi da fuoro. Boll. d. clin. Milano, 1890, VII. 193–199.

Cozzolino, Vincenzo. Igiene dell'orecchio in rapporto colla fisio-patologia della cavità nasali, del cavo nasofaringeo, ecc. 4. ed. Napoli, 1890, F. Cosmi, 80 p. 12°.

Cozzolino, Vincenzo. Hygiene des Ohres. Ins Deutsche übertragen von Emanuel Fink. Hamburg, 1891, 88 p. 24°.

Cozzolino, V. Resoconto statistico degli ammalati d'orecchio, naso e gola osservati negli anni scolastici 1887-88 e 1888-89, all'Ospedale clinico di Napoli nell'Ambulatorio. Gazz. med. d. Puglie. Bari. 1891, X. 193–209.

Crawford, G. R. J. Diffuse mastoid osteitis; trephining. Maritime M. News, Halifax, 1891, III. 33.

Crawford, G. R. J. Suppurative disease of the middle ear. Maritime M. News, Halifax, 1889-1890, II. 67.

Créguy. Note sur l'extraction des corps étrangers de l'oreille. Gaz. d. hôp Par. 1891, LXIV. 25.

Cuvillier, H. De l'emploi du salol camphré contre les suppurations de l'oreille. Ann. d. mal. de l'oreille, du larynx, etc. Par. 1890, XVI. 317–327.

Dabney, S. G. A case of "Ménière's disease." Med. News, Phila. 1891, LVIII. 229.

Dalbey, J. W. Impacted cerumen invading the mastoid process and producing facial paralysis. N. York M. J. 1891, LIV. 74.

Dalby, W. B. Bubble remedies in aural surgery. Lancet, Lond. 1891, I. 815–817.

Daly, W. H. A symposium of evidence concerning the relation of intra-nasal and ear disease. Pittsburgh M. Rev. 1890, IV. 370–375.

Dawson, B. F. Foreign body in the ear for nine years. Med. & Surg. Reporter, Phila. 1891, LXIV. 462.

Delie. Le salicylate de bismuth dans l'otorrhée. Rev. méd. Louvain, 1890, IX. 178–184.

Delogne. Écartement exagéré du pavillon de l'oreille. Clinique, Brux. 1891, V. 326.

Delstanche. Un cas d'exostose du conduit compliqué d'otorrhée. Presse méd belge. Brux. 1891, XLIII. 337.

Delstanche, C. Une observation d'audition colorée. Ann. d. mal. de l'oreille, du larynx, etc. Par. 1891, XVII. 394.

Dench, E. B. Operative measures for the relief of impaired hearing. Arch. Otol. N. Y. 1891, XX. 13–16.

Dench, E. B. Chronic non-suppurative inflammation of the middle ear; an analysis of cases of this disease treated at the New York eye and ear infirmary. N. Y. M. J. 1891, LIV. 337–341.

Discussion, A, on the etiology of tinnitus aurium. Brit. M. J. Lond. 1890, II. 667–672.

Dowd, C. N. Abscess of the temporo-sphenoidal lobe, secondary to otitis media. Med. Rec. N. Y. 1891, XXXIX. 183.

Dowling, F. Some practical remarks on the etiology and treatment of deafness. Cincinn. Lancet-Clinic, 1890, n. s. XXV. 185–188.

Draispul, E. Beitrag zur Lehre über die Formation des Hammer-Ambossgelenkes. Mitth. ü. d. embryol. Inst. d. k. k. Univ. Wien. 1890, 47–55. 1 pl.

Draispul, E. Ueber die Membrana propria des Trommelfelles. Ibid. 15–28. 1 pl.

Duplay. La surdité par bouchon cérumineux. Union méd. Par. 1890, 3. s. I. 73–77.

Duplay. Otite ostéo-périostique. Bull. méd. Par. 1890, IV. 797.

Edgeworth, F. H. The sequelæ of suppurative otitis media. Bristol M. Chir. J. 1890, VIII. 18; 87.

Egenolf, Eugen. Ueber die sog. Ménière'sche Krankheit. Bonn, 1890, Hauptmann, 32 p. 8°.

Eickler, O. Eine neue Methode zur Gewinnung von Corrosionspraeparaten des Ohrlabyrinths. Arch. f. Ohrenh. Leipz. 1890, XXX. 198-203.

Eitelberg, A. Chronische circumscripte Entzündung und Polyp des äusseren Gehörganges als Druckerscheinung in Folge eines Cerumenpfropfes. Wien. med. Presse. 1890, XXXI. 1534.

Eitelberg, A. Erkrankungen des Gehörorganes nach Nasenirrigationen und Nasenoperationen. Wien. med. Presse, 1891, XXXII. 901–904.

Ewald, R. Der Acusticusstamm ist durch Schall erregbar. Berl. Klin. Wchnschr. 1890, XXVII. 731.

Ewald, J. R. Die Abhängigkeit des galvanischen Schwindels vom innern Ohr. Centralbl. f. d. med. Wissensch. Berl. 1890, XXVIII. 753–755.

Ewald, J. R. Bedeutung des Ohres für die normalen Muskelcontractionen. Centralbl. f. Physiol. Leipz. u. Wien. 1891–2, V. 4–6.

Fano, G., und G. Masini. Beitrag zur Physiologie des innern Ohres. Centralbl. f. Physiol. Leipz. u. Wien. 1890–1, IV. 787.

Ferrand, Ét. L'oreille et le bruit, ou traumatisme de l'organe par vibrations violentes; moyen préventif à double effet conservant l'audition de la parole au milieu du bruit par lui atténué (hygiène professionelle et militaire). Lyons, 1890, F. Plan. 36 p. 8°.

Ferreri, G. La chiusura meccanïca della tromba nella cura caustica delle otite medie purulente croniche. Sperimentele, Firenze, 1890, LXV. 128–137.

Ferrier. A case of bilateral apoplectiform deafness. Lancet, Lond. 1891, I. 1094.

Ficano, G. A proposito di un caso di meningite consecutiva ad otite media suppurata cronica con produzione poliposa seguito da morte. Sierlia med. Palermo, 1890, II. 550–553.

Ficano, Giuseppe. Formulario ragionato delle malattie d'oreccio, naso, gola, laringe ed esofago. Palermo, 1891, C. Clansen, 131 p. 8°.

Ficano, G. Corpo estraneo della cassa del timpano. Boll. d. mal. d. orecchio, d. gola e d. naso, Firenze, 1891, IX. 1–3.

Fiske, G. F. The phonograph in testing hearing. J. Am. M. Ass. Chicago, 1890, XV. 854–856.

Fleming, G. Does Ménière disease occur in horses? Vet. J. & Ann. Comp. Path. Lond. 1891, XXXII. 393–398.

Fleming, G. Idem. J. Comp. M. & Vet. Arch. Phila. 1891, XII. 319–325.

Foster, M. L. Traumatic occlusion of the external auditory meatus. New York M. J. 1891, LIV. 70.

Foxwell, A. Removal of a pea after lodgement in the ear for five and one-half years. Brit. M. J. Lond. 1891, I. 459.

Freund, C. S., und R. Kayser. Ein Fall von Schreckneurose mit Gehörsanomalien. Deutsche med. Wchnschr. Leipz. 1891, XVII. 949–954.

Friedenwald, H. A case of extensive caries and cholesteatoma of the mastoid process without local signs of inflammation; death from thrombosis of the lateral sinus and meningitis. Arch. Otol. N. Y. 1891, XX. 1–10.

Froment. Hématomes de l'oreille. Gaz. méd. de Picardie. Amiens, 1890, VIII. 133–137.

Galin, M. A. [Cases of paralysis of facial nerve, dependent on cartarrh of middle ear; surgical treatment of tympanum.] Med. Obozr. Mosk. 1890, XXXIII. 1040–1049.

Gellé. Sur la comparaison des données et l'auscultation otoscopique du diapason-vertex et de son audition par le sujet, sous l'influence de la déglutition. Rev. de laryngol. etc. Par. 1890, X. 399–401.

Gellé. Séméiotique; signes tirés de la comparaison des résultats de l'audition et de l'auscultation du diapason-vertex pendant la déglutition et les divers autres modes de mobiliser l'appareil auriculaire. Ann. d. mal. de l'oreille, du larynx, etc. Par. 1890, XVI. 589–604.

Gellé. Otite et paralysie faciale. Tribune méd. Par. 1890, 2. s. XXII. 680–682.

Gellé. Audition et paralysie faciale; innervation des muscles tympaniques. Ann. d. mal. de l'oreille, du larynx, etc. Par. 1890, XVI. 760–766.

Gellé. Otite et paralysie faciale. Ibid. 729–760.

Gellé. De la lésion dans la surdité par les oreillons. Arch. internat. de laryngol. etc. Par. 1891, IV. 65–73.

Gomperz, B. Der Ohrschmerz und seine Behandlung. Centralbl. f. d. ges. Therap. Wien. 1890, VIII. 257–273.

Gomperz, B. Beiträge zur pathologischen Anatomie des Ohres. Arch. f. Ohrenh. Leipz. 1890, XXX. 216–229. 1 pl.

Goureau, T. Contribution à l'étude de la toux auriculaire; bouchon cérumineux ayant donné lieu au faux diagnostic de tuberculose pulmonaire. Actualité méd. Par. 1891, III. 113.

Gradenigo, G. Sulla eccitabilità elettrica del nervo acustico, e sul valore diagnostico di questa nelle malattie cerebrali e del sistema nervoso in generale. Boll. d. mal. d. orecchio, d. gola e d. naso, Firenze, 1890, VIII. 97-101.

Gradenigo, G., et R. Penzo. Observations bactériologiques sur le contenu de la caisse tympanique dans les cadavres de nouveau-nés et d'enfants à la mamelle. (Résumé.) Ann. d. mal. de l'oreille, du larynx, etc. Par. 1890, XVI, 555–558.

Gradenigo, G. Sull'eziologia e la cura dell'otite media acuta. Policlinico, Torino, 1890, I. 257–264.

Gradenigo, G. Contribution à l'étude morphologique de l'anthélix dans le pavillon humain. Ann. d. mal. de l'oreille, du larynx, etc. Par. 1890, XVI. 614–616.

Gradenigo, G. Les névrites de l'acoustique provenant de méningite. Ibid. 613.

Gradenigo, G. Ueber ein neues elektrisches Akumetermodell. Arch. f. Ohrenh. Leipz. 1890, XXX. 240–245.

Gradenigo, G. Ueber subjective Ohrengeräusche bei der Otitis interna. Allg. Wien. med. Ztg. 1890, XXXV. 423.

Gradenigo, G. Les microorganismes dans les affections de l'oreille moyenne et leurs complications. Ann. d. mal. de l'oreille, du larynx, etc. Par. 1890, XVI. 611.

Gradenigo, G. De l'étiologie et du traitement de l'otite moyenne aiguë. Rev. gen. de clin. et de thèrap. Par. 1890, IV. 793–796.

Gradenigo, G. Sui rumori subiettivi di orecchio. Rev. veneta di sc. med. Venezia, 1890, XIII. 114–133.

Gradenigo, G. Rendiconto statistico della sezzione otojatrica de policlino generale di Torino. Policlino, Torino, 1890, I. 493–501.

Gradenigo, G. Diagnostic, prognostic et thérapeutique de la surdité progressive dans l'otite moyenne chronique non purulente. Ann. de mal. de l'oreille, du larynx, etc. Par. 1890, XVI. 824–831.

Gradenigo, G. Beitrag zur Morphologie des Anthelix der menschlichen Ohrmuschel. Ztschr. f. Ohrenh. Wiesb. 1890–1, XXI. 289.

Gradenigo, G. Diagnose, Prognose und Therapie der progressiven Taubheit bei chronischer, nicht eitriger, Mittelohr-Entzündung. Ibid. 290–297.

Gradenigo, G. Die Mikroorganismen und die durch sie bewirkten Complicationen bei Erkrankungen des Mittelohres. Ibid. 297.

Gradenigo, G. A proposito di un nuovo modello di acumetro elettrico. Arch. internaz. di laringol. rinol. otol. etc. Napoli, 1890, VI. 129–132.

Gradenigo, G. Erster Bericht über die Abtheilung für Ohrenkrankheiten der allgemeinen Policlinic in Turin. (1889–1890.) Arch. f. Ohrenh. Leipz. 1891, XXXI. 273–286.

Gradenigo, G. Diagnosi, prognosi e terapia della sordità progressiva nell'otite media cronica non purulenta. Sordomuto, Milano-Roma, 1890–1, I. 358–415.

Gradenigo, G. Sulla classificazione e sulla etiologia delle otite medie in generale. Sperimentale, Firenze, 1891, LXVI. 173–181.

Gradenigo, G. Diagnosis, prognosis, and treatment of progressive deafness in chronic, not suppurative, inflammation of the middle ear. [Transl. by J. A. Spalding.] Arch. Otol. N. Y. 1891, XX. 221-227.

Gradenigo, G. Ueber die Classification und Aetiologie der Mittelohrentzündungen im Allgemeinen. Allg. Wien. med. Ztg. 1891, XXXVI. 331; 343.

Gradle, H. On the treatment of chronic suppuration of the middle ear. Med. News, Phila. 1891, LVIII. 397-399.

Gradle, H. Idem. Chicago M. Rec. 1891, I. 95-101.

Grady, M. E. The potash salts in the treatment of otitis. J. Ophth. Otol. & Laryngol. N. Y. 1890, II. 352-356.

Graham, H. Mucor corymbifer in the external auditory meatus. Lancet, Lond. 1890, II. 1379.

Grandhomme, Albert. Contribution à l'étude des suppurations des cellules mastoïdiennes (symptômes, diagnostic, traitement). Par. 1890, 83 p. 4°. No. 264.

Grazzi, V. Le malattie dell'orecchio nel feto e nella prima infancia e loro gravi consequenze sull'udito e sulla loquela. Boll. d. mal. d'orecchio, d. gola e d. naso, Firenze, 1890, VIII. 75–81.

Grazzi, V. Le malattie dell'orecchio nei feto e nella prima infanzia e loro gravi consequenze sull'udito e sulla loquela. Boll. d. mal. d. orecchio, d. gola e d. naso, Firenze, 1890, VIII. 134; 173; 1891, IX. 29.

Grazzi, Vittorio. Perche le malattie dell'orecchio sono tanto gravi nei bambini. Milano, 1890, F. Vallardi, 47 p. 16°.

Grazzi, V. Della sordità e delle sue cause principali. Morgagni, Milano, 1891, XXXIII. 313–324.

Green, J. O. Cases of meningitis from ear disease. Boston M. & S. J. 1890, CXXII. 643.

Green, J. O. The treatment of inflammation of the mastoid, with an analysis of eighty operations. Am. J. M. Sc. Phila. 1890, n. s. C. 575–586.

Green, J. O. Bony anchylosis of the malleus and incus. Boston M. & S. J. 1891, CXXIV. 11.

Green, J. O. Chrondroma of the ear. Ibid. 289.

Green, J. O. A case of abscess and softening of the brain with chronic disease of the tympanum. Ibid. 503; 513.

Green, W. E. Suppurative otitis media following an operation upon the septum. J. Ophth. Otol. & Laryngol. N. Y. 1891. III. 139.

Gronbech, A. C. Om kunstige Hjaelpemiddler för Tunghorige. [On artificial means for defective hearing.] Ugesk. f. Laeger, Kjobenh. 1891, 4 R. XXIII. 313; 335.

Grove, B. H. Hematoma auris. Buffalo M. & S. J. 1890–1, XXX. 205–211.

Gruber, Joseph. A text book on the diseases of the ear. Translated from the 2. German ed. by special permission of the author and edited by Edward Law, and by Coleman Jewell. N. Y. 1890, D. Appleton & Co. 604 p. 2 col. pl. 8°.

Gruber, J. Zur Behandlung der chronischen, eitrigen Mittelohrentzündung mit Durchlöcherung der Shrapnell'schen Membran. Allg. Wien. med. Ztg. 1891, XXXVI. 1; 13.

Gruber, J. Chronic purulent inflammation of the middle ear with perforation of the Sharpnell membrane. Med. Press & Circ. Lond. 1891, n. s. LI. 451–453.

Gruber, J. Operative Entferunng eines durch mislungene Extractionsversuche in die Trommelhöhle gerathenen Fremdkörpers. Monatschr. f. Ohrenh. Berl. 1891, XXV. 129–133.

Gruber, J. Fistula auris congenita. Aerztl. Ber. d. k. k. allg. Krankenh. zu Wien. (1889), 1891, 185.

Gruber, J. Misbildungen der Ohrmuschel. Ibid. 184.

Gruber, J. Othæmatoma auriculæ. Ibid. 184.

Grünwald. Zur Therapie der Gehörgangsfurunkel. München. med. Wchnschr. 1891, XXXVIII. 173.

Habermann, J. Ueber die Schwerhörigkeit der Kesselschmiede. Arch. f. Ohrenh. Leipz. 1890, XXX. 1–25.

Habermann, J. Hämorrhagien ins Labyrinth in Folge von perniciöser Anæmie. Prag. med. Wchnschr. 1890, XV. 483.

Hagan, H. Hæmatoma auris no evidence of insanity or of impending insanity. South. med. Rec. Atlanta, 1890, XX. 406–409.

Hammond, L. J. Stricture of the auditory canal, the result of a low-grade middle ear suppuration. Univ. M. Mag. Phila. 1890-1, III. 758.

Hartmann, Arthur. Die Freilegung des Kuppelraumes. Die anatomischen Verhâltnisse, welche bei der Aufmeisselung des Warzenfortsatzes bezûglith der Möglichkeit einer Verletzung des N. facialis und des Labyrinthes in Betracht kommen. Berl. 1891, H. Kornfeld, 8 p. 8°, 4 pl. 4°.

Hasbronck, S. Primary acute inflammation of the external mastoid region. J. Ophth. Otol. & Laryngol. N. Y. 1891, III. 121–125.

Haug, R. Ein Fall von Sarkom der Paukenhöhle und des Warzenfortsatzes. Arch. f. Ohrenh. Leipz. 1890, XXX. 126–132, 1 pl.

Haug, R. Ein einfaches Ohren.-Kehlkopf-Nasenphantom. Berl. kl. Wchnschr. 1891, XXVIII. 45.

Haug, R. Das Lysol und das Naphthol-(B.) in der Therapie der Ohrenkrankheiten. München. med. Wchnschr. 1891, XXXVIII. 199; 222.

Haug. Zur mikroskopischen Anatomie der Geschwülste des äusseren Ohres. Arch. f. Ohrenh. Leipz. 1891, XXXII. 151–170, 1 pl.

Haug. Schnupftabak als Ursache einer acuten Mittelohrentzündung. Ibid. 171.

Hecke, O. Bericht über die in meiner Poliklinik und Klinik für Ohrenkrankheiten zu Breslau im Jahre 1888 beobachteten Krankheitsfälle und ausgeführten Operationen. Ibid. 1890, XXXI. 66-75.

Hecke. Ueber Diagnose und operative Behandlung der Perlgeschwülste des Mittelohres. Jahresb. d. schles. Gesellsch. f. vaterl. Kult. 1889, Bresl. 1890, LXVII. 30–33.

Heiman, T. A case of operation for exostosis of the external auditory meatus. [Transl. by H. A. B. McCauley.] Arch. Otol. N. Y. 1890, XIX. 144–150.

Heiman, T. Przypadek zboczenia rozwojowego uszów. [Abnormal development of auditory canal.] Medycyna, Warszawa, 1890, XVIII. 449–453.

Heiman, T. A blow upon the ear followed by death in a week. Arch. Otol. N. Y. 1891, XX. 17–22.

Heiman, T. Ein Fall von mangelhafter Bildung beider Gehörorgane. Ztschr. f. Ohrenh. Wiesb. 1890–1, XXI. 271–277.

Heiman, T. Einiges zur Warzenfortsatz-Eröffnung. Ibid. 226–288.

Heiman, T. Some points concerning the opening of the mastoid process. Transl. by F. E. D'Oench. Arch. Otol. N. Y. 1891, XX. 132–141.

Hepburn, N. J. Report of a case of fracture of the malleus handle with luxation at the incudo-stapedial joint. Tr. Am. Otol. Soc. New Bedford, 1890, IV. pt 4. 605.

Hermann, L. Zur Theorie der Combinationstöne. Arch. f. d. ges. Physiol. Bonn, 1891, XLIX. 499–518.

Hermet. Sur quelques points de la dermatologie de l'oreille. Cong. internat. de dermatol. et de syph. C. r. 1889, Par. 1890, 734–738.

Hessler. Kann die Eröffnung des Warzenfortsatzes vom äusseren Gehörgang aus als gleichwerthig mit der sonst üblichen Methode betrachtet werden? Arch. f. Ohrenh. Leipz. 1890–1, XXXI. 59–65.

Hildebrandt. Ein zweiter Fall von Verletzung des Bulbus der Vena jugularis interna bei Paracentese des Trommelfells. Ibid. 1890, XXX. 183.

Hobz, F. E. A bug in the ear almost two years. Northwest. M. J. Minneap. 1890, XVIII. 83.

Holmes, G. A singular case of aural growth. Lancet, Lond. 1891, I. 657.

Howe, L. On the removal of a bullet from the ear with the assistance of the galvano-cautery. Tr. Am. Otol. Soc. New Bedford, 1890, IV. pt. 4. 553–559.

Howe, L. Idem. Boston M. & S. J. 1890, CXXIII. 111.

Huijsman, A. Behandeling van Otorrhoea. Nederl. Tijdschr. v. Geneesk. Amst. 1891, 2. R. XXVII. 591–593.

Iredell, C. L. M. Aural disease and epilepsy. Intercolon. M. Cong. Tr. Melbourne, 1889, II. 789–794.

Imbert. Sur l'acuité auditive. Gaz. hebd. d. sc. méd. de Montpel. 1890, XII. 529.

Jack, F. L. Injury to the ear from a piece of wood. Boston M. & S. J. 1891, CXXIV. 508; 513.

Jack, F. L. Adenoid growths in the nasopharynx, result of their removal in seventy cases of middle ear disease. Boston M. & S. J. 1890, CXXIII. 297; 301.

Jackson, G. H. Foreign body empacted in the membrana tympani. Abstr. Tr. Hunter. Soc. Lond. 1890–1, 106.

Jacobson, L. Zur Statistik der Ohrenkrankheiten. Arch. f. Ohrenh. Leipz. 1890-1, XXXI. 118–130.

Jänicke, M. Ueber die Borsäuretherapie der chronischen Ohreiterungen nebst Mittheilungen über ein neues Borpräparat. Ibid. 1891, XXXII. 15–24.

Jones, E. L. Suggestion on the use of electricity in ear diseases. J. Am. M. Ass. Chicago, 1890, XV. 48–50.

Jones, H. M. On the etiology of tinnitus aurium. Med. Press & Circ. Lond. 1890, n. s. L. 328–331.

Jones, H. M. A few remarks on inflation of the tympanum with special reference to the author's anti-insufflator. Ibid. 570.

Jones, M. The differential diagnosis and prognosis of tinnitus aurium (noises in the head and ears). Lancet, Lond. 1891, I. 1084–1086.

Jones, M. Idem. Prov. M. J. Leicester, 1891, X. 333–337.

Jones, H. Macnaughton. Subjective noises in the head and ears: their etiology, diagnosis, and treatment. Lond. 1891, Baillière, 160 p. 12°.

Jones, H. M. Idem. In: Wood's M. & S. Monog. 8°, N. Y. 1891, XI. 317–431.

Kanasugi, H. Klinische Beobachtungen über Eröffnung des Processus mastoideus. Verhandl. d. phys. med. Gesellsch. zu Würzb. 1891–2. n. F. XXV. 151–166.

Kanthack, A. A. Bacteriologische Untersuchungen der Entzündungsprocesse in der Paukenhöhle und dem Warzenfortsatze. Ztschr. f. Ohrenh. Wiesb. 1890, XXI. 44–52.

Katz, L. Knöcherne Ankylosis des Steigbügels (trockener Mittelohrcatarrh). Deutsche med. Wchnschr. Leipz. 1890, XVI. 889.

Katz, L. Histologisches über den Schneckenkanal, speciell die Stria vascularis. Arch. f. Ohrenh. Leipz. 1890-1, XXXI. 66–72.

Kayser, R. Bericht über die im Kalenderjahre 1890 in der Prof. Gottstein'schen Privatpoliklinik für Hals-, Nasen- und Ohrenkrankheiten behandelten Krankheitsfälle. Monatschr. f. Ohrenh. Berl. 1891, XXV. 161; 189.

Keen, W. W. Pyæmia and thrombosis of internal jugular vein from an old otitis media; ligation of internal jugular vein; trephining of mastoid opening of lateral sinus; death. Times & Reg. N. Y. & Phil. 1890, XXI. 559–561.

Kenny, A. L. A case of emphysema following some rupture of the Eustachian tube. Austral. M. J. Melbourne, 1891, n. s. XIII. 1–4.

Kessel. Ueber die vordere Tenotomie. Arch. f. Ohrenh. Leipz. 1890-1, XXXI. 131–143.

Kiesselbach. Stimmgabel und Stimmgabelversuche. Monatschr. f. Ohrenh. Berl. 1891, XXV. 1–7.

King, W. R. Otacoustic treatment as an adjunct to former methods of treating deafness. Hahneman Month. Phila. 1890, XXV. 443–448.

Kirchner. Ueber Paracentese des Trommelfelles. (Mit Demonstration.) Sitzungsb. d. phys. med. Gesellsch. zu Würzb. 1891, 38–40.

Klinckenström, A. Trois cas d'audition colorée dans la même famille. Biol. Fören. Forhandl. Verhandl. d. biol. Ver. in Stockholm, 1891, III, 117.

Klingel, C. Beitrag zur Histologie der Ohrpolypen. Ztschr. f. Ohrenh. Wiesb. 1890, XXI. 53–67.

Klingel, C. Messungen über die Höhenverhältnisse des Kuppelraumes der Trommelhöhle. Ibid. 1890–1, XXI. 193–196.

Klingel, C. Zwei Fälle von Talgdrüsenadenom am äusseren Ohre. Ibid. 189–192. 2 pl.

Klingel, C. A contribution to the histology of aural polypi. Transl. by C. A. Wood. Arch. Otol. N. Y. 1891, XX. 142–146.

Klingel, C. Measurements of the height of the cupola of the tympanum. Transl. by W. A. Holden. Ibid. 125–127.

Klingel, C. Two cases of adenoma of the sebaceous glands of the external ear. [Transl. by W. A. Holden.] Ibid. 193–196. 1 pl.

Köbel. Ueber kritiklose Pulverbehandlung bei Mittelohreiterungen. Med. Cor. Bl. d. würtemb. ärztl. Ver. Stuttg. 1890, LX. 201.

Köhler, R. Ein eigenthümlicher Fremdkörper im Ohr. Charité-Ann. Berl. 1890, XV. 518–521.

Körner, O. Schädelform und Topographie des Schädelbeins. Eine Entgegnung an Herrn Otto Schülzke. Arch f. Ohrenh. Leipz. 1890, XXX. 133–136.

Körner, O. Ueber die Fossa jugularis und die Knochenlücken im Boden der Paukenhöhle. Ibid. 236–239.

Krause, R. Entwicklungsgeschichte der häutigen Bogengänge. Arch. f. mikr. Anat. Bonn. 1890, XXXV. 287–304. 1 pl.

Kretschmann, F. Nachbehandlung des aufgemeisselten Warzenfortsatzes. Samml. Klin. Vortr. n. F. Leipz. 1890, No. 7. (Chir. No. 2, 35–44.)

Kuhn, A. Das Cholesteatom des Ohres. Ztschr. f. Ohrenh. Wiesb. 1890–1, XXI. 231–251. 2 pl.

Laborde y Winthuyssen, F. Cuerpos extraños en el conducto auditivo externo. Rev. méd. de Sevilla, 1891, XVI. 161; 203.

Lake, R. An unusual symptom in middle ear disease. Lancet, Lond. 1891, I. 1094.

Lake, R. Report of the aural department for the year 1889. St. Thomas's Hosp. Rep. 1889-90, Lond. 1891, n. s. XIX. 229–301. 1 pl.

Lane, W. A. The treatment of pyæmia consequent upon disease of the middle ear and unassociated with thrombosis of the lateral sinus. Brit. M. J. London, 1890, I. 1480.

Lannois. Surdité labyrinthique consécutive à la grippe. Rev. de laryngol. etc. Par. 1890, X. 561–567.

Lannois. De l'emploi du collodion dans le relâchement de la membrane du tympan. Ann. d. mal. de l'oreille, du larynx, etc. Par. 1891, XVII. 27–32.

Larsen, P. C., u. H. Mygind. Ein Fall von erworbener Taubstummheit mit Section. Arch. f. Ohrenh. Leipz. 1890, XXX. 188–197.

Larsen, P. C. Ein anatomisch-physiologischer Beitrag zur Lehre von den Ossicula auditus, anlässlich der H. Helmholtz'schen Arbeit: Die Mechanik der Gehörknöchelchen und des Trommelfells. Bonn, 1869. Anat. Anz. Jena. 1890, V. 604–607.

Larsen, P. C. Et anatomisk-fysiologisk Bidrag til Lären om ossicula auditus. I Anledning af H. Helmholtz's "Die Mechanik der Gehörknöchelchen und des Trommelfells, Bonn, 1869." Nord. med. Ark., Stockholm, 1890, XII. no. 16, 1–4.

Larsen-Utke. Thirteen cases of partial deafness with stricture of the Eustachian canal, treated with electrolysis. Ibid. Stockholm, 1891, n. F. I. pt. 3, 1–11.

Larsen-Utke. An anatomico-physiological contribution on the ossicula auditus. Lancet, Lond. 1891, II. 287.

Leudet, R. De l'otorrhagie dans la cirrhose hypertrophique. Ann. d. mal. de l'oreille, du larynx, etc. Par. 1890, XVI. 669–672.

Lewis, F. P. A peculiar inherited ear mark: fistula auris congenita. J. Ophth. Otol. & Laryngol. N. Y. 1891, III. 14–16.

Lindenberger, L. M. Pilocarpine as a remedy in middle and internal ear disease. Cincin. M. J. 1891, VI. 168–171.

Linnell, E. H. Boroglyceride in otitis media suppurative. J. Ophth. Otol. & Laryngol. N. Y. 1891, III. 133–135.

Lippincott, J. A. Mastoiditis interna purulenta following erysipelas. Med. News, Phila. 1890, LVII. 369.

Lippincott, J. A. Idem. Tr. Am. Otol. Soc. New Bedford, 1890, IV. pt. 4, 560–563.

Loeb, J. Ueber den Anteil des Hörnerven an den nach Gehirnverletzung auftretenden Zwangsbewegungen, Zwangslagen und assoziirten Stellungsänderungen der Bulbi und Extremitäten. Arch. f. d. ges. Physiol. Bonn, 1891-2, I. 66–83.

Löwe, L. Die desinfectorische Gehörgangstamponade. Monatschr. f. Ohrenh. Berl. 1890, XXIV, 161; 193, 225.

Lœwenberg. Beitrag zur Behandlung des sclerotischen Mittelohrleidens. Deutsche med. Wchnschr. Leipz. 1890, XVI. 611–613.

Lœwenberg. Der Einfluss des Geschlechts auf überwiegendes Erkranken des rechten oder linken Ohres. Ibid. 1119.

Lœwenberg. L'influence du sexe dans la latéralisation des affections auriculaires. Bull. méd. Par. 1890, IV. 727.

Luc. Contribution à l'étude des hémorrhagies névropathiques de l'oreille, sans perforation de la membrane tympanique. Arch. internat. de laryngol. etc. Par. 1891, IV. 14–22.

Luc. Idem. Par. 1891, G. Steinheil, 9 p. 8°.

Ludewig. Zur Ambosscaries und Ambossextraction. Arch. f. Ohrenh. Leipz. 1890, XXX. 263–276.

Ludewig. Bericht über die Thätigkeit der kgl. Universitäts-Ohrenklinik zu Halle a. S. vom 1. April 1889, bis 31. März 1890. Arch. f. Ohrenh. Leipz. 1890-1, XXXI. 31–58.

Lussano, F. I canali semicircolari e la malattia di Ménière. Gior. internaz. d. sc. med. Napoli, 1891, n. s. XIII. 281–311.

Maggiora, A., e G. Gradenigo. Osservazioni batteriologiche sul contenuto della tromba di Eustachio nelle otite medie catarrali croniche. Gior. d. r. Soc. ital. d'ig. Milano, 1890, XII. 442–449.

Maggiora, A., und G. Gradenigo. Bakteriologische Beobachtungen über den Inhalt der Eustachischen Trompete bei chronischen, katarrhalischen Mittelohrentzündungen. Centralbl. f. Bacteriol. u. Parasitenk. Jena. 1890, VIII. 582–589.

Maggiora, A., e G. Gradenigo. Contributo allo studio dell'eziologia delle otite catarrali. Gior. d. r. Accad. di med. di Torino, 1891, 3. s. XXXIX. 397–410.

Magro Alfonso, F. Sanguijela en el conducto auditivo derecho. Rev. de laryngol. otol. y rinol. Barcel. 1890–1, VI. 37–39.

Makins, G. H. Two cases of middle ear disease complicated by thrombosis and suppuration of the lateral sinus; with signs of pyæmia, successfully treated. Lancet, Lond. 1891, I. 1259.

Mandelstamm, B. Ein Fall von Fremdkörper in der Paukenhöhle. Ztschr. f. Ohrenh. Wiesb. 1890, XXI. 44–52.

Mandelstamm, B. A case of foreign body in the tympanum. Transl. by J. A. Spalding. Arch. Otol. N. Y. 1891, XX. 128–131.

Mansfield, A. D. Hydrogen peroxide in otorrhea. Med. & Surg. Reporter, Phila. 1891, LXIV. 463.

Marchei, E. Paralisi facciale destra da otite media suppurativa. Monitore med. marchigiano, Loreto, 1889–90, III. fasc. 11, 151.

Marian, A. Bericht über die in den Jahren 1887-1890 behandelten Ohrenkranken. Arch. f. Ohrenh. Leipz. 1891, XXXII. 101–112.

Martin, A. Otite moyenne double; paracentèse tympanique; trépanation des deux apophyses mastoides; guérison avec retour partiel de l'acuité auditive. Arch. de méd et pharm. mil. Par. 1891, XVII. 319–322.

Masini, G. Sulla cura di alcune varietà di sordità con la mobilizzazione della staffa. Boll. d. mal. d. orecceio, d. gola e d. naso, Firenze, 1890, VIII. 65–67.

Ménière. Contribution à l'étude des otites moyennes de la grippe. Statistique. Rev. de laryngol. etc. Par. 1890, X. 526–528.

Mettler, L. H. Aural vertigo (Ménière's disease?). J. Nerv. and Ment. Dis. N. Y. 1891, XVIII. 19 [Discussion]; 61.

Meyjes, W. P. Ein Fall von Zweitheilung im vordern Theil der mittlern Muschel. Monatschr. f. Ohrenh. Berl. 1891, XXV. 68.

Milligan, W. The treatment of granulations springing from the tympanic mucous membrane. Liverpool M. & Chir. J. 1891, XI. 55–59.

Milligan, W. On chronic suppurative disease of the middle ear: an analysis of 300 cases with some remarks upon treatment. Med. Chron. Manchester, 1891, XIV. 409, 412.

Miot, C. De la surdité déterminée par le tympan ou les osselets dans l'otite moyenne sèche, et des moyens d'y remédier. Rev. de laryngol. etc. Par. 1891. XI. 449–458.

Monks, G. H. Operations for correcting the deformity due to prominent ears. Boston M. & S. J. 1891, CXXIV. 84; 94.

Moos, S. Bezold's form of mastoid disease, and thrombosis of the lateral sinus. [Transl. by C. H. May.] Arch. Otol. N. Y. 1890, XIX. 161–167. 1 diag.

Moos, S. Histological and bacterial investigations of middle ear disease in the various types of diphtheria. Ibid. 1891, XX. 52–72. 8 pl.

Moos. Ueber die Beziehungen der Mikroorganismen zu den Mittelohrerkrankungen und deren Complicationen. Deutsche med. Wchnschr. Leipz. 1891, XVII. 432–435.

Moos. Ueber einige durch Bakterien-Einwanderung bedingte Veränderungen im menschlichen Gehörorgan, insbesondere im Labyrinth. Arch. f. path. Anat. etc. Berl. 1891, CXXIV. 546–561. 3 pl.

Moure, E. J. De l'enseignement des maladies des oreilles, du larynx et du nez en Allemagne. J. de méd. de Bordeaux, 1891-2, XXI. 6; 19; 29.

Müller, Alfred. Ueber einen Fall von Blutung aus der Vena jugularis bei Paracentese des Trommelfelles. Halle a S. 1890, C. A. Kaemmerer & Co. 25 p. 8°.

Müller, E. Zur Anatomie der Paukenhöhle. Med. Cor. Bl. d. würtemb. ärztl. Ver. Stuttg. 1890, LX. 233.

Müller. Einiges über die klinische Bedeutung bestimmter Trommelfellperforationen. Arch. f. Ohrenh. Leipz. 1891, XXXII. 85–100.

Mygind, H. Uebersicht über die pathologisch-anatomischen Veränderungen der Gehörorgane Taubstummer. Ibid. 1890, XXX. 76–118.

Mygind, H. Bidrag til Kendskabet til den hereds-syfilitiske Döved. c. r. Contribution à la connaissance de la surdité syphilitique héréditaire. Nord. med. Ark. Stockholm, 1890, XXII. No. 7, 1–27.

Nicolai, V. Statistica numerica degli ammalati curati nel primo quinquennio nella Sezione Rino-Laringojatrica della Poliambulanza di Milano, Bull. d. Poliamb. di Milano, 1890, III. 129. 4 tal.

Nimier, H. De l'action à distance sur les oreilles des projectiles en marche. Arch. de méd. et pharm. mil. Par. 1890, XVI. 143–149.

Noel. De l'action des détonations sur l'oreille. Bull. méd. Par. 1890, IV. 877–879.

Noltenius. Zwei Fälle von symmetrisch auftretenden Verknöcherungen der knorpeligen Gehörgangswand. Monatschr. f. Ohrenh. Berl. 1890, XXIV. 289–297.

Nouvelles considérations sur le vertige de Ménière et en particulier sur le mode de traitement de ce syndrome. [Edit.] Paris méd. 1890, XV. 209–212.

Ogston, A. The Cavendish lecture on unrecognized lesions of the labyrinth. Med. Press & Circ. Lond. 1890, n. s. XLIX. 625–632.

Ogston, A. Abstract of the Cavendish lecture on unrecognized lesions of the labyrinth. Lancet, Lond. 1890, II. 114–117.

Otitis media purulenta chronica dextra. Caries des Processus mastoideus. Pachymeningitis externa purulenta. Sinus thrombose (?). Trepanation. Heilung. Jahresb. ü. d. chir. Klin. d. Univ. Greifswald (1888–9), 1890, 9.

Otitis media chronica duplex. Caries processus mastoidei dupl. Periostitis capitis. Sinus thrombose. Trepanation. Tod. Ibid. 6.

Otitis media purulenta chronica dextra mit Polypenbildung. Caries des Processus mastoideus. Pachymeningitis purulenta externa. Trepanation. Heilung. Ibid. 9.

Ouspenskiĭ, M. Lupus de l'oreille moyenne. Ann. d. mal. de l'oreille, du larynx, etc. Par. 1891, XVII. 311–314.

Ouspenski, M. Syphilis de l'oreille. Ibid. 395–402.

Page, H. W. Two cases of middle ear disease in which operation was resorted to for the relief of cerebral complications. Lancet, London, 1891, II. 231.

Patteson, R. G. A contribution to the study of intra-cranial complications of chronic otitis media. Dublin J. M. Sc. 1890, XC. 1–22.

Perrelet, Louis. Recherches cliniques sur la réaction électrique de l'appareil auditif. Lyon, 1890, 52 p. 4°, No 563.

Phillips, S. L. Rupture of the membrana tympani by injection of warm water into the auditory canal for the removal of impacted cerumen. Atlanta M. & S. J. 1890-1, n. s. VII. 707–711.

Politzer, A. Procédés divers pouvant permettre d'établir le diagnostic de la perforation du tympan. Rev. de laryngol. etc. Par. 1890, X. 273–280.

Politzer, A. The employment of pilocarpine in certain affections of the ear, and the abuses of this remedy. Lancet, Lond. 1891, I. 10.

Politzer, A. Das Cholesteatom des Gehörorgans vom anatomischen und klinischen Standpunkte. Wien med. Wchnschr. 1891, XLI. 329; 377; 420; 475; 516.

Politzer, A. Du cholestéatome de l'oreille au point de vue anatomique et pathologique. Ann. d. mal. de l'oreille, du larynx, etc. Par. 1891, XVII. 245; 369.

Polo. Des contre-indications du cathétérisme de la trompe d'Eustache; nécessité de l'asepsie. Rev. de laryngol. etc. Par. 1890, X. 585–590.

Pomeroy, O. D. Four cases of mastoid cell disease cured by Wilde's incision and proper antiseptic treatment. Tr. Am. Otol. Soc. New Bedford, 1890, IV. pt. 4, 641–651.

Pomeroy, O. D. On some points in the pathogenesis of aural vertigo. N. York M. J. 1891, LIII. 716–719.

Pomeroy, O. D. Some cases of mastoid cell disease with a fistulous opening which recovered without the use of the drill or chisel. Boston M. & S. J. 1890, CXIII. 112.

Pomeroy, O. D. Some points on the pathogenesis of aural vertigo. Boston M. & S. J. 1891, CXXIV. 213.

Pritchard, U. Two cases of cerebral abscess resulting from longstanding otorrhea; operation; recovery. Arch. Otol. N. Y. 1890, XIX. 140–143.

Pritchard, U. Bony growths in the meatus and their removal. Ibid. 1891, XX. 45–51.

Pritchard, Urban. Handbook of diseases of the ear for the use of students and practitioners. 2 ed. Lond. 1891, H. K. Lewis, 254 p. 1 pl. 12°.

Quaife, W. F. Notes on blood tumour of the ear. Australas. M. Gaz. Sydney, 1890–1, X. 227–229.

Randall, B. A. Aural cholesteatoma. Univ. M. Mag. Phila. 1889–90, II. 526–529.

Randall, B. A. Cholesteatoma of the ear. J. Am. M. Ass. Chicago, 1890, XV. 350–352.

Randall, B. A. Suppuration of the tympanic attic and perforation in Shrapnell's membrane. Med. News, Phila. 1890, LVII. 305–310.

Randall, B. A. Caries of the wall of the auditory canal. Univ. M. Mag. Phila. 1890-1, III. 66–68.

Randall, B. A. Further notes on the Shrapnell perforation. Tr. Am. Otol. Soc. New Bedford, 1890, IV. pt. 4, 616–640. 1 pl.

Randall, B. A. The corrosion method in the study of the anatomy of the ear. Am. J. M. Sc. Phila. 1891, n. s. CI. 58–61.

Randall, B. A. The Shrapnell perforation. Boston M. & S. J. 1890, CXXIII. 112.

Rettig, A. Die "Tonbringer." Monatschr. f. Ohrenh. Berl. 1890, XXIV. 129; 167.

Richards, H. Work in the ear department of the Vanderbilt clinic. Med. Rec. N. Y. 1890, XXXVIII. 346.

Richards, H. A further report on the anatomy of the elephant's ear. Tr. Am. Otol. Soc. New Bedford, 1890, IV. pt. 4, 616–640. 1 pl.

Richards, H. Mastoid sclerosis as illustrated by a very typical and a fatal case. Ibid. 527–540.

Richards, H. Mastoid sclerosis as illustrated by a typical and fatal case. Boston M. & S. J. 1890, CXXIII. 110.

Richards, H. Implication of the mastoid cells of both ears in a case of chronic purulent otitis media; complete and rapid recovery following operation. N. York M. J. 1891, LIII. 68–70.

Richardson, C. W. The importance of surgical means applied to the naso-pharynx in the relief of naso-pharyngeal and middle ear catarrh. Times & Reg. N. Y. & Phila. 1890, XXI. 121–123.

Richardson, C. W. Idem. J. Am. M. Ass. Chicago, 1890. XV. 377–380.

Risk, E. J. E. Acquired syphilitic nerve deafness cured with pilocarpine. Brit. M. J. Lond. 1890, II. 86.

Ritchie, F. G. Two cases of fracture of the petrous portion of the temporal bone, with recovery. J. Ophth. Otol. & Laryngol. N. Y. 1890, II. 346–351.

Robertson, W. Eustachia synechiæ. Brit. M. J. Lond. 1891, I. 965.

Rohrer, F. Ueber die Anwendung des Pyoktanins (Merck) in der Ohrenheilkunde. Arch. f. Ohrenh. Leipz. 1890–1, XXXI. 144–153.

Rohrer, F. Lehrbuch der Ohrenheilkunde für Studirende und Aerzte. Leipz. und Wien. 1891, F. Denticke, 255 p. 1 tab. 8°.

Rounds, W. E. Chronic catarrh of the drum. J. Ophth. Otol. & Laryngol. N. Y. 1891, III. 189–197.

Rumler. Ueber Regeneration und Narbenbildung des Trommelfells. Arch. f. Ohrenh. Leipz. 1890, XXX. 142–157. 1 pl.

Sabrazès, J. Fistules congénitales symétriques du lobule des oreilles. J. de méd. d. Bordeaux, 1890–1, XX. 483.

Sainsbury, H., and W. H. Battle. Case of disease of the middle ear, in which symptoms suggesting cerebral abscess were completely relieved by treatment of the ear trouble. Tr. Clin. Soc. Lond. 1890, XXIII. 207–213.

Salzer, F. A. Zur operativen Behandlung der Sinusthrombose. Wien. Klin. Wchnschr. 1890, III. 651–655.

Sawtelle, H. W. Suppurative inflammation of mastoid cells of left ear; mastoid process opened; recovery. Rep. Superv. Surg.-Gen. Mar. Hosp. Wash. 1889–90, XVIII. 105.

Schaefer, K. L. Ueber die Wahrnehmung und Lokalisation von Schwebungen und Differenztönen. Ztschr. f. Physiol. d. Sinnesorg. Hamb. u. Leipz. 1890, I. 81–98.

Schaefer, K. L. Ein Versuch über die intrakranielle Leitung leisester Töne von Ohr zu Ohr. Ibid. 1891, II. 111–114.

Schanz, F. Wiederersatz einer verloren gegangenen Ohrmuschel. Cor. Bl. d. allg. ärztl. Ver. v. Thüringen, Weimar, 1890, XIX. 288–293.

Scheibe, A. Micro-organisms in acute middle ear suppuration. [Transl. by J. A. Spalding]. Arch. Otol. N. Y. 1890, XIX. 140–143.

Scheibe, A. Ueber eine neue Modification der Borsäurebehandlung bei chronischer Mittelohreiterung. München. med. Wchnschr. 1891. XXXVIII. 248–251.

Schenck, H. D. A case of otitis interna. J. Ophth. Otol. and Laryngol. N. Y. 1890, II. 315–322.

Schleicher, W. Aperçu sur les travaux de ma clinique de laryngologie et d'otologie, du 1er janvier, 1889 au 31 mars, 1890. Ann. d. mal. de l'oreille, du larynx, etc. Par. 1890, XVI. 443–453.

Schmiegelow, E. Ore, Naese, Svaelg-og Strube-Sygdomme. [Disorders of ear, nose, deglutition and throat.] Med. Aarsskr. Kjobenh. 1890, III, 227–298.

Schmiegelow, E. Beiträge zur Frage von den Perforationen in der Membrana flaccida Shrapnelli. Ztschr. f. Ohrenh. Wiesb. 1890-1, XXI. 197–230.

Schmiegelow, E. On the perforation of the membrana flaccida Shrapnelli, with remarks on the formation of cholesteatoma. [Transl. by W. A. Holden. Arch. Otol. N. Y. 1891, XX. 228–256.

Schmeider, B. J. [Ménière's disease.] Russk. Med. St. Petersb, 1891, XVII, 359–361.

Schubert, P. Bericht über das zweite ohrenärztliche Lustrum. Arch. f. Ohrenh. Leipz. 1890, XXX. 45–65.

Schülzke, O. Zur operativen. Eröffnung des Warzenfortsatzes. (Eine Erwiederung an Herrn Dr. Körner). Ibid. 137–141.

Schwabach und A. Magnus. Ueber Hörprüfung und einheitliche Bezeichnung der Hörfähigkeit. Ibid. 1890-1, XXXI. 81–117.

Schwartz, E. Ein neues Instrument zur Punktion der Oberkieferhöhle. Ztschr. f. Ohrenh. Wiesb. 1890–1, XII. 306–310.

Schwartz. [28 cases of fatal affections of ear with deductions as to treatment most convenient with enlisted men affected with otopathy.] Voyenno-med. J. St. Petersb. 1890, CLXIX. pt. 1, 99–137.

Schwartz. 28 Fälle tötlicher Ohrenerkrankungen nebst Folgerungen über die Behandlung und Dienstfähigkeit bei Ohrenleiden. Deutsche miil arztl. Ztschr. Berl. 1890, XIX. 535–572.

Schwendt, A. Ueber congenitale Missbildungen des Gehörorgans in Verbindung mit branchiogenen Cysten und Fisteln. Arch. f. Ohrenh. Leipz. 1891, XXXII. 37–52.

Secretan, L. L'oto-laryngologie et son importance pour le médecin practicien. Rev. méd. de la Suisse Rom. Genève, 1891, XI. 305–318.

Sexton, S. Removal of the drumhead and ossicles for chronic catarrh of the middle ear. Med. Rec. N. Y. 1890, XXXVIII. 584.

Sexton, S. Operation for the relief of deafness, noises in the head and ears, and vertigo, due to chronic catarrh of the drum of the ear. Arch. Otol. N. Y. 1891, XX. 95–107.

Shapleigh, J. B. Foreign bodies in the ear. Weekly M. Rev. St. Louis, 1890, XXII. 461–463.

Shield, M. A case of aural polypus accompanied with mastoid suppuration and threatening thrombosis of the lateral sinus; perforation of the mastoid cells; removal of the polypus; cure. Lancet, Lond. 1891, I. 307.

Shield, A. M. Abstract of a lecture on otorrhœa; its causes, consequences, and treatment. Ibid. II. 163–165.

Siebenmann, F. Erster Jahresbericht über die ohrenärztliche und rhinolaryngologische Poliklinik, 1. Januar bis 31. December 1889. Ztschr. f. Ohrenh. Wiesb. 1890, XXI. 68–77.

Siebenmann, F. A contribution on the question of the part taken by micro-organisms in otitis media diphteritica. [Transl. from the German.] Arch. Otol. N. Y. 1890, XIX. 293–297.

Siebenmann, F. Die Metallcorrosion. Arch f. Ohrenh. Leipz. 1890-1, XXXI. 287–292.

Simon, Emil. Beitrag zur Casuistik abscedirender Hirnentzündungen nach Otitis media purulenta chronica. Greifswald, 1890, J. Abel, 30 p. 8°.

Simon, P. De quelques complications cérébrales des otitis suppurées chez les enfants. Rev. méd. de l'est, Nancy, 1890, XXII, 373–378.

Sldziak, J. Kwas trojchloroctoroy (acidum trichloraceticum) w chorobach gardta, krtain, nosi i uszu. [.....in diseases of the pharynx, larynx, nose, and ear.] Gaz. lek. Warszawa, 1890, 2 s. X. 675; 692.

Smith, S. M. Employment of pilocarpine muriate in labyrinthine disease. Med. & Surg Reporter. Phila. 1891, LXV. 168–171.

Solari, B. T. Chancro sifilitico de la trompa de Eustaquio. An. d. Circ. méd. argent. Buenos Aires, 1890, XIII. 227–230.

Spalding, J. A. Foreign body remaining wedged in the external auditory meatus twenty-four years without injuring the hearing; removal with a hook and syringe. Arch. Otol. N. Y. 1891, XX. 218.

Spalding, J. A. On the use of benzoinol for moistening the cotton artificial membrana tympani. Ibid. 212–214.

Spalding, J. A. Eye and ear operations at the Maine General Hospital. Boston M. & S. J. 1891, CXXV. 39.

Spratling, W. P. Aural hallucinations cured by removal of foreign bodies from the ear. Med. Rec. N. Y. 1891, XXXIX. 680.

Stacke. Indikationen betreffend die Excision von Hammer und Ambos. Internat. Klin. Rundschau. Wien. 1890, IV. 2100–2102.

Stacke. Idem. Arch. f. Ohrenh. Leipz. 1890-1. XXXI. 201–215.

Steele, N. C. The importance of early treatment in middle ear disease. Atlanta M. & S. J. 1890-1, n. s. VII. 329–332.

Steinbrügge, H. Anatomical description of the left ear of a man who died of meningitis. [Transl. from the German.] Arch. Otol. N. Y. 1890, XIX. 270–279.

Steinbrügge, H. A rare case of auditory reflexes. Ibid. 1891, XX. 23–25.

Steinhoff, F. Beobachtungen über otitis externa crouposa. Arb. a. d. med.-klin. Inst. d. k. Ludwig-Maximilian Univ. zu München, Leipz. 1890, II. 138–161. 1 pl.

Steinthal. Ueber die operative Behandlung der Eiterung im Mittelohr und Warzenfortsatz. Med. Cor. Bl. d. würtemb. ärztl. Ver. Stuttg. 1890, LX. 179–183.

Stewart, T. M. Cutaneous closure of the external auditory canal; a case and operation. Pulte Quart. Cincin. 1890, I. 23.

Stocquart, A. Notes d'anatomie pathologique concernant l'appareil auditif. Arch. de. méd. et chir. prat. Brux. 1890, IV. 81–83.

Strauven, E. Cases of auricular disease treated by means of the constant current. [Transl. by Dr. W. F. Robinson.] Albany M. Ann. 1891, XII. 97–99.

Stumpf, C. Ueber Vergleichungen von Tondistanzen. Ztschr. f. Psychol. u. Physiol. d. Sinnesorg. Hamb. u. Leipz. 1890, I. 419–462.

Suarez de Mendoza, F. Sur le traitement de la sclérose de la caisse par la raréfaction et la condensation progressives, et manométriquement évaluées de l'air du conduit auditif externe. Rev. de laryngol. etc. Par. 1890, X. 493–498.

Suarez de Mendoza, Ferdinand. L'audition colorée; étude sur les fausses sensations secondaires physiologiques et particulièrement sur les pseudo-sensations de couleurs associées aux perceptions objectives des sens. Par. 1890, O. Doin, 164 p. 13 tab. 8°.

Suñé y Molist, L. Sordo-mudez adquirida en la primera infancia; consideraciones sobre su patogénia. Rev. de enferm. de la inf. Barcel. 1890, I. 3–8.

Suñé y Molist, L. Otitis media aguda, osteitis; sintomas graves; curación. Rev. de laringol. otol. y rinol. Barcel. 1890-1, VI. 143–146.

Suppurating inflammation of middle and external ear and mastoid cells; pleurisy; congestion of lungs. Rep. Superv. Surg.-Gen. Mar. Hosp. Wash. 1889-90, XVIII. 246–248.

Swain, H. L. Vesicles in the external auditory meatus. Arch. Otol. N. Y. 1891, XX. 197–206.

Szenes, S. Ueber den therapeutischen Werth einiger neuerer, in die ohrenärztliche Praxis eingeführter Heilmittel. Allg. Wien. med. Ztg. 1890, XXXV. 295.

Szenes, S. Idem. Therap. Monatschr. Berl. 1890, IV. 489; 540; 617.

Szenes, S. Zur chirurgischen Behandlung der acuten Paukenhöhlenentzündung. Centralbl. f. d. ges. Therap. Wien. 1891, IX. 257; 272.

Szenes, S. Zur Pathologie und Therapie der Fremdkröper im Ohre. Internat. Klin. kundschau, Wien. 1891, V. 869–871.

Szenes, S. Idem. Pest. med.-chir. Presse, Budapest, 1891, XXVII. 541–543.

Taylor, L. H. Cases and treatment of mastoid disease. Lehigh Valley M. Mag. Easton, Pa. 1890–1, II. 189–200.

Theobald, S. Report of a case in which a septum, closely resembling the tympanal membrane, formed in the middle third of the external auditory canal and was removed with improvement to hearing. Tr. Am. Otol. Soc. New Bedford, 1890, IV. pt. 4, 541–546.

Theobald, S. Idem. Boston M. & S. J. 1890, CXXIII. 111.

Thies. Zwei Fälle von Nekrose der Schnecke. Arch. f. Ohrenh. Leipz. 1890, XXX. 185–187.

Tillaux. Otite moyenne; nécrose et suppuration de l'apophyse mastoïde. Gaz. des hôp. Par. 1890, LXIII. 961.

Tilley, R. Four cases of disease of the mastoid. Med. News, Phila. 1890, LVII. 215–218.

Todd, C. A. Aneurism first recognized in the fundus of the ear, later appearing in the neck. Tr. Am. Otol. Soc. New Bedford, 1890, IV. pt. 4, 607.

Todd, C. A. Idem. Boston M. & S. J. 1890, CXXIII. 112.

Todd, C. A. Suppuration in the upper space (attic) of the tympanum. St. Louis Cour. Med. 1890, III. 275.

Treitel, L. Ruptures of the membrana tympani, with especial reference to their forensic importance. [Transl. by J. A. Spalding]. Arch. Otol. N. Y. 1890, XIX. 110–129.

Treitel, L. The affections of the ear in tabes dorsalis. [Transl. from the German.] Ibid. 280–292.

Trenberg, J. J. [Trephining of mastoid process in purulent inflammation of middle ear.] Med. pribav. k. morsk. sbornisku, St. Petersb. 1890, II. 367–372.

Trifiletti, A. Grave vertigine uditiva per prodotti colesteatomatosi della cassa; guarigione. Riv. clin. e terap. Napoli, 1891, XIII. 228–233.

Trifiletti, A. Otite media bilaterale; congestione meningo-encefalica; guarigione. Gazz. d. osp. Napoli, 1891, XII. 386–388.

Tschelzoff, M. M. [Styron in chronic purulent inflammation of the middle ear.] Bolnitsch. gaz. Botkina, St. Petersb. 1890, I. 409–415.

Turnbull, L. Catarrhal otitis media: aural catarrh. Virginia M. Month. Richmond, 1890–1, XVII. 617–623.

Turnbull, L. The great value of opening the Eustachian tube in diseases of head and ear. Med. News, Phila. 1891, LVIII. 492.

Turnbull, L. The treatment of tinnitus aurium. Ibid. LIX. 67.

Turnbull, L. Artificial drums. Ibid. 130.

Turnbull, L. A brief account of the etiology and treatment of tinnitus aurium. J. Am. M. Ass. Chicago, 1891, XVII. 479–482.

Turnbull, L. On the great importance of dry treatment in chronic otitis media. Med. & Surg. Reporter, Phila. 1891, LXV. 333.

Urbantschitsch, Victor. Lehrbuch der Ohrenheilkunde. 3 Aufl. Wien. & Leipz. 1890, Urban & Schwarzenberg, 528 p. 8 pl. 8°.

Uspenski, M. V. [On syphilis of the ear.] Med. Obozr. Mosk. 1891, XXXV. 768–773.

Vály, E. Zwei Fälle von Ohrmuschelkrebs. Pest. med.-chir. Presse, Budapest, 1890, XXVI. 1012.

Vaughan, J. C. Notes of a case of aural vertigo following an injury to the head. Indian M. Gaz. Calcutta, 1891, XXVI. 44.

Verdós, D. P. Un caso de emfisema general determinado por el cateterismo de la trompa de Eustaquio. Rev. de laryngol. otol. y rinol. Barcel, 1889–90, V. 149–151.

Volpe, A. Le massagio in talune modalità di otopatie, rinopatie e faringo-laringopatie. Arch. internaz. d. spec. med.-chir. Napoli, 1891, VII. 145–154.

Wahlstedt, J. C. Tvänne fall af "färghörsel" (audition colorée). Biol. Fören. Förhandl. Verhandl. d. biol. Ver. in Stockholm, 1890, II. 12–20.

Walker, G. S. Otorrhea, or inflammation of the meatus of the ear. Lancet, Lond. 1890, II. 919.

Watson, W. Spencer. Diseases of the nose and its accessory cavities, with special sections on diseases of the skin of the nose, on injuries, on rhinoplastic operations, and on ear affections in their relation to intranasal diseases, by Dr. Robert Liveing, Mr. William Adams, and Mr. A. E. Cumberbatch. 2d ed. Lond. 1890, H. K. Lewis, 328 p. 5 pl. 8°.

Welsch, D. E. The relationship of naso-pharyngeal disease and catarrh of the middle ear. Times & Reg. N. Y. and Phila. 1890, XXI. 522.

White, J. A. Importance of nasal surgery and nasal therapeutics in the treatment of aural catarrh. Virginia M. Month. Richmond, 1890–1, XVII. 717–723.

Wilson, A. The early treatment of mastoid disease. Edinb. M. J. 1890–1. XXXVI. 1017–1022.

Wolf, O. Words as tests of the hearing power and their differential diagnostic value. [Translated from the German.] Arch. Otol. N. Y. 1890, XIX. 298–304.

Wolf, O. Removal of a revolver bullet from the temporal bone by the use of the chisel: recovery with preservation of hearing. [Transl. by C. H. May.] Ibid. 1891, XX. 257-260.

Woods, H. Granular suppuration of the middle ear. Maryland M. J. 1890, XXIII. 215–218.

Würdemann, H. V. A contribution to the study of the complications of acute otitis media. Med. News, Phila. 1891, LVIII. 291.

Würdemann, H. V. Remarks on the treatment of proliferous inflammation of the middle ear. J. Am. M. Ass. Chicago, 1891, XVI, 547–551.

Zaufal. Zur Geschichte der operativen Behandlung der Sinusthrombose in Folge von Otitis media. Prag. med. Wchnschr. 1891, XVI. 28–31.

Zaufal, E. Zur operativen Behandlung der Fremdkörper in der Paukenhöhle, Wichtigkeit der ophthalmoscopischen Untersuchung. Prag. med. Wchnschr. 1891, XVI. 174–176.

Zaufal, E. Sur le traitement opératoire des corps étrangers de la cavité du tympan; importance de l'examen ophthalmoscopique. Ann. d. mal. de l'oreille, du larynx, etc. Par. 1891, XVII. 165–173.

Zaufal, E. Ueber die Bedeutung der Mikroorganismen zu den Mittelohrentzündungen und ihren Complicationen. Arch. f. Ohrenh. Leipz. 1890-1, XXXI. 177–200.

Zaufal. Ueber die Beziehungen der Mikroorganismen zu den Mittelohrerkrankungen und deren Komplikationen. Wien. med. Wchnschr. 1891, XLI. 1036; 1081; 1123; 1161.

Zwaardemaker, H. Een wet van ons gehoor (verlies der hoogste tonen van den toonladder met den leeftijd). Nederl. Tijdschr. v. Geneesk. Amst. 1890, 2. R. XXVI. 2. pt. 737–750. 1 pl.

Zwaardemaker, H. Der Verlust an hohen Tönen mit zunehmenden Alter; ein neues Gesetz. Arch. f. Ohrenh. Leipz. 1891, XXXII. 53–56.

TRANSACTIONS

OF THE

AMERICAN OTOLOGICAL SOCIETY,

TWENTY-FIFTH ANNUAL MEETING.

FORT GRISWOLD HOUSE, NEW LONDON, CONN.,

JULY 19, 1892.

VOL. V., PART 2.

PUBLISHED BY THE SOCIETY:
MERCURY PUBLISHING COMPANY, PRINTERS,
NEW BEDFORD, MASS.
1892.

Extra copies may be had by addressing the secretary, Dr. J. J. B. Vermyne, 2 Orchard street, New Bedford, Mass., or the Mercury Publishing Company, 112 and 114 Union street, New Bedford, Mass.

CONTENTS.

Members of the American Otological Society 183
Minutes of the Twenty-Fifth Annual Meeting 186
Cases of mastoid disease, exhibiting somewhat extensive carious processes. By Oren D. Pomeroy, M. D., New York, N. Y. 192
Mastoid cases. By Clarence J. Blake, M. D., Boston, Mass. . . 203
A case of chronic purulent otitis media; old pulmonary tuberculosis; opening of the mastoid; death from acute basilar meningitis; autopsy. By Herman Knapp, M. D., New York, N. Y. 205
Result of opening the mastoid in a case of chronic middle ear suppuration, with cerebral complications and septicæmic symptoms. Recovery. By T. Y. Sutphen, M. D., Newark, N. J. 210
A case of mastoid disease following an operation for the removal of adenoid vegetations. By Gorham Bacon, M. D., New York, N. Y. 213
A case of acute purulent inflammation of the middle ear, with double optic neuritis, but without tenderness or swelling of, or spontaneous pain in, the mastoid process, in which the opening of the mastoid cells was followed by a rapid subsidence of the optic neuritis and cure of the ear disease. By Charles J. Kipp, M. D., Newark, N. J. 216
A case of pyæmia, following acute suppurative otitis. Recovery. By J. B. Emerson, M. D., New York, N. Y. 221
The value of weak solutions of bichloride of mercury in the treatment of otitis media suppurativa. By Samuel Theobald, M. D., Baltimore, Md. 232
Preliminary notes on craniometric studies in relation to aural anatomy. By B. Alexander Randall, M. D., Philadelphia, Pa. 235
Discussion of preceding papers. 255
Wound of the lateral sinus during an operation upon the mastoid process, in a patient with phthisis pulmonalis. Septicæmia. Recovery. By D. B. St. John Roosa, M. D., LL. D., New York. 274

Discussion 281
Remarkable improvement in hearing by removal of the stapes. By Frederick L. Jack, M. D., Boston, Mass. 284
Middle ear operations. By Clarence J. Blake, M. D., Boston, Mass. 306
Discussion. 317
Excision of membrane and malleus for catarrhal deafness, followed by suppuration, mastoid empyema, and burrowing abscess of the neck. By B. Alexander Randall, M. D., Philadelphia, Pa. 325
Discussion. 330
A case of exostosis of the eternal auditory canal. Removal. Considerable improvement in the hearing power. By D. B. St. John Roosa, M. D., LL. D., New York. 331
Discussion. 334
Removal of the entire auricle and a part of the lobe by the bite of a horse. By E. E. Holt, M. D., Portland, Me. 340
Nomenclatura morborum auris et nomenclatura morborum nasi et naso-pharyngis. By E. D. Spear, M. D., Boston, Mass. 341
Notice—The Lenval Prize. 351
Alphabetical index of otological literature, from July 1, 1891, to July 31, 1892. Compiled by Gorham Bacon, M. D., New York, N. Y. 352

MEMBERS

OF THE

AMERICAN OTOLOGICAL SOCIETY.

Names of members deceased while in membership in italics.

HONORARY MEMBERS.

PROF. A. GRAHAM BELL, 1336 Nineteenth St., . . Washington, D. C.
Dr. E. H. Clarke.
PROF. ALFRED M. MAYER, Stevens Institute, . . . Hoboken, N. J.
PROF. OGDEN M. ROOD, . Columbia College, . . . New York, N. Y.
Dr. E. Williams.

ACTIVE MEMBERS.

DR. FRANK W. ABBOTT, . 223 Franklin St., ... Buffalo, N. Y.
Dr. C. R. Agnew.
DR. HARLAN P. ALLEN, . 73 East State St., . . . Columbus, O.
DR. A. ALT, ... 3036 Locust St., ... St. Louis, Mo.
DR. J. A. ANDREWS, . . . 9 West 22d St., ... New York, N. Y.
DR. S. C. AYRES, ... 64 West 7th St., ... Cincinnati, O.
DR. GORHAM BACON, . . 63 West 54th St., ... New York, N. Y.
DR. BENJAMIN J. BALDWIN, 13 South Perry St., . . Montgomery, Ala.
DR. ROBERT BARCLAY, . . 3211 Lucas Ave., ... St. Louis, Mo.
DR. EDWIN W. BARTLETT, 422 Jefferson St., . . . Milwaukee, Wis.
DR. CLARENCE J. BLAKE, 226 Marlborough St., . . Boston, Mass.
DR. R. O. BORN, ... 163 West 34th St., . . . New York, N. Y.
DR. ALBERT H. BUCK, . 19 East 38th St., ... New York, N. Y.
DR. CHARLES H. BURNETT, 127 South 18th St., . . . Philadelphia, Pa.
DR. FRANKLIN P. CAPRON, 203 Washington St., . . Providence, R. I.
DR. W. H. CARMALT, . . 87 Elm St., ... New Haven, Conn.
DR. J. ELLIOTT COLBURN, 808-812 Venetian Building, ... Chicago, Ill.
Dr. J. H. Dix.
Dr. E. Dyer.
Dr. E. P. Ely.
DR. J. B. EMERSON, . . . 20 East 30th St., ... New York, N. Y.

Dr. B. E. Fryer, U. S. A., S. W. cor. 9th and Cherry Sts., ... Kansas City, Mo.
Dr. John Green, ... 2670 Washington Ave., . St. Louis, Mo.
Dr. J. Orne Green, . . . 182 Marlborough St., . . Boston, Mass.
Dr. Emil Gruening, . . 109 East 23d St., ... New York, N. Y.
Dr. G. W. Hale, ... 235½ North Summer St., Nashville, Tenn.
Dr. George C. Harlan, . 1515 Walnut St., ... Philadelphia, Pa.
Dr. David Harrower, Jr., 9 Elm St., ... Worcester, Mass.
Dr. Neil J. Hepburn, . 369 West 23d St., . . . New York, N. Y.
Dr. Edward L. Holmes, 112 South Clark St., . . Chicago, Ill.
Dr. E. E. Holt, ... 723 Congress St., . . . Portland, Me.
Dr. Wm. H. Hotchkiss, . 3813 Washington Ave., . St. Louis, Mo.
Dr. Lucien Howe, . . . 183 Delaware Ave., . . Buffalo, N. Y.
Dr. Frederick L. Jack, 437 Boylston St., . . . Boston, Mass.
Dr. W. B. Johnson, . . . 170 Broadway, ... Paterson, N. J.
Dr. Samuel J. Jones, . . Montauk Bl., 115 Monroe St., Chicago, Ill.
Dr. Charles J. Kipp, . . 534 Broad St., ... Newark, N. J.
Dr. Herman Knapp, . . . 25 West 24th St., . . . New York, N. Y.
Dr. J. W. Lawton.
Dr. J. A. Lippincott, . . 435 Penn Ave., ... Pittsburg, Pa.
Dr. W. S. Little.
Dr. F. B. Loring, ... 1420 K St., North West, Washington, D. C.
Dr. C. J. Lundy, ... 27 Adams Ave., East, . Detroit, Mich.
Dr. Arthur Mathewson, 139 Montague St., . . . Brooklyn, N. Y.
Dr. Read J. McKay, . . N. E. cor. 9th and Market Sts., Wilmington, Del.
Dr. C. S. Merrill, . . . 23 Washington Ave., . . Albany, N. Y.
Dr. H. G. Miller, . . . 262 Benefit St., ... Providence, R. I.
Dr. B. L. Milliken, . . 278 Prospect St., ... Cleveland, O.
Dr. W. W. Morland.
Dr. H. L. Morse, ... 112 Marlborough St., . Boston, Mass.
Dr. Robert C. Myles, . 25 West 36th St., . . . New York, N. Y.
Dr. Henry D. Noyes, . . 233 Madison Ave., . . . New York, N. Y.
Dr. J. F. Noyes, Detroit, Mich.
Dr. Oren D. Pomeroy, . 316 Lexington Ave., . . New York, N. Y.
Dr. Thomas R. Pooley, . 107 Madison Ave., . . . New York, N. Y.
Dr. J. S. Prout, ... 26 Schermerhorn St., . . Brooklyn, N. Y.
Dr. B. Alexander Randall, 1806 Chestnut St., Philadelphia, Pa.
Dr. Wm. Rankin, Jr., . . 23 Cedar St., Newark, N. J.
Dr. J. M. Ray, ... 414 W. Chestnut St., . . Louisville, Ky.
Dr. R. A. Reeve, ... 22 Shuter St., cor. Victoria, Toronto, Canada.

Dr. Huntington Richards,	502 Youngerman Block,	Des Moines, Ia.
Dr. S. O. Richey,	732 Seventeenth St.,	Washington, D. C.
Dr. Charles E. Rider,	53 South Fitzhugh St.,	Rochester, N. Y.
Dr. Wheelock Rider,	53 South Fitzhugh St.,	Rochester, N. Y.
Dr. Frank W. Ring,	101 Park Ave.,	New York, N. Y.
Dr. S. D. Risley,	1722 Walnut St.,	Philadelphia, Pa.
Dr. D. B. St. John Roosa,	20 East 30th St.,	New York, N. Y.
Dr. John D. Rushmore,	129 Montague St.,	Brooklyn, N. Y.
Dr. Wm. W. Seely,	S. E. cor. 4th and Broadway,	Cincinnati, O.
Dr. Ralph W. Seiss,	213 South 17th St.,	Philadelphia, Pa.
Dr. Samuel Sexton,	12 West 35th St.,	New York, N. Y.
Dr. J. B. Shapleigh,	2608 Locust St.,	St. Louis, Mo.
Dr. Henry L. Shaw,	431 Boylston St.,	Boston, Mass.
Dr. E. D. Spear,	6 Beacon St.,	Boston, Mass.
Dr. H. N. Spencer,	2725 Washington Ave.,	St. Louis, Mo.
Dr. George T. Stevens,	33 West 33d St.,	New York, N. Y.
Dr. S. B. St. John,	43 Pratt St.,	Hartford, Conn.
Dr. George Strawbridge,	1500 Walnut St.,	Philadelphia, Pa.
Dr. T. Y. Sutphen,	999 Broad St.,	Newark, N. J.
Dr. J. O. Tansley,	28 West 43d St.,	New York, N. Y.
Dr. Samuel Theobald,	304 West Monument St.,	Baltimore, Md.
Dr. William Thomson,	1426 Walnut St.,	Philadelphia, Pa.
Dr. Robert Tilley,		Chicago, Ill.
Dr. J. Vanduyn,	111 South Salina St.,	Syracuse, N. Y.
Dr. J. J. B. Vermyne,	2 Orchard St.,	New Bedford, Mass.
Dr. David Webster,	266 Madison Ave.,	New York, N. Y.
Dr. F. M. Wilson,	317 State St.,	Bridgeport, Conn.

American Otological Society.

The Twenty-fifth Annual Meeting of the American Otological Society was held at the Fort Griswold House, New London, Conn., on Tuesday, July 19, 1892. The President, Dr. Gorham Bacon, of New York, N. Y., in the chair.

The Society was called to order at 9.30 A. M.

The following members were present.

Drs. J. A. Andrews,	New York, N. Y.
Gorham Bacon,	New York, N. Y.
Edwin W. Bartlett,	Milwaukee, Wis.
Clarence J. Blake,	Boston, Mass.
F. P. Capron,	Providence, R. I.
W. H. Carmalt,	New Haven, Conn.
J. B. Emerson,	New York, N. Y.
B. E. Fryer,	Kansas City, Mo.
John Green,	St. Louis, Mo.
J. Orne Green,	Boston, Mass.
E. E. Holt,	Portland, Me.
Lucien Howe,	Buffalo, N. Y.
Frederick L. Jack,	Boston, Mass.
Chas. J. Kipp,	Newark, N. J.
Herman Knapp,	New York, N. Y.
H. G. Miller,	Providence, R. I.
Robert C. Myles,	New York, N. Y.
H. D. Noyes,	New York, N. Y.
Oren D. Pomeroy,	New York, N. Y.
B. Alexander Randall,	Philadelphia, Pa.
Wm. Rankin, Jr.,	Newark, N. J.
R. A. Reeve,	Toronto, Canada.
Huntington Richards,	Des Moines, Ia.
S. O. Richey,	Washington, D. C.
Chas. E. Rider,	Rochester, N. Y.

Drs.	F. W. Ring,	New York, N. Y.
	D. B. St. John Roosa,	New York, N. Y.
	S. B. St. John,	Hartford, Conn.
	T. Y. Sutphen,	Newark, N. J.
	J. O. Tansley,	New York, N. Y.
	S. Theobald,	Baltimore, Md.
	J. J. B. Vermyne,	New Bedford, Mass.
	F. M. Wilson,	Bridgeport, Conn.

And by invitation:

Drs.	A. E. Adams,	Newburgh, N. Y.
	W. Bryant,	Boston, Mass.
	F. Buller,	Montreal, Canada.
	E. B. Dench,	New York, N. Y.
	J. Dickson,	Baltimore, Md.
	R. J. Howe,	New York, N. Y.
	S. F. McFarland,	Binghampton, N. Y.
	J. E. Nichols,	New York, N. Y.
	L. H. Taylor,	Wilkesbarre, Pa.

The President appointed as the Business Committee, Drs. John Green, H. G. Miller, and J. B. Emerson.

On account of absence of Drs. A. Mathewson and S. D. Risley, members of the Committee on Membership, Drs. C. J. Kipp and B. A. Randall were appointed on that Committee.

The Treasurer's Report was read and referred to Dr. J. A. Andrews as Auditing Committee. This Committee subsequently stated that the Treasurer's accounts were correct and properly vouched for, and the report was then accepted.

A pamphlet from Dr. E. D. Spear, of Boston, entitled "Nomenclatura Morborum Auris et Nomenclatura Morborum Nasi et Naso-Pharyngis, Boston, 1892," aiming at an uniform nomenclature, with endorsements of Drs. C. J. Blake and J. Orne Green, was referred to the Business Committee for report.

An invitation was extended to the guests of the Society

to take part in the discussions of the papers, which were then taken up in the following order:

1. Dr. O. D. Pomeroy. Some Cases of Mastoid Cell Disease, with rather Extensive Carious Processes. Read by abstract.

2. Dr. B. Alexander Randall. Preliminary Notes on Craniometric Studies in Relation to Aural Anatomy.

3. Dr. Charles J. Kipp. A Case of Purulent Inflammation of the Middle Ear, with Double Optic Neuritis, and Other Symptoms of Intracranial Disease, but Without Tenderness of the Mastoid Process, in which the Operation of Opening the Mastoid Cells was followed by Rapid Subsidence of the Optic Neuritis and Cure of the Ear Disease. Read by abstract.

4. Dr. Clarence J. Blake. On Mastoid Operations.

5. Dr. Herman Knapp. A Case of Chronic Purulent Otitis Media; Old Pulmonary Tuberculosis; Opening of the Mastoid; Death from Acute Basilar Meningitis; Autopsy.

6. Dr. J. B. Emerson. A Case of Pyæmia, following Acute Suppurative Otitis; Recovery.

7. Dr. T. Y. Sutphen. Mastoid Operation in a Case of Middle Ear Disease, with Septicæmic Symptoms and Cerebral Complications.

8. Dr. Gorham Bacon. A Case of Mastoid Disease, following an Operation for the Removal of Adenoid Vegetations. Read by abstract.

9. Dr. Samuel Theobald. The Value of Weak Solutions of Bichloride of Mercury, in the Treatment of Otitis Media Suppurativa.

10. Dr. Herman Knapp. Demonstration of a Specimen of a Bezold Perforation (on the medial side) of the Mastoid.

These papers were collectively discussed by Drs. Knapp, Blake, Wilson, Reeve, J. O. Green, Tansley,

Randall, Jack, Pomeroy, Richards, Fryer, Andrews, Dench, Nichols, Myles, Richey, and H. D. Noyes.

On motion of the Business Committee the Society at 12.30 P. M. adjourned to 2 P. M.

AFTERNOON SESSION.

The session was opened at 2 P. M. and the reading of papers was continued as follows:

11. Dr. D. B. St. John Roosa. Wound of the Lateral Sinus in a Mastoid Operation; Septicæmia; Recovery.

Discussed by Drs. Carmalt, Randall, and St. John.

12. Dr. Frederick L. Jack. Remarkable Improvement in Hearing by Removal of the Stapes.

13. Dr. Clarence J. Blake. On Middle Ear Operations.

The two last papers were discussed by Drs. Pomeroy, Roosa, Dench, Jack, Theobald, Rider, Blake, and Randall.

At 4.30 P. M. adjourned to 8 P. M.

EVENING SESSION.

The Society met for evening session at 8 P. M. The following papers were read:

14. Dr. B. Alexander Randall. Excision of the Membrane and Malleus, for Catarrhal Deafness, followed by Suppuration, Mastoid Empyema and Burrowing Abscess of the Neck.

Discussed by Dr. Roosa.

15. Dr. D. B. St. John Roosa. A case of Exostosis of the External Auditory Meatus.

Discussed by Drs. Blake, Reeve, Knapp, Pomeroy, Randall, Roosa, Howe, and Carmalt.

16. Dr. E. E. Holt. A Case of an Ear Bitten off by a Horse.

17. Dr. C. J. Blake. Exhibition of Plans of the New Aural Building of the Massachusetts Charitable Eye and Ear Infirmary.

All the papers read were referred to the Committee on Publications.

At 9.45 P. M. the Society went into Executive Session.

In the matter of Dr. Spear's pamphlet the Business Committee report that they wish to refer it back to the Society.

A motion of Dr. Roosa, discussed by Drs. H. D. Noyes, Carmalt, Andrews, and John Green, to publish the pamphlet in the Transactions of the Society and that two reprints be sent to each member was carried.

Dr. H. D. Noyes moves that a prefatory notice be published with the pamphlet, explaining that it is thus printed in order to bring it to the consideration of the members of the Society. Carried.

The Committee on Membership reported favorably on the names of

DRS. J. ELLIOTT COLBURN, of Chicago, Ill.
ROBERT TILLEY, of Chicago, Ill.
B. L. MILLIKEN, of Cleveland, Ohio.

who were duly elected on ballot.

The Business Committee reported the following list of officers for the ensuing year:

President:	DR. GORHAM BACON.
Vice President:	DR. HUNTINGTON RICHARDS.
Secretary and Treasurer:	DR. J. J. B. VERMYNE.
Committee on Membership:	DR. A. MATHEWSON. DR. S. THEOBALD. DR. S. B. ST. JOHN.
Committee on Publications:	DR. C. J. BLAKE. DR. J. ORNE GREEN. THE SECRETARY, EX OFFICIO.
Delegate to the Executive Committee of the Third Congress of American Phys. and Surg.:	DR. W. H. CARMALT.
Alternate:	DR. F. B. LORING.

The Committee further recommended that the next Annual Meeting of the Society be held on the day before the next Annual Meeting of the American Ophthalmological Society and at the same place.

A continuance of the publication in the Transactions of the Alphabetical Index of Otological Literature was voted on affirmatively by the Society, and on motion of Dr. B. A. Randall a vote of thanks was offered to its compilers.

The records of the Annual Meeting were then read and approved, and at 10.30 P. M. the Society adjourned.

J. J. B. VERMYNE, *Secretary*.

CASES OF MASTOID DISEASE, EXHIBITING SOMEWHAT EXTENSIVE CARIOUS PROCESSES.

By Oren D. Pomeroy, M. D., *New York, N. Y.*

Case I.—Jerry W., æt. 19. Has had a suppurative otitis media for four years. He came into the Hospital on Nov. 22d, 1887. In December, 1885, a post aural abscess was incised. Some months afterwards the mastoid was freely opened and carious bone removed. He was treated for several months subsequent to this. On entering the Hospital the mastoid opening was found to be nearly closed and the discharge came only from the tympanum through the meatus. A considerable swelling was also observed just below the auricle, which was red and painful, and prevented the patient from opening his mouth except very slightly. Pressure on the tumor discharged pus from the tympanum. Pulse rapid and weak, temperature $101\frac{2}{5}°$. The patient was emaciated and pale; bowels very much constipated; he was placed upon milk punch. On Nov. 24th the swelling was increased and extended to the face, while in the neck it was sufficient to interfere with swallowing. Under ether, the polypi in the meatus were removed by the curette, and the original opening in the mastoid was extended downwards fully two inches. On using the probe, a second opening was found below the first one, and the pus was completely evacuated by the aid of the syringe. The petrous portion of the temporal bone seemed to be diseased everywhere. At evening on the day of the operation the temperature was $103\frac{2}{5}°$. Bromide

of potass. was administered. Nov. 25th, temperature 99°. In the mouth on the left side in front of the velum, a swelling was noticed, which on being incised let free about a drachm of pus. There was apparently no communication with the external abscess cavity. During the day the temperature was about 101°, and the pulse 104. Nov. 27th, discharge from the mouth abscess very slight; temperature nearly normal, pulse 76, much better every way; 2 grains quinine ordered every three hours; continue nourishment and stimulants. For the next three days the temperature was slightly above normal.

Dec. 5th, very much better, temperature normal for several days. Discharge from the ear and from the mastoid much less; antiseptic irrigation practiced. The opening in the mastoid apparently filling up with normal tissue. Discharged.

I do not remember the precise reason for discharging the patient; it would appear that treatment should have been continued longer, but no further record appears. I believe the abscess in the mouth to be probably caused by the adjacent purulent collection in the mastoid and tympanum.

Case II.—Michael McG., æt. 34, applied for treatment Feb. 20th, 1890. On December last he had suppurative otitis of the left ear, which involved the mastoid region, for which a Wilde's incision was done. On entering the Hospital there was a carious opening into the mastoid, large enough to pass in the little finger, and extending three-quarters of an inch in depth. This was surrounded by carious bone. There was a very offensive discharge. There seemed to be pulsation in the bottom of the opening. The auditory canal was filled with dried epithelium and pus. He has rheumatism in his left hip joint, which causes some elevation of temperature. The mastoid was cleansed with

bichloride solution, 1 to 5000, and packed with iodoform gauze; large doses of iodide of potassium internally. During two weeks the temperature has been about $100\frac{2}{5}°$ in the evening and normal in the morning; suspected septicæmia. On March 7th I enlarged the mastoid opening and scraped away easily detachable carious bone with the bone curette and gouge. March 8th, temperature 103°; ordered whiskey and antifebrine. Temperature 102° at 12 M. and 103° at 5 P. M. Phenacetine in 15 gr. doses promptly reduced the temperature to $101\frac{1}{2}°$. During the next six days the temperature fluctuated from normal to 103°, and phenacetine in 10 to 15 grain doses seemed to be most successful in lowering it. Until March 20th the temperature has remained normal; stimulants and nourishment carefully looked after; discharge from mastoid profuse. The patient is much better and walks about the ward.

After March 20th he has persistent headaches and pachymeningitis is suspected. The carious bone looks very dark, and by passing the little finger deeply into the aperture a soft pulsating object is felt which was thought to be the meninx. Sequestra of carious bone were found and on March 7th, 1890, the following operation was done:

The original opening was enlarged downward about an inch. The upper part of the opening extended inwards about $1\frac{1}{4}$ inches, while below this the depth was only $\frac{3}{4}$ inch, the two openings being partially separated by a bridge of bone tissue, probably an effort at reparative action. This was cut away by the gouge and bone curette, and a number of small pieces of carious bone were removed. The syringe succeeded in washing out small bits of bone; granulations and cheesy material were also removed. At the level of the meatus, in the

bottom of the wound, soft tissue could be felt by thrusting in the little finger, which was regarded as granulations. The wound was irrigated with bichloride solution, 1 to 3000, and dressed with a 10 per cent. iodoform gauze. In this operation the chisel and drill were not serviceable.

On April 21, as the temperature had continued normal since the operation, and the patient in other respects was much improved, he was transferred to Bellevue Hospital.

Case III.—Thomas S., æt. 16, has otitis media suppurativa of both ears. On Aug. 11th, 1891, he came into the Hospital with acute suppurative otitis media of each ear. Six days afterwards a Wilde's incision was done on the left mastoid. The wound soon closed and the patient was relieved of urgent symptoms, but the discharge continued from each ear. He was then discharged.

On March 23d, 1892, he returned and came under my care for the first time. Over the left mastoid was a small aperture leading to a large carious cavity which readily communicated with the tympanum.

On March 23d, 1892, this opening was enlarged by a stout knife, sufficiently to allow the finger to be passed into the region of the mastoid cells. By means of the curette and gouge, considerable dead bone was removed, together with granulation material, and on syringing, a flocculent substance resembling broken down brain material, was removed in considerable quantities. This cavity seemed to include the drum cavity, and extended more than one inch inwards. Granulations in the drum cavity were also removed by the small curette. Considerable pus was removed by syringing.

Thorough antiseptic irrigation was practiced and the opening was loosely filled with cotton smeared with 1 part bichloride of mercury and 5000 of vaseline. During the next three weeks irrigation was practiced twice daily.

On examination at the end of that time, more granulations were found both in the tympanum and the mastoid. These were removed by the curette, and during the syringing minute particles of bone were removed. Things progressed very favorably until May 10th, 1892, when an abscess appeared above the meatus and opening into it. This was freely incised at a point above the auricle, and was found not to reach the bone. It was treated by antisepsis and a compressive pad of cotton to close the abscess cavity. At the present time, June 20th, the mastoid has closed, there are few granulations in the tympanum and the discharge has nearly ceased. The abscess above the ear is still discharging slightly, but on the whole this ear is nearly cured, *with hearing for rather loudly spoken words close to the ear*. The *right ear*, in the mean time, had filled with granulations, which were removed by forceps and curette; the discharge was purulent and excessive. On April 8th, by pressure over the right mastoid, pus escaped from the meatus and it was thought that the external table of the mastoid was perforated. A Wilde's incision was made but no breaking down of the parts was discovered; the wound was kept open by a tent, and antiseptic cleansing practiced. On May 9th the mastoid was found with a carious aperture and two or three masses of dead bone were removed by means of a stout pair of artery forceps. One of the bits of bone was a half inch in diameter. This left an enormous cavity surrounded by rough bone which included the drum cavity. Polyps were also removed from the tympanum. There was considerable hemorrhage. Antiseptic irrigation was practiced and the wound was covered with vaseline and bichloride on cotton. Since this date, the curette has been used to remove granulations from the tympanum, and small bits of carious bone from the mastoid.

At the present, June 20th, the external wound has

closed with considerable sinking of the parts. In the centre of the depression is an opening sufficient to introduce a No. 6 Bowman probe for a half inch. At the bottom, the probe touches a hard substance, but there is no discharge and no offensive odor. The ear no longer discharges more than to slightly moisten cotton on a probe. During the treatment the temperature has occasionally been slightly above the normal, and as the patient has been much emaciated, and with a strumous tendency, it looked at one time as though he might succumb. Stimulants were exhibited from the first, and the nutrition was carefully attended to. The right ear hears loudly spoken words at contact. It would seem by the description that a sufficiency of the essential parts of the ear had been so damaged as to abolish all useful hearing.

Case IV.—Anna W., æt. 2 years. In June of 1890, the patient had measles which resulted in a suppurative otitis media of the left ear, which recovered spontaneously after a few weeks. After two months the discharge reappeared and there was a swelling behind the ear. In November, 1890, I saw the patient for the first time, when there was suppurative otitis with polyps and a large carious opening in the mastoid, which was filled with granulations, small sequestra of carious bone, and cheesy looking detritus. The granulations were principally removed by the thumb nail, and the curette sufficed to remove the broken-down bone. Irrigation by means of the syringe was freely done, and the tympanum was cleared of granulations by the curette. The mastoid was dressed with bichloride gauze and bandage, with orders for daily antiseptic irrigation and reapplication of the dressing. Nov. 21st, 1891, about four days after the operation, there was very little discharge from the ear. Opening in the mastoid large and discharging freely; treatment continued,

but the attendance is irregular. After another month, granulations appeared about the mastoid opening and were removed as before, and some small particles of carious bone were removed by the curette. The subsequent notes of this case are meagre, but after three or four months the mastoid opening completely closed, of course with considerable depression over the mastoid region.

The notes are not clear as to how completely the discharge ceased from the tympanum, but it showed diminution in every instance after operation on the mastoid.

Case V.—James L., æt. 4 months, had a discharge from the left ear dating back a month, at first accompanied by pain. This suddenly ceased and a considerable swelling appeared over the mastoid region. I saw the patient after this had continued four or five days, and a Wilde's incision was at once made. The knife passed into the antrum, the external table being completely destroyed. A large amount of pus was evacuated; a probe could be passed in as far at least as the tympanum; there was considerable discharge from the tympanum. The after treatment was bichloride irrigation and dressing with bichloride gauze. After a few days a probe was easily passed one and a half inches in the direction of the tympanum, touching a bony bottom. It was impossible to tell the exact location of the termination of the fistula. A probe was frequently passed into the opening; it was somewhat enlarged by a drill and effort was made to perfect the drainage.

The patient came very irregularly and was not properly attended to at home, and in about two months he died with brain symptoms. There was no autopsy.

In analyzing this case, one is confronted with the proposition, Could more have been done to avert a fatal termi-

nation? It seems to me that all was done which was possible. It was impracticable to chisel out all the dead bone, as the danger of encroaching on brain or meninges was too great. The wonder is that so many of these cases escape a fatal termination.

Case VI.—Antonio P., an Italian, æt. 42, has a chronic suppurative otitis media in the right ear of three months' duration, accompanied by swelling in the mastoid region. A Wilde's incision was at once made, evacuating pus. An opening into the mastoid cells was found sufficiently large to pass the handle of a scalpel. A large portion of the mastoid cells was broken down, and a cavity lined with carious bone was found, readily communicating with the tympanum. There was no sequestrum found. From Feb. 29th to March 21st, 1892, the patient reported daily to the Hospital, and antiseptic irrigation was freely practiced.

On March 21st the temperature was $99\frac{3}{5}°$ and on 22d $100\frac{1}{5}°$. Some granulations in the mastoid aperture were removed by the thumb nail and curette, followed by a dressing of iodoform gauze. On the 23d the temperature was $100\frac{3}{5}°$, and the tissues about the auricle were much swollen and œdematous; wet bichloride dressing was used and a gum elastic drainage tube inserted into the mastoid opening. The patient was admitted to the Hospital and in two days was much better. The drum-membrane shows a small perforation, and the discharge from the ear is moderate. Daily antiseptic douching of the tympanum and the carious mastoid was practiced. March 29th, less discharge, temperature normal.

There was some pain in the side of the head, which was regarded as neuralgia, and 5 grains of quinine was ordered every four hours until relief was obtained. March 31st, pain relieved and quinine stopped; tempera-

ture normal. Opening in mastoid was $1\frac{1}{4}$ inches in depth. April 9th, complains of headache for the last two days and nights; relief from bromide of potassium and chloral. Some granulations in the bottom of the mastoid opening were removed by the curette, together with a few minute sequestra of bone; discharge free, both from tympanum and mastoid. April 18th, temperature $100\frac{5}{10}°$ and headache; next day no symptoms. Being disturbed by the action of the nurse, he suddenly made a murderous attack on him, with a pruning knife, inflicting several wounds upon the scalp. I had him sent with a note to the New York Insane Asylum, stating that I was uncertain as to whether the ear affection was the cause of the maniacal conduct or that it might be due to viciousness on the part of the patient. The doctor in charge of the asylum soon discharged him, believing him to be sane. I heard from the patient subsequently and found him about as before, with no urgent symptoms. In this case we will be likely enough to have brain abscess, meningitis, or thrombosis of some of the larger sinuses. The elevated temperature seems in this case to have had no serious significance.

Case VII.—Antonio P., an Italian, æt. 42, has a suppurative otitis of one month's duration. There was a swelling over the mastoid region, which had existed for two weeks, and which was very painful. A Wilde's incision was at once done, which resulted in the evacuation of pus. An aperture in the mastoid was found of sufficient size to pass in the handle of the scalpel to the distance of an inch and a quarter from the skin surface. An antiseptic poultice was applied and antiseptic irrigation practiced twice a day; also a hard rubber drainage tube was placed in the opening. After about four weeks of treatment the external wound was nearly closed, but some sequestra of bone were found and the temperature was $99\frac{3}{5}°$. There

was also some swelling of the soft parts much simulating cellulitis. It was accordingly decided to enlarge the opening and search for loosened particles of carious bone. By means of the bone curette several pieces of dead bone were removed, the wound irrigated and afterwards dressed with bichloride gauze, the whole covered with wet bichloride dressing. As a result of the operation the temperature became normal and all of the unpleasant symptoms disappeared. The subsequent history was not followed up.

In reviewing these cases, it is noticeable that no great effort was made to remove all of the dead bone. Any detached or easily detachable bit of carious bone was invariably removed. Antisepsis and adequate drainage were carefully looked after, and great pains were taken by means of nourishment, stimulants and tonics, to keep the vital energies in the best condition for reparative work, for on this depends mainly the success of our treatment.

It seems almost unaccountable that so few of these cases resulted fatally, when it is well known that any considerable amount of dead bone in proximity to the brain *may* set up a variety of brain disturbances sufficient to result fatally. In the event of carious processes in or near the roof of the tympanum or in the thin plate of bone separating the mastoid antrum from the brain, it seems to the writer that any special effort to remove carious bone would be too disastrous to be practicable. Numerous cases are on record, one of mine in the number, where most or all of the petrous pyramid was thrown off by natural processes, and the patient recovered. Would a fatal issue have been avoided if effort had been made to remove the dead bone, beyond the most gentle scraping with curette or gouge?

Moreover, in the event of removing *all* the dead bone,

we are confronted with this condition: before reparation takes place, the surface of the live bone remaining must needs die before reparative action commences, and we are again confronted with the old question of separation of dead bone by natural processes.

MASTOID CASES.

By Clarence J. Blake, M. D., *Boston, Mass.*

Of the twenty-five cases of mastoid congestion and inflammation seen in the first six months of this year, three were treated by means of the continuous cold coil, with excellent effect; the remaining twenty-two cases came to operation at various stages of the mastoid disease, and with various complications.

In three of them the disease of the bone was so extensive as to make it necessary to remove that portion of the inner wall of the mastoid forming the anterior wall of the sinus. Three cases, also, were complicated by extension of pus from the mastoid cells through the digastric fossa or the inner surface of the anterior portion of the mastoid tip, down into the tissues of the neck, and required counter opening and drainage. Two cases died: one on the ninth day, complication with pneumonia, and the other on the tenth day, with meningitis consequent on extension of the suppurative process from the middle ear through the tegmen tympani. The details of operation were much the same as those given at length in the paper read before this Society last year, with the exception of the use of a rongeur to enlarge the opening in the mastoid cortex in a few cases, and an experimental change in after treatment in two of the cases hereinafter mentioned.

The thorough excavation of the mastoid cavity, by means of the sharp spoons, as heretofore practiced, was continued with justifying results.

Of the three following cases in which the mastoid cavity was quite cleared of its cellular structure, one was subsequently dealt with by frequent probing, antiseptic syringing and dressing; in the other two cases the excavated mastoid cavity was allowed to fill in with blood clot at the conclusion of the operation, then superficially irrigated with very hot water, — so hot as just not to scald the skin. The edges of the cut were brought together, covered with a cheese-cloth pad, baked dressing, and a bandage.

The first case healed in four weeks with a deeply depressed cicatrix.

Of the other two, one was practically healed in five days; the other, the first dressing was made on the third day, and on the fifth day a cotton collodion dressing only was required; and in both, the pain and fever incident to the mastoid disease were entirely relieved by the operation. The greater part of the wound healed practically by first intention, and the cicatrix was insignificant.

A CASE OF CHRONIC PURULENT OTITIS MEDIA; OLD PULMONARY TUBERCULOSIS; OPENING OF THE MASTOID; DEATH FROM ACUTE BASILAR MENINGITIS; AUTOPSY.

By Herman Knapp, M. D., *New York, N. Y.*

In view of the great attention which, during the last years, has been paid to severe intra-cranial affections resulting from suppurative ear disease, I beg leave to report a case to show how misleading the existence of suppurative ear disease may be in the diagnosis of severe brain disease. The case will illustrate the fact how, apparently with good reasons, the aural surgeon may be induced to open the mastoid, penetrate into the tympanum, trephine the cranial cavity in the expectation to find an extradural collection of pus, a brain abscess, or purulent thrombo-phlebitis, when in reality the simultaneous presence of brain and ear disease is only a coincidence.

On May 3, 1892, I was called in consultation by Dr. S. Glück, of New York, to see Mr. W. Black, a well built man about 31 years of age. The doctor gave me an extensive history of the case, from which I take what seems essential for my purpose. Since January, 1892, Dr. Glück met Mr. Black socially many times, conversed with him for hours, and found nothing abnormal in him apart from a somewhat pale complexion and moderate hardness of hearing. He was intelligent and made the impression of being a perfectly healthy man. In the middle of April he began to complain of frontal headache. The pain was increased by pressure on the supra-orbital nerve and was

believed to be a neuralgia of the fifth pair. Antipyrin and phenacetine had no effect, but phenocoll acted like a charm, two or three 15 grain doses in twenty-four hours being sufficient to give perfect relief. In the night from 26th to 27th April, he was very restless and excited, but quiet again in the morning when the doctor saw him. Headache moderate. Temperature 100.1°. This temperature continued unchanged for days and there was no retardation of pulse, nor any tenderness or swelling of the mastoid. Pupils normal.

April 27th, vomiting and drowsiness. He had taken chloral hydrate and morphia the night before. The headache had disappeared and the temperature was 98.5°.

April 28th, pulse normal, temperature 101° ; drowsiness, alternating with nervous movements of the hands. Dr. Glück diagnosticated partial meningitis dependent on aural disease. Patient had been carefully examined in Berlin two years previously ; result negative. He had no cough and seemed to have a good constitution. The doctor had no occasion to examine carefully all organs of the patient's body ; everything pointed to brain disease from the ear. Two of our most prominent neurologists without hesitation diagnosticated cranial abscess *ex otitide*, and urged operating.

I was called in consultation May 3d. I learned that he had had discharge from the right ear for three years, which had ceased during the last week. I still found some thin offensive pus in the ear canal. Mastoid and neck normal. Temperature 102.25°. *Headache*, *stupor*, *incoherent and difficult speech*, *delirium*. Pupils and fundi oculorum normal, as well as the movements of the eyes. No painful spot on percussion of the skull. I diagnosticated suppuration in the brain, either extradural, cerebral, or cerebellar abscess. Meningitis and sinus thrombosis did not appear likely. I advised an operation and was asked to perform it.

In the afternoon of the next day, May 4th, the condition of the patient being materially unchanged, I operated on his mastoid, in his residence, assisted by Dr. Glück and some of my assistants, Drs. Mills, Holden, and May. My plan was to remove the external table of the mastoid process and penetrate deeper, as circumstances would seem to indicate, into the attic and cranial cavity. The mastoid was sclerosed throughout. Underneath its outer cortex the bone tissue was blackened in patches and had some small cavities, filled with thin pus. The more deeply I chiselled, the more natural the color of the now uninterruptedly compact bone surface appeared. I chiselled toward the tympanic cavity, along the antrum. It was very laborious work, and when I had penetrated about two centimeters inward and so far forward as to make me suppose that I had penetrated into the antrum, I desisted from going any farther. The bone substance, being hard, ivorylike, and apparently healthy, free from caries and necrosis, gave no indication in which way the morbid process might have travelled into the cranial cavity.

The patient stood the operation well, and answered questions sensibly, though slowly.

May 5th. He was rational and talked well a few hours after the operation, then again with difficulty. Temperature 100.2°, in the evening 103°, pulse 82. No discharge from the wound.

May 6th. Very feeble, comatose; temperature 100°, pulse 80.

May 7th. Unconscious, restless. In the afternoon difficult breathing, as if asphyctic. Dr. Glück opened the mouth with a spatula and saw and removed a large quantity of greenish pus on the left side of the pharynx. His first thought was that he had to deal with a retropharyngeal abscess, but later he came to the conclusion that the pus originated in the patient's lungs. At 6.30 P. M., tempera-

ture 104°, pulse 130. Eyes and limbs in motion; pupils even, responsive. No pain on percussing the skull.

The patient died at 4 o'clock in the morning, May 8th.

I made the autopsy in the afternoon of the same day, assisted by Drs. Glück, Mills, and Holden, of New York, and Dr. Ball, of Keokuk, Iowa.

The brain was taken out in the usual way, leaving it in the skull cap. The whole lower surface, most in the region of the left Sylvian fossa, was covered with a whitish yellow deposit in which a number of small hyalin granules were embedded. The whitish infiltration of the pia was most marked along the veins, conspicuous on the chiasm and pons, extending over the medulla oblongata, and laterally over the cerebellum and the temporo-spheroidal lobes of the brain. The convexity of the brain was fairly normal. The sinuses, ventricles, and substance of the brain showed no noticeable change.

On removal of the dura the whole cranial surface of the temporal bone proved perfectly healthy.

On Dr. Glück's remark that we would probably find tuberculosis of the lungs, I opened the thorax and found his supposition verified. The pleura was adherent throughout, the pseudomembranes watery and emphysematous. The pericardium contained fibrous deposits and a quantity of yellowish liquid. The lungs were congested, dense, studded with tubercles throughout, and contained several cavities in the upper lobes filled with dirty brown liquid.

The right temporal bone and adjacent parts were removed, and put into 35 % alcohol. The next day I sawed through it in several directions. The mastoid and the pneumatic parts surrounding the tympanum were all converted into dense bone. In the tympanic cavity, both antrum and attic, and also in the cavities of the inner ear there was thin pus. No perforation or discoloration anywhere on the inner surface of the temporal.

Anatomical diagnosis.—Chronic tuberculosis of the lungs and pleura; pneumothorax; pericarditis; acute tubercular meningitis. Chronic purulent otitis with sclerosing ostitis.

Remarks.—The most instructive feature in this case is another striking example of the fact that an astonishing degree of extensive tubercular disease may exist in the lungs and pleura, without causing notable disturbance of general health. Whether the ear disease was tubercular in its origin or complicated with tuberculosis later on, I know not, but can possibly ascertain by a microscopical examination of the specimen. The patient died from acute basilar meningitis which was independent of the ear disease. The latter being the only affection of which the patient ever had complained, it was but too natural to suppose it to cause the fatal brain disease. All the physicians who examined the patient fell, like myself, into this error. Had not the healthy condition of the inner part of the mastoid determined me to desist from penetrating into the cranial cavity, for which I was prepared, the diagnostic error would have been followed by an uncalled for and by no means indifferent surgical operation.

RESULT OF OPENING THE MASTOID IN A CASE OF CHRONIC MIDDLE EAR SUPPURATION, WITH CEREBRAL COMPLICATIONS AND SEPTICÆMIC SYMPTOMS. RECOVERY.

By T. Y. Sutphen, M. D., *Newark, N. J.*

May 17th, 1892, the writer was called to see Miss Bertie K., a young lady 16 years of age, living at Jersey City. The history, in brief, was that she had had slight occasional discharge from her left ear for years. Very recently an acute attack had occurred, which had been followed during the last two days by severe pain through the left side of the head, with high temperature. Syringing the ear removed considerable cheesy matter, slightly purulent. The drumhead was absent and the ear was readily inflated. There was no sign whatever of mastoid disease — except the pain. Both pupils were moderately dilated, but responsive to light, and the ophthalmoscope showed swollen retinal veins, but no neuritis. Warm applications about the ear appeared to give relief, and the pain in the head subsided during the next twenty-four hours. May 18th and 19th there were marked and sudden alterations in temperature, ranging from 98° to $105\frac{2}{5}$°, with frequent short chills and occasional vomiting. May 20th, a tender swelling developed in the neck, extending from just beneath the ear downwards, and beneath the sterno-cleido-mastoideus muscle.

May 21st. The patient's condition continued the same, but a small swelling had developed upon the right forearm. Opening the mastoid appeared to be the only

chance left for the patient, but there being no evidence whatever of pus in the mastoid cavity, and the symptoms of thrombosis being so well marked, together with the septicæmic condition which had already developed, I was in doubt as to the advisability of making the operation. In consequence of this, I expressed a wish for the opinion of Dr. Roosa before proceeding. That gentleman met me on the following day, May 22d. The case was no better. Chills, vomiting, and high temperature still continued, and there was a decided cyanotic appearance to the patient. Opening the mastoid, insufficient as were the indications for the need of this, was determined upon as the only chance for the patient's life.

At my request Dr. Roosa made the opening. The drill was employed, the opening being ample and the cavity well explored. A drop or two of pus appeared as the instrument penetrated into the cavity, but beyond that no pus could be found.

The patient rallied after the operation, the temperature decreased a trifle, and there were no more severe chills. During the following six or seven days the patient's temperature did not vary as much as before, ranging between 100° and 104°. There was some vomiting, with occasional headaches, and an inclination to sleep when free from pain. From the time of operation until May 30th, eight days, there was no discharge of pus, either from the middle ear or mastoid, the swelling in the neck remaining the same.

On May 30th pus began to flow freely from the opening in the mastoid, followed by immediate and general improvement in all the patient's symptoms. Everything progressed favorably, the swelling in the neck gradually disappeared, and the retinal veins assumed their normal calibre.

Without the positive evidence of an autopsy, it is rea-

sonable to presume this to have been a case of thrombosis resulting from the middle ear disease, the flow of pus which occurred a week after the mastoid was opened being from suppurative changes outside the cavity of the mastoid but through which it found its escape.

A CASE OF MASTOID DISEASE FOLLOWING AN OPERATION FOR THE REMOVAL OF ADENOID VEGETATIONS.

By Gorham Bacon, M. D., *New York, N. Y.*

The following case seemed to me to be of sufficient interest to report to this Society, as I do not remember having seen mentioned in otological literature any case of mastoid disease, in which the cause was undoubtedly due to the removal of adenoid growths. On the contrary, most all cases of acute otitis media suppurativa are greatly benefited by this operation, and frequently the discharge from the ear ceases almost immediately after the removal of such vegetations.

The patient, Annie R., aged 24, German, came to the New York Eye and Ear Infirmary on February 16th, 1892. She said she had a sore throat and sent for a physician, who told her she had "growths in the nose," and that she would not be any better until they were removed. This was on February 8th, and on the same day she consented to an operation, and he immediately scraped away with his index finger, all the vegetations that he could, and finished the operation on the following day with forceps.

Two days later, she had a severe pain in her right ear, which has been more severe at night, but the pain has been better at times. She has been using hot Pond's Extract for the ear, and she syringed her nose with a carbolic acid solution the day of the operation and the day following.

Examination.—Right membrana tympani dull red, very

much congested, and slight bulging of the same in the posterior inferior quadrant. Left membrana tympani shows evidences of chronic catarrhal inflammation. There is severe pain on pressure over the tip of the mastoid process and well marked evidences of inflammation of the mastoid cells. H. D. watch, right ear, C; left ear, 24″.

I applied my wet-cup at once in front of the tragus and over the apex of the mastoid process, with some relief to the pain, and put the patient to bed. The ear was ordered to be douched with warm boracic acid solution every few hours, and Leiter's coil was applied.

February 17th. The discharge from the ear is profuse. Pain much less severe. The same treatment continued. The patient complained of considerable sore throat and, on examination, it was found to be due to a peritonsillar inflammation of both sides. At 5.45 P. M., temperature 100° and pulse 98.

February 23d. A point of fluctuation was detected in the right peritonsillar abscess and, being incised, about one drachm of pus escaped. The patient was given a gargle, and on the following day an incision was made in the swelling about the left tonsil, but no pus was evacuated. Before the abscess pointed on the right side, she had been taking small pieces of ice. The symptoms of mastoid inflammation having subsided, the coil was taken off.

March 4th. The patient's condition has gradually improved, and on examination today, the right membrana tympani has cleared up very much and the inflammation is rapidly subsiding. There is a small cicatrix in the drumhead just below the umbo, where the membrana tympani was perforated. H. D. watch, right ear, 3″; left ear, 12″. Tuning-fork when placed on vertex, heard louder in the right ear. The ærial conduction is better than the bony conduction for both ears. The ears were inflated by

Politzer's method. The temperature at no time rose above 100° F.

The patient continued to improve and passed from observation.

Although it is possible that the acute otitis media and mastoiditis interna may have been due to water entering the Eustachian tube from the carbolic acid solution syringed through the nares, it is more probable, however, that the removal of the adenoid vegetations, which was done in this case in a very unskillful and brutal manner, was the direct cause, not only of the inflammation about the ear, but also of the peritonsillar inflammation.

At the last meeting of this Society, I read a short paper on the use of the Leiter coil in cases of mastoid inflammation. During the past winter I have had under observation a very large number of cases of mastoid disease, and I am fully convinced that in a large number of these cases the inflammation can be arrested and the patient cured by the application of cold, if seen in the early stage of the disease, and I consider the Leiter coil one of the most valuable appliances that we have, in the treatment of acute mastoiditis externa and interna.

A CASE OF ACUTE PURULENT INFLAMMATION OF THE MIDDLE EAR, WITH DOUBLE OPTIC NEURITIS, BUT WITHOUT TENDERNESS OR SWELLING OF, OR SPONTANEOUS PAIN IN, THE MASTOID PROCESS, IN WHICH THE OPENING OF THE MASTOID CELLS WAS FOLLOWED BY A RAPID SUBSIDENCE OF THE OPTIC NEURITIS AND CURE OF THE EAR DISEASE.

By Charles J. Kipp, M. D., *Newark, N. J.*

Mrs. A. P., æt. 35, consulted me for the first time, July 7, 1891. She complained of pain and throbbing in her right ear and stated that she had been suffering from the ear disease for about six weeks. Previous to this attack she had never had pain or a discharge from either ear. A month before the ear became affected she had an attack of epidemic influenza, which left her in a weak condition. The physician who attended her when she was attacked by the ear disease, punctured the drum-membrane, which gave her some relief. Since then, she has been syringing the ear with tepid water several times daily, and has instilled various kinds of ear drops. She is not suffering very much from earache now, but has a constant throbbing in the ear and the head, which prevents her from sleeping and makes her very nervous. The examination at this time showed that she could hear the tick of my watch (normal hearing distance 60 inches) only when pressed against auricle. She heard my voice only when close to ear. All tuning-forks were heard through air but better

through the bone, and when placed on vertex they were heard better in the diseased ear.

There was but little pus in the external canal, the walls of which were somewhat swollen and red. The drum-membrane was of a deep red color and much thickened, and in its upper anterior quadrant was a small perforation through which air, but no secretion, escaped on making the Valsalvian experiment. The parts behind and in front of auricle were neither red, swollen, nor tender on pressure. The examination of the eyes with the ophthalmoscope showed them to be entirely normal. To secure better drainage of the tympanic cavity, I enlarged the opening in the drum-membrane downwards to its lower margin, and at the same time made several long and deep incisions in the walls of the external canal in the hope of reducing the swelling of the same. I ordered frequent syringing of the ear with tepid $\frac{3}{4}$ % solution of salt several times daily and inflation of the middle ear by Politzer's method once a day. After her first visit to me the patient felt somewhat better, and this improvement continued for two weeks. Then the opening in the drum-membrane had again nearly closed, but the walls of the external canal were but little swollen. The throbbing in the ear was now as bad as before. On the 22d of July I again enlarged the opening in the drum-membrane, as before, and washed out the tympanic cavity with warm salt water by means of the middle ear syringe. But little secretion came away. Inflation of the middle ear through the catheter caused loud perforation noise, but did not cause pus to escape through perforation. The soft parts over the mastoid process were perfectly normal in appearance, and deep pressure over same caused no pain. The ophthalmoscope showed no signs of disease of the fundus oculi. I advised her physician to continue the same treatment. I did not see the patient after this visit for a month, but was told that during this period she

did not suffer much from pain in her ear, but that the throbbing continued. The discharge from the ear had almost entirely ceased. On the 29th of August I made another examination of the ear, and found it in about the same condition as at her first visit to me. The mastoid process was neither œdematous nor red, and not at all tender on percussion. The ophthalmoscope revealed, however, a remarkable change in the eyes. *A well marked optic neuritis was found in both.* The swelling of the optic discs was greater than I had ever before observed in connection with ear disease. The vision was not at all impaired in either eye. Her general condition had also undergone a change for the worse since her last visit to me. The throbbing in the head and ear and the dull ache in the affected side of the head were more pronounced. She felt very weak in her lower limbs, her gait was somewhat staggering, and she had occasional attacks of dizziness. She was listless and at times quite drowsy. Her appetite was very poor and the bowels were somewhat constipated, but she had neither nausea nor vomiting. Her temperature was 99° and her pulse 72. She had no chills or fever at any time.

As in all similar cases previously under my observation, in which I had been permitted to open the mastoid process, I had found an abscess in the bone, I advised my patient to have this operation made at once. She consented, and on the 2d of September I opened the process in the usual place, according to Schwartze's method, with chisel and hammer. The soft parts over the process were entirely normal, and the surface of the bone showed no evidence of disease; no soft or discolored spots could be found. After the removal of the cortex, which was of about the average thickness, a cavity of about the size of a large hazel nut was reached. It was full of foul pus and unhealthy looking granular tissue. The cavity was

thoroughly cleaned out with a sharp spoon and then the antrum mastoideum was reached without difficulty. Water injected into the external canal escaped readily through the cavity in the mastoid. The wound was dressed in the usual way with iodoform gauze and absorbent cotton and the patient put to bed. No reaction followed the operation. For several days the temperature rose to 99.5°, but after that it remained normal. The vertigo, headache, and throbbing in the head and ear continued for several days and then ceased. For a month after the operation there was more or less discharge through the wound, but it was at no time profuse. After that it ceased entirely, but, wishing to be on the safe side, I kept a silver drainage tube in the opening for three weeks longer. Then I allowed the opening to close, which it did in about a week. The otorrhœa ceased four days after the operation, and soon afterwards the perforation in the drum-membrane was found closed.

The patient's appetite improved rapidly and her strength returned gradually but steadily after the operation. The optic neuritis remained stationary for a week after the opening of the mastoid, then it began to subside gradually, and at the date of her discharge from the hospital, September 26, the optic discs were almost normal in appearance. The only remedy administered during her stay in the hospital was hydrarg. c. creta with pulv. ipecac, comp. ãã gr. i. three times daily. During the following six months the patient returned from time to time for examination, and when she was last seen by me, three weeks ago, she was in perfect health. She could hear with the affected ear the tick of my watch at 24 inches. The drum-membrane was of a grayish color, and in its upper anterior quadrant was a large scar. The opening in the mastoid process was firmly closed. The ophthalmoscope showed the optic disc to be pale, but otherwise

the fundus oculi was in a perfectly healthy condition in both eyes. The vision was normal.

While this case presents no feature of unusual interest to the otologist, it demonstrates the value of repeated examinations of the eye with the ophthalmoscope in cases of purulent inflammation of the middle ear. In no other case have I seen the optic neuritis developed within four months from the commencement of the ear trouble. Some surgeons would probably have opened the mastoid process in this case even without knowing of the existence of the optic neuritis, but I doubt that the majority would have done so.

A CASE OF PYÆMIA, FOLLOWING ACUTE SUPPURATIVE OTITIS. RECOVERY.

By J. B. Emerson, M. D., *New York, N. Y.*

A. D., a female, 24 years of age, was admitted to the Manhattan Eye and Ear Hospital on April 4th, 1891. Two weeks before, she had had an attack of the grip, from which she had not entirely recovered. On April 1st she began having pain in her left ear. This pain extended over the entire left side of her head. Twenty-four hours later the left ear began to discharge, but the pain continued.

Previous to the grip she had been in good health and there was no family history.

When admitted to the Hospital, the patient was thin and anæmic, temperature 101° F., pulse 104. There was a free purulent discharge from the left ear. The outlines of the membrana tympani could not be seen on account of the swelling and redness. There was decided tenderness over the whole side of the head, but no more over the mastoid than on the contiguous parts. There was no redness or œdema of the mastoid. She complained of the pain in her head and ear. The patient was put to bed, the canal douched every hour with hot water, three leeches applied to the mastoid, and an anodyne given at bed-time.

April 5th. The patient passed a comfortable night and there is less pain to-day. Poultices ordered over mastoid.

April 6th. The pain continues, though the ear is discharging profusely. Temperature 101° F. Pulse 108. Leeches again applied to mastoid and in front of tragus.

April 7th. Less pain and tenderness.

April 8th. Patient does not feel so well, more pain in ear and head. Temperature 102°. Pulse 100.

April 9th. Feels and looks much better. Temperature 101°. Pulse 96.

April 10th. Morning temperature 101°. Had a slight chill during the day and the evening temperature rose to 105°. Pulse 125. The tongue white and dry, and she has a short, frequent cough. No pain except in the back of her neck, tenderness much less over mastoid and left side of head. No redness or œdema over mastoid. The ear is discharging profusely. Stimulants in the form of milk punches were given.

April 11th. Is in about the same condition. Temperature in the morning 101°, in the evening 105°.

April 13th. Evening temperature 104°. Had a slight chill and at 10 P. M. the temperature had risen to 105.5°.

April 14th. Evening temperature 103°. Complains of pain in her ear; vomited once during the day.

April 15th. The evening temperature reached $105\frac{2}{5}$°, pulse 125. There is *no* tenderness, redness, nor swelling about mastoid — a free discharge from the ear. Dr. Andrew H. Smith examined the chest and discovered numerous rales in both lungs, and pronounced the case one of septic pneumonia. The cough is frequent but no expectoration.

April 16th. Temperature 105°. Condition about the same.

April 18th. Temperature 103°. Pulse 108. Complains of pain in the right side of her chest and in her right shoulder.

April 20th. Patient seems much better. Temperature 101°. Still has pain over her right shoulder and chest,— no special point. Poultices were applied over the upper part of the chest on the right side. Is taking nourishment well.

April 23d. Temperature 100°. Pulse 108. Respiration is rapid, 30 to 40 to the minute. The discharge from the ear is less and she has no pain. There is a small swelling over the right sterno-clavicular articulation. Poultices are continuously applied over that part.

April 25th. There has been continued improvement in the general condition of the patient. The cough is less. Fluctuation being detected, an incision was made over the right sterno-clavicular articulation and about ℥ss of pus evacuated. The abscess was found to involve the joint, and after removal of the pus crepitation could be produced by moving the clavicle. The cavity was packed with iodoform gauze.

May 4th. There has been gradual improvement, the temperature varying — at one time being sub-normal. The abscess of the joint is closing from the bottom.

May 5th. The temperature rose to 103° ; a swelling was discovered just above the right sterno-clavicular joint.

May 6th. The swelling is more marked; extends across the supra-sternal fossa.

May 8th. Swelling is much less; there is more discharge than usual from the abscess.

May 11th. Patient is feeling much better. Temperature 99°. Pulse 100. Respiration 18. The discharge from the abscess much less and the swelling above the sternum entirely gone.

May 16th. Temperature 102°. A collection of pus was found above the sternum on the right side and evacuated through the original opening. Drainage tube inserted.

May 18th. Temperature 103°. An abscess is forming above the sternum in the neck.

May 19th. The abscess was opened by an incision a little to the right of the sternum and one-half inch above. About two ℥ of pus removed.

May 24th. Patient is doing well. Temperature varies from 100½° to 102°. There is free discharge from the abscesses.

May 29th. For the past two days patient has been very irritable. There is now a swelling over the left side of the neck, extending from the mastoid to the clavicle. No indication of pus. Poultices used continuously.

June 3d. The strength of the patient is failing. The temperature has ranged from 99° to 104°. About midway between the mastoid and sternum, on the left side, there is a point in the swelling which is softer, but there is no fluctuation.

An incision under ether was made over the sterno-cleido-mastoid muscle down to the muscle, and after some dissecting through the muscle, pus was found at a depth of about an inch and a half and evacuated, leaving a cavity which extended up to the base of the skull. No direct communication with the mastoid could be found. The cavity was dressed with drainage tube and iodoform gauze.

June 9th. Another small pocket of pus was discovered to the right of the one above the clavicle and a communication between the two established.

June 25th. A similar abscess was found below the clavicle behind the sternum and opened.

July 18th. The patient has improved steadily. The temperature has ranged from 99° to 101°. The abscesses in the chest walls are entirely closed. The discharge from the ear has ceased.

August 4th. The patient was discharged from the Hospital. There was a small fistula in the neck, with little or no discharge from it.

April 26th, 1892. The patient is and has been well for the past eight months — weighs more than she did before her sickness. Says that at times she has a pain in the right sterno-clavicular joint. The membrana tympani is

cicatricial. H. D. L. $=\frac{4}{40}$. The scars where the abscesses were opened are not noticeable.

The treatment extended over a period of four months and was entirely surgical, no drugs being used except for the relief of pain.

Supporting treatment was pushed from the first and whiskey and other alcoholic liquors were given as the condition of the patient indicated them. There were seven distinct abscesses formed, of which one was in the right sterno-clavicular articulation; two in the anterior mediastinal space and one deep down in the muscles of the neck, but, fortunately for the patient, in reach of the knife.

I am indebted to my colleagues in the Manhattan Hospital for advice and assistance in treating this case, and they as well as myself were surprised at the recovery.

Temperature charts of the above case follow.

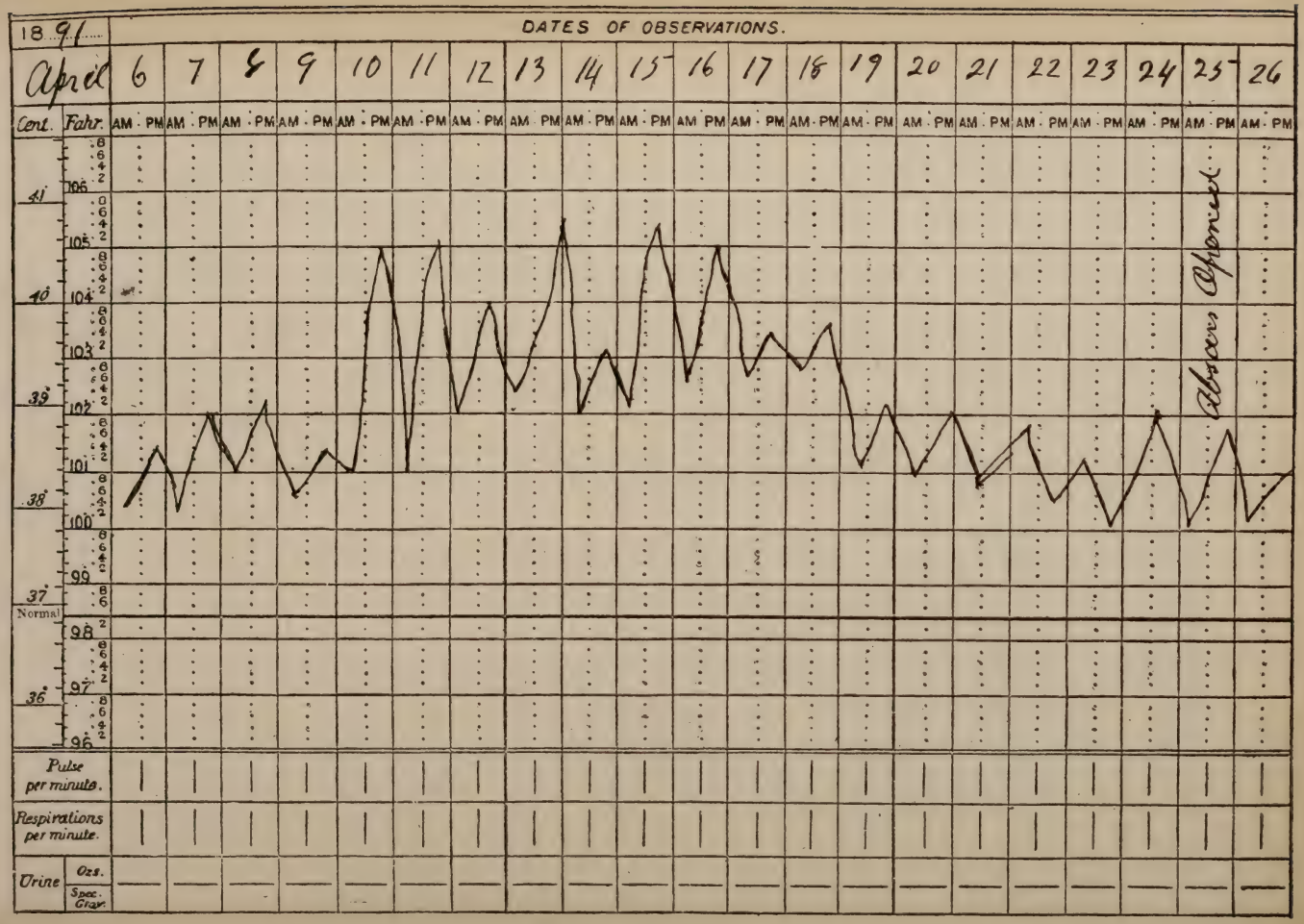
18 91
DATES OF OBSERVATIONS.
April 6 7 8 9 10 11 12 13 14 15 16 17 18 19 20 21 22 23 24 25 26
Cent. Fahr.
AM PM
41° 106 105 40° 104 103 39° 102 101 38° 100 99 37° Normal 98 36° 97 96
Pulse per minute.
Respirations per minute.
Urine
Ozs.
Spec. Grav.
Absent Opened

18.....

DATES OF OBSERVATIONS.

April 27 28 29 30 May 1 2 3 4 5 6 7 8 9 10 11 12 13 14 15 16 17

Cent. Fahr. AM PM

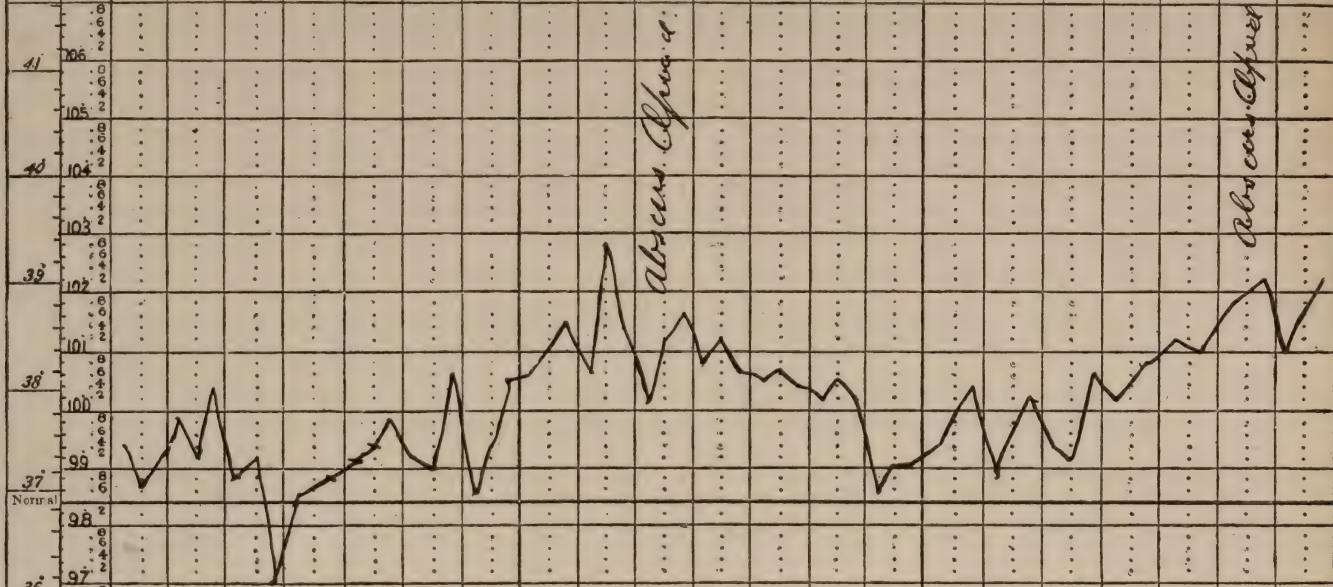

Pulse per minute.	106		100		110	112	100	110	115	112	120	96	130	116	100	116	120	122	118	120	125	130	125	140	120		104	108	100		84	100			100	104	108	100	120	102	106
Respirations per minute.											32		32	32	24	32	36	32	30	36	36	36	36	36	32		24	28	18		22				32	26	28	22	16		
Urine Ozs.																																									
Urine Spec. Grav.																																									

18 .....

DATES OF OBSERVATIONS.

May	18	19	20	21	22	23	24	25	26	27	28	29	30	31	June 1	2	3	4	5	6	7
Pulse per minute.	124			104	120/112	112/112	112/120	110	108	108/112	112/112	106/112	112/130	128/130			125	128/135	120	130	124
Respirations per minute.				24/26		28/32	24/26	32	32				28/28	24/24							
Urine Ozs.																					
Urine Spec. Grav.																					

Cent. 41 40 39 38 37 Normal 36

Fahr. 106 105 104 103 102 101 100 99 98 97 96

AM PM

Above Afebrile

Above Afebrile

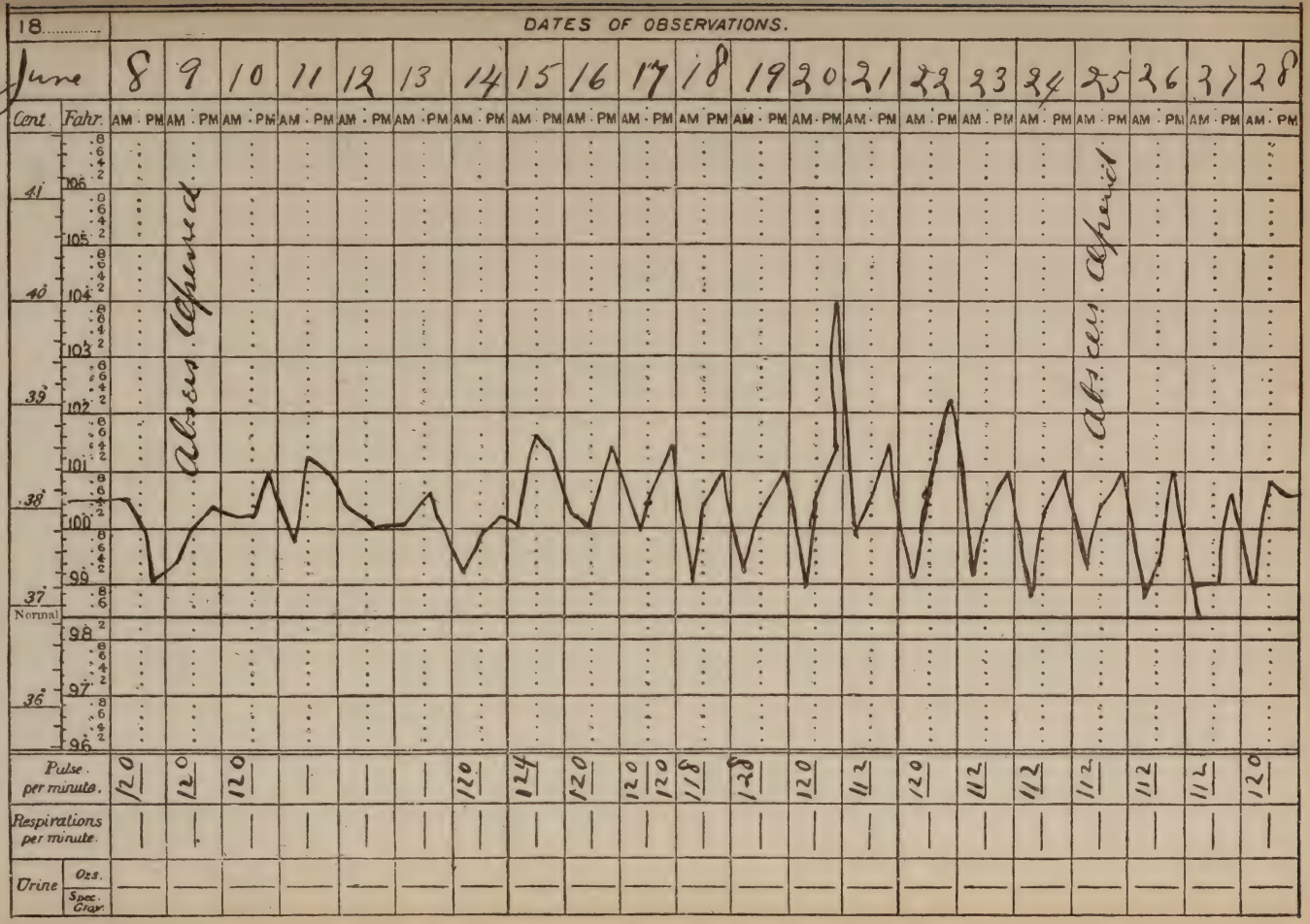
18
DATES OF OBSERVATIONS.
June
8 9 10 11 12 13 14 15 16 17 18 19 20 21 22 23 24 25 26 27 28
Cent. Fahr.
AM PM
41 40 39 38 37 36
106 105 104 103 102 101 100 99 98 97 96
Normal
Absent
Absent
Pulse per minute.
120 120 120 120 120 124 120 120 120 118 118 120 112 120 112 112 112 112 112 120
Respirations per minute.
Urine
Ozs.
Spec. Grav.

18 ..... July

DATES OF OBSERVATIONS

Jun	29	30	1	2	3	4	5	6	7	8	9	10	11	12	13	14	15	16	17	18	19
Pulse per minute.	120	112	112	112	116	112	108	120	112	112	104	112	112	112	112	112	104				
Respirations per minute.																					
Urine Ozs.																					
Urine Spec Grav.																					

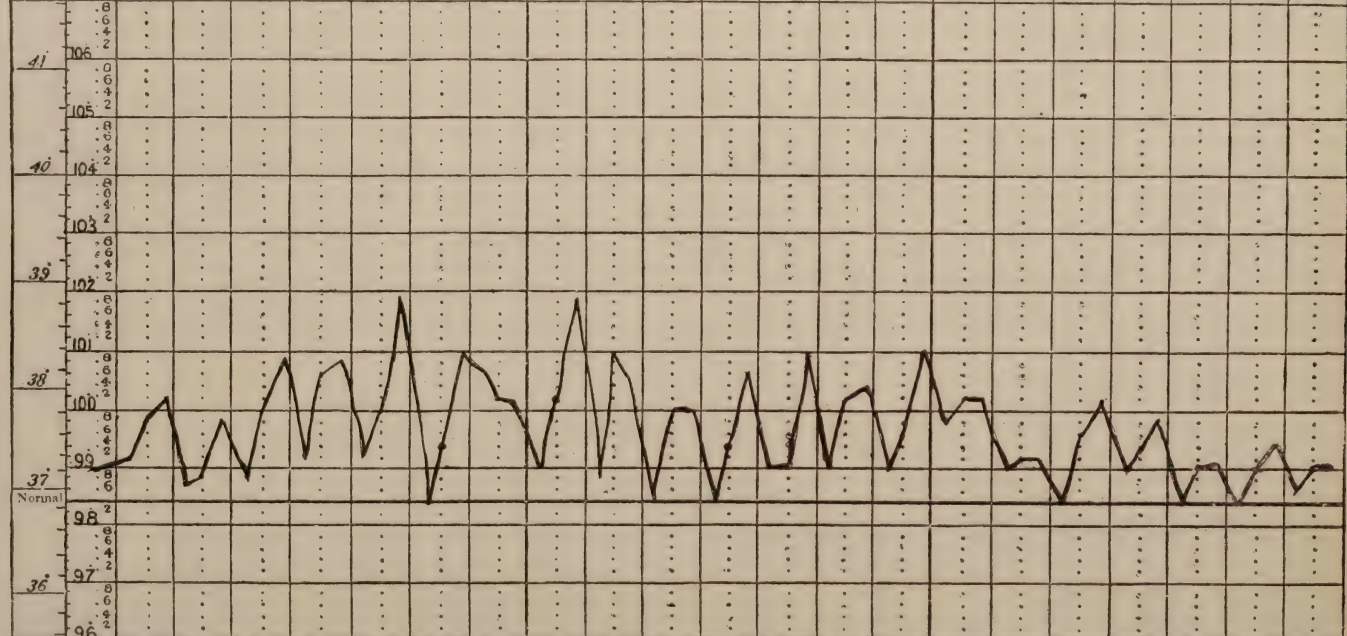

18.....

DATES OF OBSERVATIONS. August

July	20	21	22	23	24	25	26	27	28	29	30	31	1	2	3	4					
Cent. / Fahr.	AM · PM	AM · PM	AM · PM	AM · PM	AM · PM	AM · PM	AM · PM	AM · PM	AM · PM	AM · PM	AM · PM	AM · PM	AM · PM	AM · PM	AM · PM	AM · PM	AM · PM	AM · PM	AM · PM	AM · PM	AM · PM
41 / 106																					
105																					
40 / 104																					
103																					
39 / 102																					
101																					
38 / 100																					
99																					
37 Normal / 98																					
97																					
36 / 96																					
Pulse per minute.																					
Respirations per minute.																					
Urine: Ozs.																					
Urine: Spec. Grav.																					

THE VALUE OF WEAK SOLUTIONS OF BICHLORIDE OF MERCURY IN THE TREATMENT OF OTITIS MEDIA SUPPURATIVA.

By Samuel Theobald, M. D., *Baltimore, Md.*

Perhaps some of the members present may remember that I have more than once spoken to this Society of the good results which I have obtained in the treatment of otitis media suppurativa from the use of solutions of boracic acid. In adding my testimony to that of others as to the value of weak solutions of bichloride of mercury in the same affection, I do not wish to be understood as having abandoned the agent which has done me such good service and of which I have so often spoken words of praise. On the contrary, boracic acid, in solution, is still my first choice as a remedial agent in all cases of recent, and in most cases of chronic, otorrhœa. As I have heretofore pointed out, however, in a comparatively small number of cases, this agent fails to accomplish what we expect of it, and in a still smaller number, which I have spoken of as possessing a boracic acid idiosyncrasy, it actually causes an aggravation of the inflammatory symptoms.

It is in the cases comprised in these two classes, in which I have, heretofore, been somewhat at a loss to know which way to turn for an efficient remedy, that I have recently employed weak sublimate solutions with such good effect. A brief description of several of these cases will detain the Society but for a moment, and will serve to illustrate the method in which the treatment was carried

out. I may add that I have rarely found it necessary to employ a solution of greater strength than 1 to 8000; that I have simply had the ear syringed with this, using from half a pint to a pint of the solution at a sitting, and that, unlike others who have recommended that the bichloride should be used several times in twenty-four hours, I have seldom found it necessary to repeat the syringing more than once a day.

Case I.—Miss X., 9 years of age, the daughter of a physician, had been for a long time subject to recurrent attacks of otitis media in the left ear, and when brought to my notice had a pretty free purulent discharge from this ear. In accordance with my usual practice, the ear was directed to be syringed once a day with a fifteen grain solution of boracic acid, and a tonic was prescribed to build up the system. This treatment was kept up for a considerable time[1], but the discharge persisted. The boracic acid was then discontinued and in its place a very weak solution of bichloride of mercury (1 to 16,000) was prescribed. Within a very few days the discharge disappeared and the perforation in the tympanal membrane closed. Probably two months have elapsed since this change for the better occurred, and so far the case has shown no signs of a relapse.

Case II.—Miss Y., about 10 years of age, had a monaural otorrœa of five weeks' duration, with a history of previous attacks. There was a small perforation in the central portion of the tympanal membrane. Before the case came under my observation the ear had been syringed with a solution of carbolic acid, and boracic acid had been applied by insufflation. Elixir of phosphate of iron, quin-

[1] Written notes of this case were not kept, so that I am not able to give as exact data in reference to it as I should like.

ine, and strychnine, and a daily syringing of the ear with a fifteen-grain solution of boracic acid were prescribed. The discharge, though somewhat diminished, still continued after nineteen days of this treatment. Bichloride solution[1] (1 to 8000) was then substituted, to be used once a day, and within two days the otorrhœa ceased. The patient was irregular in her attendance and was not seen again for three weeks, the treatment having been continued meantime. The perforation was then found to be closed and the tympanal membrane presented a normal appearance. Several weeks after this the patient, in consequence of a cold, had another attack of otitis media with a return of the discharge. The treatment was resumed, but as she left the city at this time, the result is not known.

Case III.—The two year old child of Mr. R., as a result of a recent otitis media acuta had a free purulent discharge from the left ear. A fifteen-grain solution of boracic acid was tried, daily, for six days, without appreciable effect; but, within four days after substituting for this the 1 to 8000 bichloride solution, the suppuration had ceased and the perforation in the membrane had closed.

I might add other cases in which the value of the mercuric solution, used in the manner described, was clearly shown, but those which I have given seem to be sufficient for the purpose in view.

---

[1] I have found it convenient to prepare the solution from the "antiseptic tablets" made by Park, Davis & Co., and known as Dr. Bernay's. One of these dissolved in a quart of water makes a solution of the strength of 1 to 8000.

PRELIMINARY NOTES ON CRANIOMETRIC STUDIES IN RELATION TO AURAL ANATOMY.

By B. Alexander Randall, M. D., *Philadelphia, Pa.*

Numerous special studies have been devoted of late years to the anatomy of the temporal bone, under the stimulus of the increased specialization of otological work and the greater employment of bolder surgical methods. Notable among these are the investigations of Rüdinger, Bezold, Hartmann, Zuckerkandl, and Leidy, and from each we can claim important teachings. But a new point of view was taken by Koerner, when he sought to link together the individual peculiarities of configuration of the temporal bone with the general form of the cranium, and to learn, in a given case, from the mere measurement of the length and breadth of the patient's head, important data as to the dangers and indications of operation. The results which he obtained indicated a general and easy solution of a most weighty question; and it only remained for his study of sixty skulls to be verified by wider investigations in order to serve as a most valuable guide in mastoid trephining. A beginning of such a study was promptly made by the writer; and as its early indications were confirmatory, its clinical application has since been constantly made with satisfaction. But a contradictory result was soon published by Schültzke; and it became doubly manifest that no general rule could be drawn except from a very wide study.

Working in these lines towards a statistical contribution,

it has seemed advisable to bring forward some preliminary data, at this time and place, in order that my methods and views may profit by criticism; while, perhaps, they may stimulate others to like investigation. The conflict between the work of Koerner and Schültzke is great, in both method and result, and each indicts the fundamentals of the other's measurements. It must, therefore, be evident that there is much room for arbitrary choice of aims and means, as well as for the personal equation in employing the methods adopted. It might be better as a means of deciding between these two students, to follow out the methods of one or both; yet I have endeavored to devise a plan applicable, with ease and accuracy, to all the skulls in any collection and giving results which seem to meet the practical requirements of the question.

The method of Koerner requires that the skulls be cut sagitally — a condition obtaining in a few of the many hundred within my reach — and while the calvaria is removable in many, even this is the exception; and the study should be so planned as to be applicable to the intact skull. Thus only may the deductions be based upon the requisite thousands of specimens to lay any fair claim to general applicability.

The several queries, then, which I seek to answer, are:

In skulls of various index, what is the relation of the usual operation track to the sulcus of the lateral sinus?

What is the proximity of the most vulnerable portion of the middle cerebral fossa?

Is the danger greater on the right side than on the left?

With these preliminaries, I may pass to my measurements. The length of the cranium was measured by calipers from the glabella between the superciliary prominences to the most prominent part of the occiput. The distance between the parietal protuberances was taken, but the breadth given is the maximum width of the parietals.

This is often much greater than that at the protuberances, but at times slightly less than could be obtained upon the squamæ of the temporals: yet the latter were so often slightly sprung apart in the macerated skull as to raise a question of the worth of measurements there. The distance was measured between the "spinæ supra meatum" and the inter-mastoid distance was taken at a point 5 millimeters horizontally back of the spina, as the point of election for operation. For the maximum distance between the sulci of the lateral sinuses, a special instrument was employed through the foramen magnum, constructed at first out of a straight-branched spectacle frame, but later made, as in the Fig. 1, to secure greater rigidity. A plain pair of calipers then served to measure the thickness of bone between the sinus and the operation point, 5 millimeters back of the spina, between the sulcus and the back wall of the meatus and at the thinnest point of the mastoid, where the sinus most nearly approached the surface of the mastoid. The distance of this thinnest point behind the spina was also noted. To determine the position of the most vulnerable part of the middle cerebral fossa, a sliding caliper (Fig. 2 a), like a shoemaker's measure, was used to take the position and plane of the spinæ, and a detached L scale, as figured (b), was passed through the foramen magnum and applied to the lowest and most external part of the fossa, as determined by touch aided by sight. Its external part was then brought into relation with the outside scale, its rectilinear position secured by application of its mortised block to the lower edge of the scale, its relation to the plane of the spina secured by the apposition of the surfaces (or any deviation made evident), and then the position of the point read off as to its height and lateral distance within or beyond the spina. The figure will make clearer the manœuvre, which was really simpler than the description may suggest.

The relative size of the lateral sinus of each side was then determined by the eye, and similarly that of the jugular caput and foramen. All the more difficult measurements were made in strong light, generally full sunshine; and the translucency of the bone permitted much more to be seen through the foramen magnum than might be expected, while it made easy the location of the most superficial portion of the sulcus, and in the dangerous bones made the condition readily manifest.

On the results in general, I am not yet ready to report; but it seems worth while to record the data of some one hundred and twenty skulls in the Hyrtl Collection of crania in the Museum of the College of Physicians of Philadelphia. The first hundred was taken and tabulated to serve as illustrations; but as there were only ten dolichocephalic crania among them, twenty-two more of low index were selected to amplify this end of the series. Except thus as to index, the skulls were unselected; and they probably represent fairly the three hundred and more thus far measured. A study of the tabulation of these 31 long, 73 broad, and 18 medium skulls reveals little confirmation of Koerner's hypothetical law; yet, the general rule is evident that the lateral sinus is apt to be larger and more superficial on the right side, and the room for operation on that side may be a little less. The middle cerebral fossa shows much the same variation in height above the spina in all three groups of skulls, and although averaging a trifle lower in the brachycephalic and on the right, it was actually more frequently lower on the left than the right. The measurements show conclusively the extremely practical point, that minimum results may be found on either side and in any form of skull, in a way that will prevent the operator from relying at all upon any general law that may ultimately be deduced, however much it may weigh, perhaps, in questions of the indications and prognosis of operative intervention.

Some description of the instruments devised and their methods of employment should accompany the diagrams and make clearer the measurements taken. The inside calipers (Fig. 1) consist of a crossing pair of slightly curved arms 120 millimeters long, pivoted 75 millimeters apart and centrally slotted through about half their length in order to articulate with a graduated rod sliding in a vertical mortise through the centre of the base. Movement of this vertical rod forward or back symmetrically separates or approximates the tips of the calipers, and their distance apart at any moment is accurately shown by the graduation upon the scale. The points can be brought close together for easy introduction through the foramen magnum, there expanded until they meet the sides of the sulcus on each side, their most external position found and verified by observation through the same opening, and then the distance read off to a fraction of a millimeter. The plane of this measurement is easily determined in relation to that of the spinæ, the outside calipers serving, at need, to demonstrate its exact distance back, and any lack of symmetry in the height or distance out or behind the spinæ.

The instrument for measuring the relations of the middle cerebral fossa consists of a sliding caliper scale (a), with curved points, of sufficient length to embrace the skull from below and close upon the "spina supra meatum" or the depressions just behind them, where they are readily held by light pressure. The second part of the instrument (b) consists of an L scale with an arm 50 millimeters in length and a mortised block sliding upon it so as to furnish an edge at right angles to its length. Introduced through the foramen magnum, the tip of its curved arm easily finds the lowest and most external portion of the middle cerebral fossa or any other point more exposed to injury by proximity to the trephining track, the surface

of its long arm is brought into apposition with the external scale, so as to show that the tip is in the plane of the spinæ, its sliding block is pressed against the lower edge of the external scale to secure its vertical position, and then the height of its tip above the spina can be read off from the graduation. At the same time, its outer edge, which is just 50 millimeters internal to the tip, indicates upon the outside scale by what amount the measured point lies within or beyond the spina,—e. g., in the figure it marks 53 less 50=3 millimeters within. As the fossa often overhangs the spina, the reading may be negative by as much as the scale shows less than 50 millimeters. The same measurements may then be made upon the other side, without shifting the outside scale, by taking the difference between the two readings on the horizontal scale and subtracting 50 millimeters. The sliding caliper is made of such size as to serve for taking all the external dimensions of the skull; but these were quite generally taken with an ordinary pair of calipers, graduated in millimeters. The same were employed, with one branch introduced through the foramen magnum, to measure the distance between the sulcus and the mastoid surface or the back wall of the meatus—the latter measurement being rarely possible in a horizontal plane, as the instrument had to be so inclined that the plane of its tips sloped up and forward about 30°. Similarly the thickness of the bone between the sulcus and the exterior of the mastoid was slightly overestimated through measuring in a somewhat inclined plane. The small errors thus introduced were inconsiderable and fairly constant throughout the series.

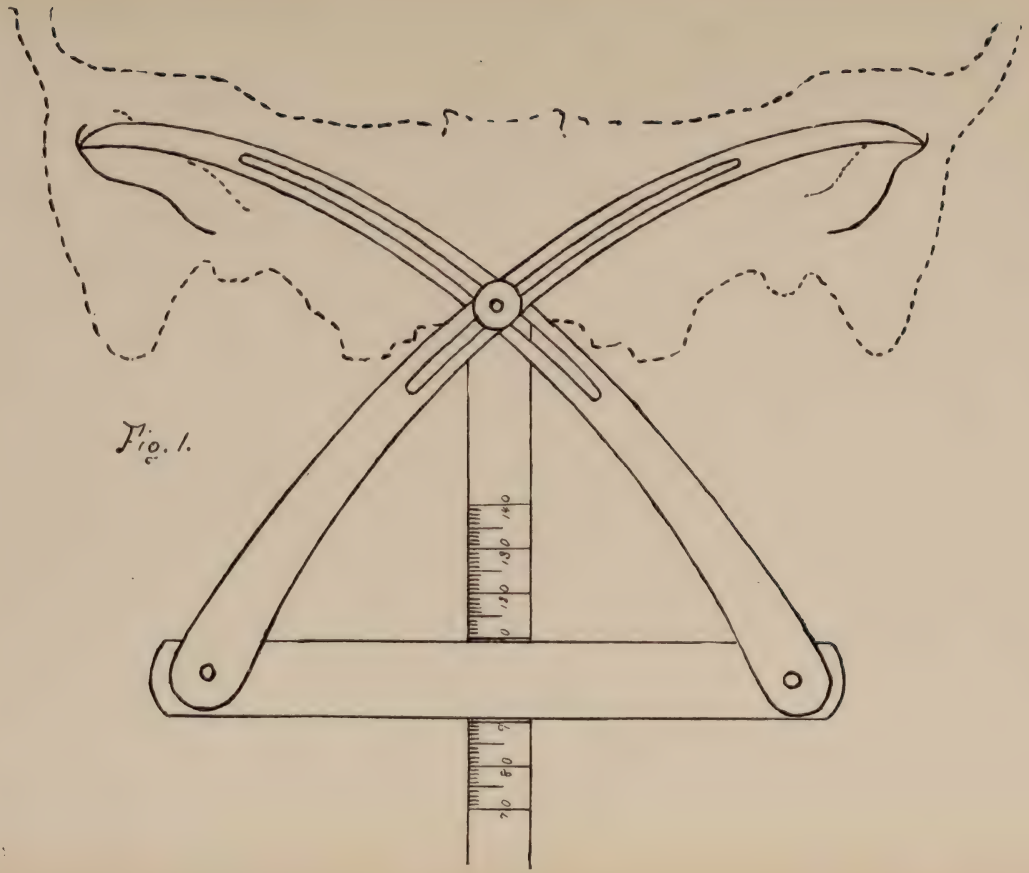

Fig. 1.

Fig. 2.

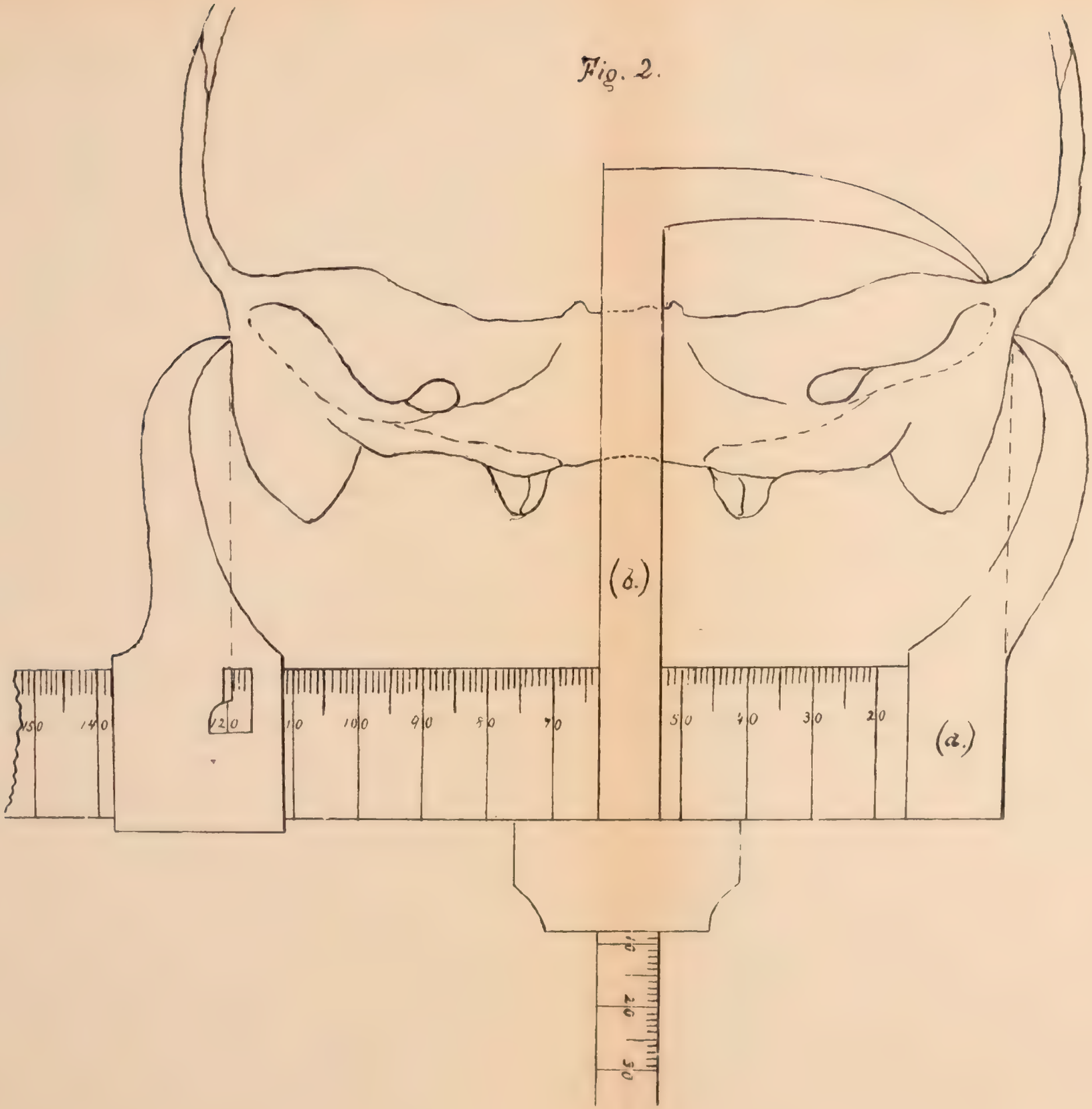

Detailed Data of 122 Skulls in the Mütter Museum.

Skull.	Length.	Breadth.	Height.	Index.	Parietal.	Mastoid.	Spina.	Sinus.	Operation Room.	Meatus to Sulcus.	Thinnest Point, back.		Larger Sinus.	Larger Caput.	Fossa height.		Remarks.
1159.1	200	123	128	.61	117	110	105	112	3	3	2	16	R.	R.	—4	9	
									6	10	5	10			—3	7	
34	196	135	121	.68	130	126	122	124	2	0	2	5	R.	R.	1	5	Tartar m. Upper post. wall lacking on right.
									7	10	4	10			4	10	
145	183	127	133	.69	127	114	109	109	13	14	7	19	L.	L.	1	8	Adult, massive.
									13	14	10	15			1	4	
1168	181	130	135	.71	130	117	111	109	10	11	7	12	R.?	R.	3	9	Young adult.
									15	12	7	14			—1	9	
1188	195	139	135	.71	139	120	116	118	11	12	5	16	R.	R.	4	10	Young adult.
									12	13	6	18			2	6	
1161.01	180	131	138	.72	131	117	109	109	10	12	5	20	L.	R.	4	9	White, old.
									14	12	5	22			2	6	
1155.01	196	145	140	.74	143	122	116	118 117	10	10	6	12	=	L.	4	8	White, adult.
									10	11	5	14			0	6	
51	186	137	123	.73	135	109	104	106	6	6	5	18	R.	R.	—4	2	Greek, adult.
									5	6	4	10			—4	3	
18	187	140	130	.74	140	125	121	117	13	16	10	16	L.?	R.	4	11	Gipsy, male, 24 years old.
									15	15	7	16			3	12	

Skull.	Length.	Breadth.	Height.	Index.	Parietal.	Mastoid.	Spina.	Sinus.	Operation Room.	Meatus to Sulcus.	Thinnest back. Point,		Larger Sinus.	Larger Caput.	Fossa height.		Remarks.
38	168	125	129	.74	125	108	104	106	3	4	2	7	L.	L.	—4	4	Caucasian.
									1	0.2	1	5			—3	6	
57	191	143	137	.74	140	130	125	113	15	15	10	20	L.	L.	4	13	Greek, male.
									13	12	9	14			5	12	
1169.03	185	137	130	.74	125	112	110	106	10	8	5	19	=	=	2	8	White, old, male.
									9	12	5	16			4	7	
131	185	137	135	.74	128	127	122	110	20	20	12	14	L.	L.	—1	10	Bohemian.
									17	20	9	20			2	11	
1169.09	193	144	136	.74	136	129	122	122	11	12	5	20	=	=	5	8	Aged adult.
									10	10	5	19			0	5	
1177	187	139	126	.74	136	117	114	112	9	10	7	11	R.?	L.	4	8	Old, male.
									10	10	6	12			—1	1	
1169.07	177	133	134	.75	130	115	111	117	10	13	7	10	L.?	L.	4	8	Adult, female.
									8	11	4	12			2	9	
104	188	142	145	.75	140	120	113	112	9	15	7	17	=	R. huge.	1	9	Russian.
									10	15	5	18			2	10	
9	183	139	133	.75	138	112	110	109	10	12	6	12	L.	L.	—5	10	Hollander, male, adult.
									15	15	8	16			+1	8	
54	178	144	132	.75	142	120	114	113	10	11	9	10	L.	L.	1	8	Cretan, male.
									10	11	7	11			0	8	

Skull.	Length.	Breadth.	Height.	Index.	Parietal.	Mastoid.	Spina.	Sinus.	Operation Room.	Meatus to Sulcus.	Thinnest Point,	back.	Larger Sinus.	Larger Caput.	Fossa height.		Remarks.
2	184	140	140	.76	139	123	117	113	10	15	5	19	L.?	L.?	2	10	Austrian, male, 29 years old.
									7	11	5	16			1	9	
1165.01	186	143	132	.76	140	127	121	116	12	12	10	15	L.	R.	1	8	
									17	16	10	13			0	7	
1169.05	178	137	134	.76	136	121	116	109	11	14	10	6	R.?	R.	2	6	White, adult.
									12	15	11	13			3	3	
0.23	182	139	142	.76	137	119	117	112	15	16	8	22	L.	L.	—2	6	Drumhead with perforation and chalk deposit; dehiscent post. mastoid wall on left.
									14	16	1	22			1	4	
128	180	138	130	.76	136	115	109	107	15	15	5	22	R.	R.	3	11	Egyptian.
									16	15	6	22			0	5	
0.1	183	142	142	.77	138	127	124	119	15	12	6	18	R.	R.	2	8	Young adult.
									15	12	8	16			2	8	
126	173	134	129	.77	133	124	115	106	19	16	7	21	R.	L.	1	8	Female, 21 years old.
									17	15	14	17			—4	6	
140	181	140	140	.77	137	123	115	109	11	14	8	16	L.?	=	3	10	Chinese, female.
									15	13	11	10			2	7	
1161.03	180	139	123	.77	132	121	121	112 110	11	11	6	14	R.	R.?	1	11	Adult, syphilitic caries.
									14	15	7	12			0	10	
105	172	133	130	.77	127	124	116	108	9	11	9	23	L.	R. huge.	2	5	Caucasian.
									15	15	5	21			2	4	

Skull.	Length.	Breadth.	Height.	Index.	Parietal.	Mastoid.	Spina.	Sinus.	Operation Room.	Meatus to Sulcus.	Thinnest Point,	back.	Larger Sinus.	Larger Caput.	Fossa height.		Remarks.
36	183	142	133	.77	142	127	120	116	14	15	7	18	R.?	R.	1	10	Cashmere, male, 30 years old.
									15	15	6	18			2	6	
53	188	145	134	.77	141	131	125	122	7	10	5	20	R.	R.	0	3	Greek, male.
									11	12	6	16			1	3	
1182.05	172	134	123	.78	134	114	108	110	7	11	4	15	R.?	R.	—1	8	
									12	12	6	16			—2	6	
98	172	134	135	.78	130	131	125	104	15	14	9	24	R.	R.	2	5	Tassia, 37 years old.
									15	12	10	22			4	8	
12	183	143	137	.78	143	125	119	113	15	15	10	20	R.	R.	—3	8	Marmarosch, male, 80 years old.
									16	15	11	20			0	12	
14	185	145	142	.78	143	123	118	117	13	11	6	16	=	=	—1	6	Hungarian, male, 34 years old.
									11	15	8	16			1	5	
19	166	131	127	.78	128	106	100	106	10	10	5	12	R.	R.	—5	9	Ruthene, male, 12 years old.
									10	15	3	14			—3	7	
31	176	138	140	.78	136	124	118	116	12	11	7	12	R.	R.	3	8	Gipsy.
									15	12	6	16			5	8	
32	178	139	135	.78	133	125	120	112	15	18	6	17	R.	R.	5	7	Finlander, male, adult.
									17	13	10	14			5	5	
37	175	137	122	.78	128	131	127	117	15	15	6	21	R.	R.	3	9	Padolian, male, 25 years old.
									12	14	6	18			5	8	

Skull.	Length.	Breadth.	Height.	Index.	Parietal.	Mastoid.	Spina.	Sinus.	Operation Room.	Meatus to Sulcus.	Thinnest Point, back.		Larger Sinus.	Larger Caput.	Fossa height.		Remarks.
76	178	140	128	.78	134	121	118	118	10	10	4	16	R.	R.	—2	7	Saxon, male, 36 years old.
									12	11	6	16			0	6	
99	173	136	133	.78	131	128	121	116	10	13	6	20	L.	R.	2	6	Armenian, 29 years old.
									12	12	5	16			—2	4	
10	164	131	113	.79	135	115	111	110	8	10	2	20	R.?	R.	—4	1	Hollander, female, adult.
									13	14	8	18			—3	6	
44	183	146	129	.79	145	116	111	120	12	15	7	20	L.	L.	0	12	Piedmont, male, 23 years old.
									15	16	6	20			0	12	
55	186	148	134	.79	144	134	129	125	19	13	10	25	R.	R.	5	10	Greek, male.
									9	20	3	12			5	6	
61	182	144	130	.79	142	122	120	116	15	15	5	16	R.	R.	4	11	Austrian, male, 16 years old.
									15	15	6	20			0	10	
70	177	141	126	.79	137	115	114	115	12	15	7	18	R.?	L.?	2	11	Hungarian, male, 23 years old.
									12	15	4	17			2	8	
81	180	143	135	.79	135	129	123	114	16	15	7	21	L.	L.	4	9	Pole, male, 46 years old.
									14	16	6	20			4	6	
85	180	143	129	.79	137	124	119	113	10	11	6	17	=& huge=		0	7	Wende, female, 23 years old.
									5	8	5	5			5	6	
91	175	139	133	.79	137	123	118	111	7	11	7	5	R.	=	5	9	Bosnian.
									12	12	11	14			3	9	

Skull.	Length.	Breadth.	Height.	Index.	Parietal.	Mastoid.	Spina.	Sinus.	Operation Room.	Meatus to Sulcus.	Thinnest Point	back.	Larger Sinus.	Larger Caput.	Fossa height.		Remarks.
21	174	140	123	.80	137	120	116	112	12	15	5	12	R.?	L.?	—3	6	Lithuanian, female, 17 years old.
									12	15	6	14			—2	10	
22	184	148	133	.80	143	136	129	120	11	11	6	19	R.	R.	2	8	Pole, 26 years old.
									12	12	5	21			5	8	
30	177	142	148	.80	138	125	120	122	4	7	4	5	R.	R.	0	8	Syrian, male, adult.
									1	1	1	1			1	6	
47	192	154	145	.80	154	130	122	123	9	11	4	13	=	R.	0	9	Italian, male, 37 years old.
									5	10	3	8			0	10	
52	166	133	124	.80	130	129	123	105	15	11	17	16	R.?	R.	2	3	Microceph., male, 24 years old.
									13	11	5	18			3	6	
68	182	146	134	.80	147	119	112	106	10	10	5	21	R.	R.	0	10	Schleswig, male, 40 years old.
									14	11	10	12			0	9	
78	179	144	127	.80	134	126	119	117	11	15	5	21	R.?	L.?	—2	9	Servian, male, 18 years old.
									16	20	5	22			1	7	
84	176	142	128	.80	135	128	125	119	12	8	6	20	=	=	—1	6	Hannak, male, 25 years old. Right antrum and mastoid open in canal. Dehiscent left mastoid.
									7	13	6	15			+1	6	
94	172	139	131	.80	129	129	123	120	11	12	6	20	=	R.	2	8	Bulgarian.
									11	13	5	20			0	5	
1	183	150	130	.81	138	139	129	118	16	16	6	22	L.?	R.	0	8	Bohemian, male, 19 years old.
									16	15	10	20			3	10	

Skull.	Length.	Breadth.	Height.	Index.	Parietal.	Mastoid.	Spina.	Sinus.	Operation Room.	Meatus to Sulcus.	Thinnest back. Point,		Larger Sinus.	Larger Caput.	Fossa height.		Remarks.
4	175	142	127	.81	141	115	111	109	9	12	4	15	R.	R.	0	6	Bohemian, male, 15 years old.
									15	15	3	16			1	7	
20	179	146	148	.81	139	122	114	120	14	13	3	19	L.	L.	1	9	Ruthene, male, 62 years old.
									15	15	4	12			—1	9	
33	180	146	128	.81	141	132	122	121	14	15	10	24	R.	R.	4	9	Russian, male.
									14	15	12	21			4	10	
39	176	144	141	.81	143	119	118	110	6	10	3	12	R.	R.	2	6	Siamese, male.
									6	9	½	14			2	6	
48	179	146	127	.81	145	122	114	109	10	12	7	15	R.	R.	2	6	Italian, male, adult.
									9	10	8	12			4	7	
50	181	147	129	.81	142	125	117	111	9	10	8	18	L.	L.	3	8	Japanese.
									11	10	5	18			1	7	
73	186	152	133	.81	145	130	123	122	16	11	6	16	R.	R.	—2	6	Russian, male, 38 years old.
									10	11	5	16			3	6	
87	170	139	130	.81	138	113	109	105	11	14	6	18	L.	L.	—2	9	Carniola, 19 years old.
									8	13	4	18			0	6	
90	183	149	128	.81	147	134	131	120	15	15	10	15	R.	R.	3	8	Servian, 24 years old.
									16	15	12	16			3	8	
92	180	147	138	.81	144	131	125	118	10	14	5	17	L.	L.	3	8	Bosnian.
									15	12	10	16			1	5	

Skull.	Length.	Breadth.	Height.	Index.	Parietal.	Mastoid.	Spina.	Sinus.	Operation Room.	Meatus to Sulcus.	Thinnest Point,	back.	Larger Sinus.	Larger Caput.	Fossa height.		Remarks.
28	176	144	135	.81	143	129	121	114	10	10	7	13	L.	L.	2	9	Kurd.
									13	12	5	20			2	8	
3	179	147	131	.82	139	130	123	118	15	12	8	19	R.	R.	0	14	Jew, 41 years old.
									16	12	14	18			3	7	
26	184	151	135	.82	151	128	124	106	10	12	5	16	R.	R.	3	8	Servian.
									15	15	11	12			3	9	
35	180	148	131	.82	131	126	126	122	9	8	6	12	L.	L.	—3	5	Russian, adult, male.
									10	10	4	10			—1	5	
41	177	146	131	.82	141	134	128	121	12	11	3	21	R.	R.	3	3	Swiss, male, 50 years old.
									11	11	4	21			5	2	
43	180	148	132	.82	144	137	129	118	17	11	10	14	=	=	2	2	Italian, male, 32 years old.
									11	10	10	14			0	4	
56	180	148	131	.82	147	123	121	116	9	14	4	13	L.	L.	1	9	Hydriot, male.
									9	10	4	16			1	7	
72	175	145	133	.82	144	130	126	116	12	15	3	18	R.	R.	6	10	Turk, male, 21 years old.
									16	15	3	20			5	5	
15	180	150	131	.83	144	131	125	113	17	15	6	22	L.?	L.?	5	11	Hungarian, male, 21 years old. Dehiscent at spina.
									16	16	7	22			3	7	
23	183	153	141	.83	151	131	121	115	15	15	7	20	R.?	=	4	7	Pole, male, 50 years old.
									14	16	10	20			0	10	

Skull.	Length.	Breadth.	Height.	Index.	Parietal.	Mastoid.	Spina.	Sinus.	Operation Room.	Meatus to Sulcus.	Thinnest Point, back.		Larger Sinus.	Larger Caput.	Fossa height.		Remarks.
86	173	145	132	.83	142	130	123	107	18	15	11	21	R.	R.	4	7	Krain, female, 48 years old.
									18	16	12	21			2	6	
101	177	147	137	.83	144	129	124	110	15	15	6	24	R.	R.	—1	8	Don Cossack.
									13	15	5	24			3	—2	
100	177	147	140	.83	142	138	129	120	15	15	8	20	R.?	R.	2	6	Russian.
									15	15	10	19			1	6	
95	174	146	128	.83	139	126	120	117	15	16	5	21	R.?	R.?	—2	9	Wallachian, 32 years old.
									15	16	7	20			—2	9	
42	165	137	115	.83	135	122	116	116	5	5	3	12	L.?	R.?	—2	6	Italian, female, 23 years old.
									8	7	5	12			0	3	
46	178	148	127	.83	143	128	121	123	11	16	5	20	L.?	=	—1	10	Sicilian, male, 28 years old.
									10	16	6	15			0	10	
60	171	143	129	.83	143	110	108	108	6	11	3	12	R.	R.	1	6	Austrian, male, 16 years old.
									8	11	3	11			0	2	
62	165	137	144	.83	134	117	111	112	5	7	2	20	R.	R.	—1	7	Austrian, male, 13 years old.
									7	11	2	20			1	3	
67	154	129	116	.83	124	116	115	111	10	15	4	16	R.	R.	2	9	Tyrolese, female, 22 years old.
									15	12	6	20			1	10	
69	173	145	130	.83	142	126	123	116	12	11	5	16	L.	L.	2	7	Hungarian, male, 40 years old.
									10	12	6	16			4	5	

Skull.	Length.	Breadth.	Height.	Index.	Parietal.	Mastoid.	Spina.	Sinus.	Operation Room.	Meatus to Sulcus.	Thinnest Point,	back.	Larger Sinus.	Larger Caput.	Fossa height.		Remarks.
96	177	148	133	.83	144	123	115	117	10	15	7	21	=	R.	—1	2	Roumanian, 35 years old.
									7	10	5	16			0	1	
17	174	147	132	.84	140	112	111	115	3	1	1	12	R.?	R.	—3	7	Croatian, male, 24 years old.
									3	1	2	13			5	7	
89	166	141	125	.84	136	121	108	103	10	12	2	16	R.	R.	1	10	Adrian, 20 years old.
									15	15	8	18			1	8	
82	176	148	134	.84	145	126	121	118	14	15	7	20	=	=	—4	6	Greek, male, 26 years old.
									8	15	7	21			—2	7	
5	171	145	127	.84	143	116	116	111	10	11	4	14	L.	L.	0	6	Moravian, male, 17 years old.
									12	11	3	16			2	6	
59	176	149	136	.84	146	127	119	121	9	11	3	18	R.?	R.	4	9	Greek, male, 19 years old.
									8	10	3	11			0	6	
49	188	158	142	.84	157	128	120	116	9	10	7	12	R.	R.	—1	3	Chinese, adult.
									11	11	7	12			1	6	
27	180	152	133	.84	143	132	125	120	11	12	6	19	R.	R.	1	6	Roumanian.
									11	12	5	19			0	3	
83	175	149	132	.85	144	131	125	119	11	15	5	19	R.?	R.?	1	3	Caucasian, male, 43 years old.
									13	15	7	19			5	4	
71	172	147	137	.85	145	132	127	122	10	12	4	13	R.	R.	3	6	Kumann, male, 35 years old.
									11	12	5	18			2	3	

Skull.	Length.	Breadth.	Height.	Index.	Parietal.	Mastoid.	Spina.	Sinus.	Operation Room.	Meatus to Sulcus.	Thinnest Point,	back.	Larger Sinus.	Larger Caput.	Fossa height.		Remarks.
58	168	144	120	.85	140	113	110	109	3	10	1	14	R.	R.	—2	7	Armenian, female, 8 years old.
									9	13	3	16			—4	6	
45	180	153	124	.85	151	127	121	127	10	12	4	20	R.	=	0	5	Sardinian, male, adult.
									11	10	5	20			0	6	
24	177	151	123	.85	144	126	122	115	11	15	7	12	R.?	R.	—4	10	Pole, 42 years old.
									10	13	5	14			—4	8	
65	174	148	140	.85	143	127	121	120	12	11	6	12	L.	L.?	—1	8	Tyrolese, male, 37 years old.
									11	10	10	14			2	7	
97	181	155	135	.85	147	135	126	116	13	15	5	20	L.	=	3	9	Albanian.
									15	15	11	20			1	5	
63	172	149	137	.86	145	123	119	114	10	11	6	16	=	=	2	3	Austrian, male, 19 years old.
									15	11	6	14			1	3	
75	176	153	127	.86	143	149	130	115	17	14	15	19	L.	L.	0	10	Wallachian, male, 50 years old.
									17	15	10	20			0	8	
80	175	151	122	.86	147	116	114	115	10	10	5	16	=	=	—3	9	Bohemian, male, 17 years old.
									9	10	2	16			—3	8	
13	172	148	132	.86	141	127	121	119	14	11	6	19	L.	L.	2	7	Hungarian, male, 28 years old.
									14	10	6	18			3	6	
11	178	155	131	.86	149	126	127	117	14	16	8	18	=	=	—3	6	Hungarian, male, adult.
									16	16	9	20			0	6	

Skull.	Length.	Breadth.	Height.	Index.	Parietal.	Mastoid.	Spina.	Sinus.	Operation Room.	Meatus to Sulcus.	Thinnest back. Point,		Larger Sinus.	Larger Caput.	Fossa height.		Remarks.
29	173	150	129	.86	145	134	131	121	17	19	8	18	L.?	L.?	4	10	
									18	18	10	18			5	9	
25	172	148	134	.86	141	131	127	115	15	15	7	16	R.	R.	1	9	Pole, 30 years old.
									15	15	7	18			0	10	
93	172	150	127	.87	141	123	117	112	10	13	4	20	R.	=	0	6	Bagdad, 13 years old.
									15	13	6	20			—3	7	
66	180	158	146	.87	157	129	125	119	15	17	8	12	L.	=	0	5	Tyrolese, male, 30 years old.
									15	16	5	16			2	4	
74	165	146	129	.88	145	118	112	120	15	11	4	14	R.	R.	—2	3	Carpathian, male, 15 years old.
									12	12	4	16			1	6	
64	166	147	133	.88	145	126	117	115	12	15	4	20	R.	R.	2	12	Cretin, 17 years old.
									15	16	8	12			4	10	
7	170	150	135	.88	146	128	125	116	11	12	5	12	R.?	R.?	2	6	Swiss, cretin.
									11	12	5	12			0	8	
79	171	153	127	.89	148	130	130	126	8	10	5	11	R.?	R.	1	6	Bohemian, male, 25 years old.
									10	10	6	11			0	3	
8	167	149	129	.89	141	121	119	115	14	12	7	15	R.?	R.	1	8	Italian, male, 48 years old.
									10	10	8	11			1	9	
88	163	146	129	.89	143	124	119	112	10	12	5	14	R.?	R.	3	11	Dalmatian, female.
									14	15	7	18			2	8	

Skull.	Length.	Breadth.	Height.	Index.	Parietal.	Mastoid.	Spina.	Sinus.	Operation Room.	Meatus to Sulcus.	Thinnest Point,	back.	Larger Sinus.	Larger Caput.	Fossa height.		Remarks.
16	163	149	132	.91	145	138	122	112	10	11	5	12	L.?	R.	7	6	Savornian, male, 34 years old.
									15	13	10	14			5	6	
77	164	150	129	.91	142	123	120	117	12	15	8	16	R.	R.	1	10	Croat., male, 24 years old. Massive mastoid.
									15	16	10	20			0	7	
6	170	157	137	.92	148	125	122	119	11	7	9	11	L.	=	—3	9	Swiss, cretin.
									11	10	6	11			—2	10	

In eight skulls detachment of the calvaria permitted control from above of the measurements previously made through the foramen magnum. They were confirmed in all cases except 1155.01 and 1161.03, where the bisigmoid distance had been slightly underestimated, as shown by the double figures in the tabulation.

Summarized Table of Dimensions of 122 Skulls.

31 Dolichocephalic Skulls (.615–.776).

OPERATION ROOM.

Right	Maximum	19		
	Average	10.8	Greater	10
	Minimum	2		
			Equal	4
Left	Maximum	20		
	Average	11.9	Greater	17
	Minimum	1		

MEATUS TO SINUS.

Right	Maximum	20		
	Average	11.8	Greater	8
	Minimum	3		
			Equal	11
Left	Maximum	20		
	Average	12.5	Greater	12
	Minimum	0.2		

THINNEST POINT, BACK.

Right	Maximum	12			24
	Average	6.8	Greater	13	15.8
	Minimum	2			5
			Equal	6	
Left	Maximum	14			22
	Average	6.6	Greater	12	15.3
	Minimum	1			5

FOSSA HEIGHT.

Right	Maximum	13		
	Average	8	Greater	20
	Minimum	2		
			Equal	4
Left	Maximum	12		
	Average	8	Greater	7
	Minimum	1		

Sulcus larger—R. 9, R.?4,=4, L ?4, L. 10.
Caput larger—R. 15, R.?1,=3, L.?1, L. 11.

18 Mesocephalic Skulls (.777–.799).

OPERATION ROOM.

Right	Maximum	19		
	Average	12.3	Greater	5
	Minimum	7		
			Equal	4
Left	Maximum	17		
	Average	12.5	Greater	9
	Minimum	5		

MEATUS TO SINUS.

Right	Maximum	18		
	Average	13	Greater	4
	Minimum	10		
			Equal	3
Left	Maximum	20		
	Average	13.7	Greater	11
	Minimum	8		

THINNEST POINT, BACK.

Right	Maximum	10			25
	Average	6.3	Greater	8	17.2
	Minimum	2			5
			Equal	1	
Left	Maximum	11			20
	Average	6.5	Greater	9	16
	Minimum	3			5

FOSSA HEIGHT.

Right	Maximum	12		
	Average	8.1	Greater	12
	Minimum	1		
			Equal	2
Left	Maximum	12		
	Average	7.6	Greater	4
	Minimum	4		

Sulcus larger—R. 11, R.?2,=2, L. 3.
Caput larger—R. 12,=3, L. 3.

73 Brachycephalic Skulls (.800–.920).

OPERATION ROOM.

Right	Maximum	18		
	Average	11.4	Greater	22
	Minimum	3		
			Equal	17
Left	Maximum	18		
	Average	12	Greater	34
	Minimum	1		

MEATUS TO SINUS.

Right	Maximum	19		
	Average	12.3	Greater	19
	Minimum	1		
			Equal	28
Left	Maximum	20		
	Average	12.7	Greater	26
	Minimum	1		

THINNEST POINT. BACK.

Right	Maximum	17			24
	Average	5.7	Greater	21	16.6
	Minimum	1			1
			Equal	15	
Left	Maximum	14			24
	Average	6.3	Greater	37	16.3
	Minimum	0.5			1

FOSSA HEIGHT.

Right	Maximum	14		
	Average	5.9	Greater	37
	Minimum	2		
			Equal	15
Left	Maximum	10		
	Average	6.5	Greater	21
	Minimum	1		

Sulcus larger—R. 29, R.?15,=9, L.?5, L. 15.
Caput larger—R. 40, R.?4,=13, L.?5, L. 11.

DISCUSSION OF PRECEDING PAPERS.

Dr. Knapp: — From Dr. Sutphen's case, in which there was a small opening made at the beginning and the symptoms persisted until, later, an abundant flow of pus relieved the patient, we may take another warning not to make our openings of the mastoid too small. I think that we have reason to believe that Dr. Sutphen's case was one of those in which the morbid process is most intense along the inner (medial) side of the mastoid.

Dr. Blake: — As bearing upon the case reported by Dr. Emerson and the specimen shown by Dr. Knapp, one of the three cases that I have recorded illustrates the importance of thorough opening of the mastoid and also the importance of following up the disease in the mastoid in cases where there are no special mastoid symptoms. The patient in question was a man 45 years of age, well built, and well nourished. As a result of a contusion, he had an attack of acute inflammation of the middle ear, accompanied by a good deal of pain and spontaneous serous, followed by a muco-serous and then a muco-purulent discharge, the pain being relieved coincidently with the appearance of the discharge. Before the discharge had ceased, however, the pain returned and again subsided with the cessation of the discharge; there was some tenderness over the mastoid, more particularly over the antrum, and some tenderness at the tip posteriorly. These symptoms had all subsided before I saw him. The canal and membrane were clear, the latter showing a small scar, and there was neither pain nor tenderness over the mastoid. He was able to go about his business, and had been fairly comfortable, except that there was a sense of fullness in the neck, accompanied by swelling, which had been painted with iodine on the supposition that there was a glandular swelling. The history, of two months' duration,

pointed to acute inflammation of the middle ear, which had extended to the mastoid antrum and then slowly through the mastoid with perforation of the tip and extension down into the neck. Operation on the neck was advised with a view of evacuating the pus, which was evidently deep seated, and at the same time the patient was given to understand that this was to be accompanied by a mastoid operation. The incision, three inches long, was so made as to strike the tip of the mastoid behind the muscle. The mastoid cortex was exposed and found firm and apparently normal. An opening was made with the drill which passed through quarter of an inch of good bone, before any evidence of disease was reached. At the depth of a quarter of an inch, the bone bled much more freely and, continuing the operation, a spot of soft bone was found in the region of the antrum and the whole cavity was thoroughly curetted. Search was made for a possible opening at the tip, but none could be found with the probe. Water passed through the mastoid and out through the membrana tympani, which had been incised as a preliminary. A large probe was then passed into the lower end of the mastoid cut, down into the neck in two directions, and the opening enlarged to admit the finger, which could be passed well in toward the occiput and down into the neck below the middle point between the mastoid and the lower end of the muscle. A counter opening was then made in the neck below, with the liberation of more pus. A large drainage tube was passed from above downward and the whole wound was irrigated with a corrosive sublimate solution. The day after the operation the patient was free from pain and had a normal temperature and there was a muco-purulent discharge from the ear which had been previously dry. On the second day, the muco-purulent discharge was less; on the third day it had ceased, and on the fourth day the membrana tympani was

healed. The mastoid was probed at the first dressing and syringed, and syringed again on the third day, but after that the dressings were confined to the neck alone, in the treatment of which syringing with corrosive sublimate solution and, later, a weak peroxide of hydrogen solution was employed. The case made an excellent recovery and was interesting, as we had here an acute suppurative process of the middle ear which apparently had ceased, but was followed by a progressive inflammation, slowly extending through the mastoid and finally evidencing itself in the neck. It is still further an illustration of the importance of early treatment and of thorough operation in these cases.

Dr. Wilson: — It has been my misfortune during the last year to have two deaths from pus poisoning, in which the line of infection was down the neck. The first case was one of chronic suppuration in a man of 30 years of age. Although there was no pain or tenderness over the mastoid, the mastoid was opened, but no appreciable amount of pus found. During the three or four weeks of his illness, he had high temperature, as high as 105°, and many chills, occurring irregularly, with the usual symptoms of pus poisoning. He finally died and at the autopsy a slight opening was found from the mastoid cells into the cerebral cavity but no appreciable amount of pus. There was, however, a distinct line of purulent infection in which pus could be traced down the right side of the neck and into the left lung, showing that the abscesses in the left lung from which he died were not metastatic but that the purulent infection had extended down the neck into the lung.

The second case was one of acute suppurative inflammation in a man 45 years of age, who had not had ear trouble before. The case extended over a period of about four weeks and there were some slight evidences of trouble

in the neck. This man developed pericarditis and died and the general practitioner whom I called in consultation thought that it was suppurative pericarditis but we could obtain no autopsy. The mastoid was opened in this case and there possibly was a slight amount of pus, but that was doubtful.

I think the first of these cases important, as a positive demonstration at the autopsy of a line of purulent infection, extending from the right mastoid down the neck and into the left lung.

Dr. Reeve :—About nine months ago I had a case of mastoiditis in which I could demonstrate this perforation of the tip that has been shown by Dr. Knapp. The patient recovered after free opening of the mastoid and curetting of the cavity.

In the last month I had a case of extensive lymphœdema, in which the practitioner thought that there was simply an abscess external to the mastoid and that a Wilde's incision would be sufficient. I considered the case one of lymphœdema and advised opening the mastoid. On opening the mastoid, I found the septa carious and scraped them out. In a week, all discharge had ceased from the middle ear and the mastoid, and all œdema had disappeared from beneath the mastoid.

Dr. J. O. Green :—These cases of inflammation of the neck have interested me a great deal and I have seen many of them in consultation with the surgeons of a large general hospital, where the patients were admitted and operated upon for simple abscess of the neck, and afterwards I have been able to demonstrate the connection with the mastoid, and to satisfy some of the surgeons that the mastoid disease was the original trouble. I believe that in every case of abscess of the neck in the neighborhood of the sterno-cleido-mastoid muscle, the possibility of ear disease should be considered.

We have, I think, three varieties of inflammation of the neck directly connected with the ear. First, an extension of the inflammation from the mastoid cells downwards through the base of the bone, giving us pus, at first in small amount beneath the periosteum, then, later, a more or less extensive inflammation of the cellular tissue of the neck within the deep cervical fascia, due to a rupture of the first described pus through the periosteum. Second, an extension of the mastoid inflammation inwards to the groove of the lateral sinus, where we may get a true phlebitis of the sinus, with or without thrombosis, which then extends down the internal jugular vein and there sets up a periphlebitis, giving us the inflamed neck; or else the extension of the mastoid inflammation to the groove allows the pus to extend along the sheath of the sinus and jugular vein, and sets up the same periphlebitis of the neck, without there being a true phlebitis of the jugular and sinus. Thirdly, we may have inflammation of the cellular tissue of the neck, within the deep cervical fascia, from a carious meatus.

Of the second variety I have seen two examples within the last two years at the Boston City Hospital. There was a history of acute suppurative otitis media with mastoiditis, followed by trouble in the neck, beginning with pain and tenderness along the anterior edge of the sterno-cleido-mastoid muscle; then the tissues became hard over a small extent, not more than an inch, with the characteristic appearances of a cellulitis; there were high temperature, slight chills, and general disturbance of the system. There was not the slightest fluctuation. In both cases I expressed the opinion that there was inflammation of the lateral sinus, that the disease was a phlebitis running down the jugular from the sinus, and asked the surgeon to explore the neck for pus. This was done and pus was reached in very small amount, only when the tissues im-

mediately over the jugular vein were opened. The disease, in fact, was a periphlebitis which had not gone on to the formation of any large amount of pus. Both made good recoveries.

In regard to Dr. Kipp's case, it can not be too strongly emphasized that there may be mastoid disease without marked tenderness. Here, it is not necessary to emphasize this point, but with the general practitioner, it is important. The general practioner is continually opposing operation, because he can not actually see the presence of pus in the way of fluctuation or of very great tenderness. We do have serious troubles without tenderness, although this is an important feature in the diagnosis. With other suspicious symptoms of mastoid disease, as otorrhœa, in spite of treatment of the tympanic cavity, I should not hesitate to advise mastoid operation as exploratory in bad cases.

In regard to Dr. Knapp's case of sclerosis, these cases are exceedingly interesting. This is one of the most serious complications in mastoid operations and I find it very common. I should be glad to hear some discussion of the point, whether or not this sclerosis is always pathological. I have sometimes wondered whether it was always a pathological condition, or whether in some cases it was not a hyper-development.

Dr. Tansley :—I should like to say just a few words. I have seen a number of these cases, and I am indebted to Dr. Emerson for a suggestion which he made seven or eight years ago, but which has not been spoken of to-day. At that time, I had a bad case of mastoid disease, with a burrowing abscess down the sterno-cleido-mastoid, which ultimately had to be opened at the clavicle. I passed a drainage tube from the mastoid to the clavicle. The cases took some time but ultimately recovered. Dr. Emerson saw the case in consultation and suggested that a compress be placed at the angle of the jaw and kept there continu-

ously until the mastoid was well. I must confess that in the last eight years this little thing has helped me a great deal. I have had a number of these cases which showed a tendency to burrow in the neck, but since I have adopted this plan I have not had a single unpleasant or bad case to treat. I think that it is an excellent routine method in every case of mastoid abscess. Of course, I use poultices. Every time the poultice is changed the compress is reapplied. It is well to remember these little things and I hope that it will prove of assistance to others.

Dr. Randall: — I have met with a few of these cases. I published a little while since[1] a series of three seen in six months, the abscess burrowing into the neck. One case that I here report is also a case of opening into the digastric fossa. I speak of it principally to lay stress upon a point which I was slow to learn and which has been forced upon me by the necessity for a second operation in one case.

The method of operating on these cases seems to be a little in doubt. Bezold primarily laid stress upon the necessity of attacking the digastric fossa and opening the abscess in that direction and dealing with the neck abscess according to the surgical requirements of the case, but laid no stress upon trephining of the mastoid in a more typical manner. In a later discussion he apparently wholly abandons treatment of the tip and devotes his attention solely to trephining the mastoid at the ordinary point of election. He speaks as though he gave no attention to the tip and a minimum amount of attention to the abscess as it burrows in the neck.

In one of the cases that I have reported, the cortex of the mastoid was apparently thoroughly healthy. The symptoms pointed exclusively to the digastric fossa and the neck at the angle of the jaw. The incision at the back of

[1] Therapeutic Gazette, May 15, 1892.

the digastric fossa opened freely into the fossa and passed beyond into a cavity as large as a hen's egg, and carried me well down to the sheath of the vessels, so that pulsation of the carotid was uncomfortably presented to the probe with which I was seeking for further extension of the disease. I was able when I enlarged the openings already present in the drumhead to secure good irrigation through the meatus from the sinus in the digastric surface of the mastoid, which I enlarged freely with the curette. I therefore contented myself with this operation, which seemed to be directed to all the parts actually involved. I saw the case only for a week, and the patient disobeyed instructions as to the continuance of treatment. The outcome was that three months later I had to operate again, this time opening in a typical way, trephining through the dense surface of the mastoid and opening the antrum, and although I did not find much pus at any point, I found the antrum and neighboring cells filled with flabby granulations. Curetting these away, I found in the back wall of the antrum, in apparent proximity to the lateral sinus, a mass of these granulations, scraping which gave rise to such free venous bleeding that I had to stop the operation, with the strong suspicion that there had been a total loss of the bony wall at that point and that I had opened the lateral sinus. I question whether this was the case, although I could detect no bone. I had previously opened the mastoid on its outer surface, as well as upon the digastric surface, in such cases, thus obtaining free communication, through and through, and I expect to continue to do so. It does not seem quite rational to open the antrum alone when we have trouble at the tip, and it is not safe to attend to the tip alone when we may have trouble in the antrum.

Dr. Jack:—In the treatment of the incision over the mastoid I find that healing is quicker, the scar much

smoother, and there is less trouble with granulations, if a drainage tube is put in and the edges of the wound, above and below, brought together by sutures. The tube is removed in twenty-four hours, leaving a good opening for drainage.

In reference to cases of sclerosis of the mastoid, I would like to speak briefly of a markedly illustrative case,— a male, 58 years of age. Four months previous to my examination he had had an attack of acute inflammation in the right ear with perforation of the drum-membrane. He complained of pain, more or less continuous, over the right eye and in the neck posterior to the tip of the mastoid. This spot was tender on firm pressure and pained very much on even slightly moving the head. No tenderness or swelling over the mastoid. Bone somewhat enlarged. Nothing found in the middle ear to account for pain. He described his suffering for the past four months as terrible. For relief he had been taking considerable morphia. Had lost thirty pounds in weight. It was decided to explore his mastoid and he was operated on Sept. 3d, 1891. The tissues over the bone were found firmly adherent. The chisel and hammer were used with great difficulty through ivory-like bone, to the depth of more than half an inch, where the operation stopped, there being no guide for deeper penetration. No pus was found. Considerable relief from pain followed the operation, although at one time the pain approached nearly its former severity. Dr. J. Orne Green saw the case in consultation and agreed that nothing would be gained by further surgical treatment. The patient subsequently improved and in three months after the operation was entirely free from pain. He had gained flesh and called himself well again.

With reference to a middle ear inflammation following an operation for the removal of adenoids, I agree with Dr. Bacon that it will sometimes happen. Out of about 150

cases, operated upon by myself, there have been three or four instances of sharp middle ear trouble, with slight tenderness over the mastoid. A report in the Boston Medical and Surgical Journal, Sept. 25, 1890, gives the results of removal of adenoid growths in seventy cases of middle ear disease. Relief was afforded many of the cases and had continued in several up to the time of that report, one year and a half after the operation.

Dr. J. O. Green: — I have seen one case where inflammation of the ear followed the adenoid operation. The patient was a boy who previously had had repeated attacks of ear inflammation. The attack came on three days after operation, no application to the nose having been made. I think that these cases occur once in a while.

Dr. Pomeroy: — A word in regard to the propriety of closing the opening in the soft parts in mastoid operations. Several years ago a child a year old had mastoid disease following suppurative inflammation of the drum cavity. I made a tolerably large incision, evacuating pus and did not proceed farther. The wound was not allowed to close. After a little time I found that it gaped and that I could not keep it together, even by a number of deep sutures, and the bone was exposed. There were no signs of reparative action for six or eight weeks and the surface of the bone became carious superficially. There was a most terrible fetor. I scraped the carious bone away with the finger nail. It was nearly two months before any granulations appeared in the wound, but ultimately it healed. I think that I made a mistake in allowing the wound to gape so much, as the bone became uncovered. This would indicate that it is better to partially close the wound made by the Wilde's incision.

Dr. Richards: —In regard to burrowing abscess of the neck, I should like to refer to a dispensary case which was

seen by me last year and which, in its final stage, after transfer to a prominent and skillful general surgeon, was also seen by the President of this Society and by others. The patient was, for special reasons, transferred by me, for operation, to another man and was finally transferred to a third. I have in my own possession no notes of the case. I shall, however, try to secure a full report of it next year. The case was one of acute otitis, following "grippe." There were at first no very urgent symptoms, but there was some indication of this brawny swelling in the neck, anterior to the sterno-cleido-mastoid muscle. The man went about his business, but probably suffered more pain than he gave me reason to think he did. There was a perforation high in the membrane and there were indications that the greater part of the inflammatory trouble was confined to the tympanic vault. Finally I told the man that he would not get well and would probably die if the mastoid operation, suggested when I first saw him as a possible ultimate necessity, were not done. He was operated on at his own house by another gentleman. A large opening was made into the antrum. He did well for a few days and then symptons of pyæmia developed. Dr. Abbe then saw the case, and the patient was transferred to St. Luke's Hospital, where the jugular vein was tied by Dr. Abbe. A clot was found in the vein above the point of ligature and the vessel was washed out. The man did well after this operation, but some two or three days later his condition altered for the worse and an opening was made in the cranial cavity searching for abscess. A small amount of necrotic bone tissue was taken away between the antrum and the upper portion of the lateral sinus. No abscess of the brain was found. Death from pyæmia followed some days after this operation. There was no probability of purulent absorption after the first operation. The man died from lung complication. This case should sooner

have been reported either by myself or one of the other two surgeons who treated it.

The special points in it are the early appearance of brawny swelling in the neck, but of so slight a degree as to excite no alarm. I have seen this swelling appear and disappear. I recall one case seen in the New York Eye and Ear Infirmary, where the man had been told by most of the surgeons there and also those of another institution, in fact by all who had seen him, that he would die if an operation were not done. He came back six weeks later in triumph, perfectly well. There had been a tremendous swelling of the neck. It is not every one of these cases that is sure to die, if left without operative interference, and yet nearly every one of them will properly call for surgical investigation of the cause of the suspiciously located swelling.

Dr. Knapp: — These abscesses that come from the sinuses are sometimes so obscure that we can not trace their origin. In the case from which the specimen shown was removed, the ear on the right side was diseased. In the course of the disease, swelling on the left side of the neck occurred and puzzled me much. It was under the tip of the mastoid. In four or five days it disappeared and then it returned. At the autopsy the lateral sinus of the right side was plugged with blood, but the sinuses on the other side were full of pus, which extended into the left jugular vein and could be moved back in the skull by pressure on the neck.

Dr. J. O. Green: — The case reported by Dr. Knapp is very interesting but I am not astonished, for we sometimes get these wonderful instances just in that way. I spoke of two forms of phlebitis,—one a true phlebitis, with or without thrombus. Sometimes this gives rise to a periphlebitis. In other cases there is simply periphlebitis, without necessarily true phlebitis. In abscess of the neck,

we have the abscess from pus getting into the neck from the mastoid, either deep or superficially, we get abscess of the neck from the external meatus, we get periphlebitis from extension downwards, or we get phlebitis, with or without periphlebitis.

In regard to recovery, we have all seen wonderful cases of recovery. I have seen recovery where the neck was a brawny mass from the occiput to the angle of the jaw, and from the mastoid to the clavicle. I saw this patient six months later, perfectly recovered.

Dr. Fryer: — As bearing on Dr. Knapp's remarks, I would state that Bergman and others have reported cases of brain abscess from disease of the middle ear, the abscess being on the opposite side.

Dr. Andrews: — The remarks of Dr. Knapp bring to my recollection a case which I saw two years ago at Charity Hospital with one of my colleagues, a general surgeon, Dr. James E. Kelly. The patient was a deaf mute, about 40 years of age. There was a chronic suppurative process of the middle ear, with swelling extending from the tip of the mastoid downward and backward, behind the sterno-cleido-mastoid muscle, towards the middle of the neck. The patient had complained of pain in the ear and head for two months previous to his admission to the hospital. Mastoid disease was suspected, but there were no positive indications of this disease. The mastoid was opened, but no pus was found. Dr. K. extended his explorations as far as the axis. An abscess was found over or on the posterior occipito-atloid and atlo-axoid ligaments. The posterior arch of the atlas was bare, and, apparently, necrosed. The vertebral artery was distinctly perceptible and uncovered. About eight weeks subsequently, Dr. K. explored the cavity again, but failed to find the arch of the atlas. The higher vertebro-occipital articulations became anchylosed and, after a long period,

all the sinuses closed perfectly, and, apparently, permanently. It is my belief that the ear was the original seat of the disease.

Dr. Randall :—As bearing on the questiod of phlebitis, I might call attention to one of the specimens shown last year, where caries originated in the tympanum and extended later through the tip of the petrous portion of the temporal bone, giving rise apparently in that way to involvement of both petrosals, superior and inferior, the cavernous sinus, the transverse veins, and the cavernous sinus of the other side.

Dr. Dench : — It has been my fortune in the last year and a half to see three of these cases of burrowing abscess of the neck. In two of them the symptoms were so masked that for quite a long time operation on the mastoid was delayed. In another case the symptoms were marked and the mastoid was opened at once. I am inclined to pay more attention to the subjective symptoms, although the objective symptoms may not be marked. Persistent pain in this region, if we have the slightest objective signs, will warrant the operation, which in itself is not a dangerous one. I think that the entire trend of the discussion seems to indicate an inclination on the part of aural surgeons to expose the mastoid freely and to do a more extensive operation than formerly. It seems to me that this is a movement in the right direction. In several cases operated on, particularly one seen two weeks ago, pus was found only on reaching the antrum. I then considered the propriety of extending the operation further. Removing a thin layer of bone, I found several of the other cells of the mastoid filled with granulation tissue which would have broken down, had it been left undisturbed; going down towards the tip of the mastoid, I found a distinct collection of pus, which apparently was shut off from the other cells.

Another point which has been of interest to me is in re-

gard to clearing out the passage between the middle ear, the mastoid antrum, and the superficial cells. In the more recent cases, I have taken pains to curette this passage and in most cases have removed more or less granulation tissue. In these cases, there has been no discharge from the ear after the mastoid operation. Where, formerly, the ear had needed attention after mastoid operation, in cases in which the above procedure was carried out, a strip of iodoform gauze introduced into the ear after the operation, the ear having been thoroughly cleansed and tamponed before operation, has been left for several days, and when removed it has been exceptional to find any moisture upon it; the drainage being through the artificial opening, rather than through the ear.

With reference to the remarks of Dr. Randall in regard to the exposure of the sinus, I would say that in a case in which there were comparatively insignificant symptoms, the mastoid had broken down, the bone wall of the sinus was destroyed, and the meninges over a space one inch in area were exposed. This was covered by granulations. I used the curette freely without much hemorrhage and the patient recovered.

Dr. Nichols: — Mastoiditis following the removal of adenoid vegetations must be rather a rare complication. In the seventy-five operations which I have done for adenoid vegetations in the last three years, I have never had an instance of suppuration of the middle ear or mastoid after the operation. On the contrary, I can point to two cases in which chronic suppurative processes have entirely ceased after the adenoid vegetations have been removed. I do not know whether it has been on account of the superior drainage which has been afforded, or whether the irritative process has been started by the adenoid condition. In these two cases after the failure of other treatment to overcome the suppuration, the adenoid

was removed and the process stopped in a few days. In the many cases of adenoid vegetations on which I have operated, the ages of the patients ranging from six months to 38 years, I have never had a case of suppuration.

Dr. Tansley: — I should like to say a word on this subject of inflammation of the middle ear from adenoid growths. There is hardly a week passes in which I do not operate from one to three times for adenoid growths. I have operated on a number of cases where there was sub-acute otitis, just on the point of passing into suppuration. Slight exposure to cold or anything of that sort would certainly have given rise to acute otitis in one or both ears. I have never refrained from operating on these adenoid growths by forceps or snare on account of the presence of this inflammation. I have always warned the patient that there was a possibility of the occurrence of suppuration, but I do not think that in any of these cases on which I have operated in the past eight or ten years, there has been a single case in which the operation on the adenoid has not improved the condition of the ear. I remember the first case on which I operated in this way. The individual could not hear at a distance. The watch had to be pressed on the ear. The vault of the pharynx was filled with the adenoid. There was sub-acute otitis in both ears. I told him that I could do nothing for his ears but must operate on the throat immediately. In four different operations, I removed four large pieces, as large as the first joint of my thumb. The result was, that in five weeks he could hear the watch at eight feet with one ear and ten feet with the other. The sub-acute otitis passed away entirely. My experience is that operation on adenoids is always beneficial and I should not hesitate a moment in operating on adenoid growths even if sub-acute otitis were present.

In the case reported, I should say that the inflammation

resulted, not from the operation, but from the snuffing up of the solution afterwards. That is dangerous. We have to criticise the rhinologist with reference to the use of the nasal douche. The use of the galvano-cautery is always dangerous, as leading to suppurative trouble. I use the cold snare or forceps and have had no untoward symptom.

Dr. J. O. Green: — I agree with what Dr. Tansley says in regard to the use of fluids, and especially solid masses of fluid, through the nose. The fact remains that I have had one case of inflammation follow the removal of adenoids, where no application was made. I do not see that this may not occur once in a while in spite of every precaution, just as we have accidents in other operations.

Dr. Myles: — I have had an experience of about one hundred cases of adenoids, which were operated on under ether, and I think that it is a mere coincidence when the bad effect occurs in the ears. In private practice, I have never seen such a case. In sub-acute cases, the hearing is improved wonderfully. I think that there is much in the manner in which it is done. The nasal and post-nasal mucus is very antiseptic. I have watched these cases with the mirror after operation and the process seems much more favorable than after operation on the faucial tonsil.

I generally use some modification of Löwenberg's forceps, as large as possible, so as to get the central part of the tonsil and the base, during the first insertion of the forceps. I find that the inflammation is more severe when the Rosenmüller fossa has to be scraped. The hemorrhage is so great when the operation is performed that I think that the depletion relieves the vessels and you get an immediate effect in that way. I often use vaseline with an antiseptic, or an aqueous solution, and this can usually be used through the nose in the way of a spray or with a medicine dropper. A modified Dobell solution may be used with advantage.

Dr. Pomeroy:—I would ask a question in regard to the rationale of the alleged great improvement to the hearing after removal of adenoid growths, to which reference has been made and in which I do not concur. I have seen few cases in which there was a great increase of hearing after removal of growths. I am in favor of removing the adenoid growths in any case, but I find it difficult to explain this apparently great improvement to the hearing. In a few of the cases the Eustachian tube is obstructed; this is shown by inflation. How do the gentlemen explain this enormous increase in the hearing distance? Dr. Myles refers to the fact that bleeding depletes the drum cavity and that the hearing is improved in consequence. The rule is that there is no excessive hyperæmia. In the majority of these cases, the lowered hearing does not depend upon hyperæmia, and only slightly upon obstruction of the Eustachian tube. What is the other cause of lowered hearing? It must be sclerosis, due to otitis media chronica. We know how much we can do for that. In the majority of cases, this is the principal explanation of the lowered hearing. How can it be brought up by removal of adenoid tissue?

Dr. Richey:—I would suggest that possibly some of the improvement in hearing following removal of adenoid tissue is due to the restoration of the resonating cavity to a more normal condition.

Dr. H. D. Noyes:—I have been interested in Dr. Randall's remarks on craniometric measurements. There is one point which does not directly pertain to that subject and that relates to the topography of the skull, that is, the situation of the lateral sinus with reference to the mastoid process. My observation of a certain number of skulls has struck me forcibly as to the irregularity of the position of the sinus with regard to the mastoid process. We frequently find that the position of the sinus varies greatly from what we should have a right to expect.

A child, the daughter of a physician, was under my care for six or eight years, for chronic otitis media of both ears. The child also had epilepsy and was in feeble health, with probably a tubercular tendency. When she was about sixteen years old, I was summoned to see the girl and found her suffering from an acute attack, which had been present for several days. I found sufficient evidence of mastoid disease and also of cranial trouble. I at once pronounced in favor of operation on the mastoid. At this time, fifteen years ago, the mode of operation was with the drill. I made the incision in the usual way and perhaps went a little further behind the auricle than was necessary. The bone was perforated with considerable difficulty, and the exact spot I cannot absolutely remember. I know that it was my practice to take a line horizontally backward from the middle of the meatus. To my horror I saw a stream of purple blood welling up from the opening, making me think that I had perforated the lateral sinus. I plugged the opening with a bit of wood and left the case. The girl died a few days later. There was no autopsy. What other resource would have been available? What can be done in cases of malposition of the sinus where a perforation is made?

Dr. Reeve: — I do not think it necessary to plug the opening with wood in perforations of the lateral sinus. I have had one or two cases. The lateral sinus will not bleed if you let it alone. In my case, I put a piece of aseptic rubber into the wound and applied a compress in the usual way. After a long time, the patient made a good recovery. The delay was due to the osteitis. I think that I have opened the sinus twice, if not three times. In one I simply closed it in the ordinary way and there was no special danger.

WOUND OF THE LATERAL SINUS DURING AN OPERATION UPON THE MASTOID PROCESS, IN A PATIENT WITH PHTHISIS PULMONALIS. SEPTICÆMIA. RECOVERY.

By D. B. St. John Roosa, M. D., LL. D., *New York.*

Mary D., æt. 23, was placed under my care, at the Manhattan Eye and Ear Hospital, on May 11th, 1891, by Dr. E. A. Davis, who had been the family physician of the patient. The history of the case is, that the patient, who is a delicate young woman, with a cough, had an attack of acute suppurative otitis media in the left ear, about fifteen months since. She recovered from the acute symptoms in a week; leeches were used and a paracentesis of the drumhead performed. One year ago she began to have pain and tinnitus aurium in the right ear, which improved under treatment. She, however, had recurrent attacks during the year. She is now again suffering, and with an additional symptom,—slight tenderness of the mastoid process. She has now had pain for three weeks, the first of which she ascribes to exposure to a draught. There is tenderness and swelling of the mastoid and neck. The tenderness is most marked at the apex of the mastoid process. The auditory canal is red and swelled, the drum-membrane perforated. The hot douche and poultices were used, but, relief not being had in two days, an operation of opening the mastoid was decided upon, and was performed on May 12th. Wilson's trephine was used. After boring for $\frac{1}{16}$ of an inch the cells were reached. A slight flow of venous blood followed the withdrawal of the

trephine. An opening, carious in character, was found immediately beneath the surface of the bone, this involving a large part of the cells. A Bowman's probe, passing freely in and about the drill, was being used to enlarge the opening, when a great gush of venous blood occurred. It was so large and so persistent that a tent of oakum was quickly plugged in the cavity, and the whole wound closed with the same dressing. Borated cotton was firmly applied on this, and a bandage over all. The patient was put to bed, and at 10 P. M. morphia given on account of pain and throbbing in the ear.

May 13th. The patient has done well. Her pulse and temperature have been normal. The bandage was removed, but the dressings were left undisturbed, and a bandage not so tightly applied. At 9 P. M. on this day the temperature was elevated for the first time to 100°, pulse 80, slight headache.

May 15th. Patient has slight pain in the ear. Temperature 99°. Her wound was now dressed and nearly all the oakum removed, but a small part of the tent was left behind. There was no bleeding. The wound looks well. It was cleansed and iodoform gauze applied. On the next day the wound was again dressed by Dr. Frank N. Lewis. (Dr. Lewis had assisted me in the operation. He had the main charge of the treatment of the case, in connection with the house surgeon, Dr. A. E. Davis, until June 21st, and after that, the sole charge until the patient left the Hospital.) The remainder of the tent was then removed. It had a very offensive odor. About a drachm of dark colored blood oozed from the cells. The wound was washed with hot water, and again dressed with iodoform gauze and borated cotton. At 5 P. M., three days after the operation, the patient had a chill, which lasted a little more than half an hour. The patient states that she began to be chilly immediately after the dressing. At 5.30 P. M.

she vomited. Her pulse was 134 and weak, temperature 104.2°. At 9 P. M. the temperature and pulse were about the same. She had copious movements from the bowels, from medicine given in the morning.

May 17th. The temperature after midnight receded to 101°. The wound was redressed and a light poultice applied. Patient had a chill at 10.45 A. M., and the temperature and pulse again went up. The patient could take no nourishment on account of sickness of the stomach. Champagne and whiskey were given during the day, the latter hypodermically. Her pulse during the day reached 200, but came down to 120.

May 18th. The patient rested better. Pulse 120, temperature, per rectum, 100.2°. A watery evacuation from the bowels. The poultice was removed from the mastoid. The patient took peptonized milk during the day. She had a slight chill at 10.30 A. M. and at 8 P. M. Movements of the bowels occurred frequently, and were checked, when excessive, by starch and opium enemata.

May 19th. Patient is resting better. Takes some nourishment by the mouth and peptonized milk per rectum. The morning temperature was 99.5°, evening 102.5°. She had a severe chill at 8.45 P. M. Complains of pain and hardness in the right knee.

May 20th. The chills continue to recur at irregular intervals. The knee is better, but she complains of pain immediately below, and to the outer third of the left clavicle. There is frothy expectoration. The temperature is 101.2°. She is taking a fair quantity of nourishment and ℥ii injections of peptonized milk, per rectum, every two hours.

May 21st. The chills continue. The wound looks well. Takes milk and whiskey, the former with lime water. The bowels moved freely.

May 24th. The chills continue, but no severe ones.

Temperature generally lower, highest 103°. Pain under clavicle and knee.

May 30th. Pulse 100, temperature 100° to 103°. Respiration 40. Sleeps better. Chills continue but are not severe.

June 6th. The wound has healed. The patient is *nauseated constantly and vomits occasionally*. All food is taken by the rectum. Pains under clavicle and in knee and in chest. Dr. A. H. Smith in consultation advised morphia every hour to control vomiting. It had no effect.

June 12th. There is still no change in the existent nausea. The patient is losing flesh rapidly. Small quantity of coloring matter of the bile found in the matter vomited, on examination by Dr. Reyling, besides epithelium from mouth, fat globules, starch granules, half digested mucous fibres, and putrefactive bacteria.

June 15th. Patient is still vomiting, but retained a drachm of clam juice given every two hours.

June 20th. The patient continues the same. Retains no nourishment except that given per rectum. Pulse and temperature a little above normal.

June 27th. The patient has a normal temperature to-day. She has nutritive enemata, but retains nothing taken by the mouth. The next day she had a natural movement of the bowels. The temperature was again above normal, 101.5°, pulse 100.

June 30th. She retained artificial food taken by the mouth (sarco-peptones).

July 8th. The patient has retained no food taken by the mouth until to-day, when she asked for toast and an egg, which were given, and which were retained. She is sleeping well, and has no fever. She has made a decided turn for the better. This has been evident for ten days.

July 15th. It is now a little over two months since the operation upon the mastoid. The patient is taking nour-

ishment every three hours, and is retaining it. Takes coca wine, *vin mariani*, ℥ii, three times a day. She continues to improve, to take solid food, and to go about the Hospital.

Her weight increased. In a few weeks after, she looked as well as when she entered the Hospital. She had no pain in the ear, no redness or suppuration from the canal, and on July 25th, seventy-four days from the opening of the mastoid, she was discharged. In the winter of 1891 and '92 she went to the Adirondacks on account of her cough, and in August, 1892, she was still there, but Dr. Trudeau informs me that she is not materially improved, but with a prospect of recovery. Her ear continued well, and she was not losing flesh.

REMARKS.

It is not possible to say positively that the lateral sinus was wounded in this case, but all the probabilities are in that direction. The patient had had a chronic suppurative abscess for some months when the mastoid process was opened; an irregular, carious cavity, in which there was inspissated pus, was found. It is probable that the wall of the sinus had been invaded by this carious process, so that the sinus was ready to open on very slight provocation. As will be remembered, the trephine was used to open the cells, then a Bowman's probe was employed to explore the cavity. It was while a drill was being used to enlarge the opening, that the profuse and alarming hemorrhage occurred. This was so great as to forbid anything but the use of the tampon.

Several cases of wound of the sinus have been reported, —a notable one by Knapp. In none of them, I believe, has a fatal result occurred as a result of the lesion of this blood channel. In the case now presented, the septicæmia was

probably due to the entrance of the pus into the circulation at the time of the operation. Such a carious cavity as this mastoid was, is pretty certain, unless well cleared out, to produce septicæmia, sooner or later. This was not as grave a case as the one of pyæmia, reported by the late Dr. Edward Ely, which was under his care and mine, but the patient who recovered from pyæmia, as described by Ely, after an operation upon the mastoid, was in much better general health than the patient whose case is now reported. The patient was delicate and had a cough, when operated upon. She was found to have phthisis pulmonalis when she recovered from the septicæmia, but she looked well and weighed as much as, or more than, when the operation was performed. I am constrained to believe, from what has been reported, that a wound of the lateral sinus, much as its occurrence is to be deplored, is by no means generally a fatal accident.

The difficulty of determining beforehand, just what we shall find on opening the mastoid process of an ear that has for a long time been the seat of disease, is clearly illustrated by this case, as it has been in so many others.

There was no good reason for believing that we should find an extensive carious process on opening the bone. But the indications for this operation and the signs which indicate about what pathological conditions will be found, have not yet been made everywhere clear. The operation has been too recently adopted into surgery for this. It is only since 1871 that it has been clearly set forth, as an operation that is often required in this country. We are about as early in its recognition as an indispensable thing to be done, as any civilized people, as the history of the operation shows. It is safe to predict that in another decade, the indications for its performance will be as clearly laid down, as it will be possible to give the rules for operations upon closed parts of the body.

The concluding history of this patient is interesting. Whether the operation and the subsequent blood poisoning had any bad influence upon her general health must, I think, remain an open question. There are points in the therapeutics of this case worthy of remark. When it was known that septicæmia had set in, as was shown by the irregular chills, the redness and tenderness of the popliteal space, and under the clavicle and in the lungs, fortified by past experience, to which allusion has already been made, it was resolved that no medicines intended to directly combat the disease should be given. I believe that the only hope in pyæmia or septicæmia is that the poison may be eliminated through the bowels, the kidneys, and the skin. The antipyretics generally, and especially quinine, shut up the emunctories partially, at least, and in so far interfere with the only means of cure. Not a grain of quinine, of antipyrine, phenacetine, or any such drug, was given. An occasional laxative, with anodynes to a very moderate degree, in the beginning, and the trial of morphia, and per rectum injections of bromide of sodium, with the hope of lessening the vomiting, were given. The laxatives were thought to be very useful, but the bromide of sodium injections and the hourly use of morphia were useless, and were discontinued after a short trial. I think if the fear of high temperature in various diseases could be lessened in the minds of the profession at large, that much good would be done. I think that the benefit from its supposed reduction by the antipyretics is often illusory. In erysipelas, and after serious surgical operations, in my own practice and that of my colleagues, I have seen a temperature of 106° become normal, without the aid of any drug whatever, in twelve hours. Dr. Emerson's case, also reported to this Society, at this meeting, adds to the testimony now accumulating as to the uselessness of drugs to reduce temperature and eliminate the poison in pyæmia and septicæmia.

DISCUSSION.

DR. CARMALT: — Several years ago I had a case of pyæmia, following what I judged to be mastoid disease, but in which the proof as to the original focus of infection was wanting, and it presented this difference from that reported by Dr. Roosa, that the patient recovered. A lad of about twelve years of age was brought to my office by the advice of his family physician, with the statement that he had had "a running ear" off and on for several years and that there had recently been an acute attack attended with several chills, high fever, and other evidence of severe constitutional disturbance, — there was marked mental hebetude and excessive headache. Over the right mastoid there was a marked puffy swelling, pitting and tender on pressure, the ear pushed forward and projecting from the head. I had no manner of doubt as to with what we had to deal. I advised immediate operation, which was carried out in the course of a few hours. I found a slightly sclerosed bone, but got no pus: it may be that I did not go far enough, but I went so far that I got an amount of bleeding that alarmed me. I thought I had opened into the lateral sinus. The blood welled up so that I thought it best to stop the operation and plug the opening in the sinus (?) with iodoform gauze. The case went on to a general pyæmia, abscesses forming in the axilla, near an ankle, and in the opposite arm. I was not allowed to follow the case; both the family physician and I were dropped as a couple of ignoramuses, but the gentleman into whose hands the case ultimately came, reported that the boy made a complete recovery. What the pyæmia resulted from I can not say. I found no pus in the mastoid, but if he did not have mastoiditis there is no value in symptomatology, and yet he got well, after a number of secundary (metastatic?) abscesses had developed, and the original focus never became manifest.

Dr. Randall: — Was Dr. Roosa able to tell more precisely as to the venous lesion or the source of the venous bleeding? Was it discernible that the lateral sinus was laid bare? With regard to a point brought up by Dr. Carmalt — I had the misfortune to have a case to report at the last meeting of the Society where the septic condition had gone on to a fatal meningitis, and for which I could find no reason except purulent absorption in the operation track. I found only a trace of pus in the antrum. There was no communication with the cranial cavity and the intracranial trouble arose apparently from absorption of infective material. This will make me very careful about attacking healthy bone unless I see an absolute necessity for it.

Dr. St. John: — As bearing on this discussion, I should like to put on record a case in which there was a manifest pyæmic condition. The case began with "grip" and ran on to otitis media acuta. The acute symptoms promptly subsided, but left a moderate discharge, which grew less. I then ceased visiting the patient, but two or three weeks later, happening to call, I found the woman in a low constitutional condition but with no local symptoms of importance. When first called to the case, I had carefully examined the mastoid region, but there was no tenderness, redness, or swelling. I examined her still more carefully when I found her in this pyæmic condition. I could find no tenderness except just before operation, when very slight tenderness at the tip of the mastoid could be made out. The discharge from the ear was insignificant. From the condition I was satisfied that there was something wrong with the mastoid. I opened the mastoid and found that the bone was not more than a millimeter in thickness. The cavity exposed embraced almost the whole mastoid and was filled with foul pus. Washing out of the cavity was followed by almost immediate improvement

and four weeks later the patient was practically well. At the time of the operation she was in such a low condition that my assistant was almost afraid to give ether.

Dr. Gruening, I think, asserts that tenderness is the only necessary indication for opening the mastoid, but this case indicates that we do not require much tenderness to justify opening of the mastoid, if there are such severe constitutional symptoms as I have pointed out.

Dr. Roosa: — In reply to Dr. Randall, I would state that I found a large carious cavity, and while I could not see the lateral sinus, by inference I believe that the wall of the sinus had been involved before the operation.

REMARKABLE IMPROVEMENT IN HEARING BY REMOVAL OF THE STAPES.

By Frederick L. Jack, M. D., *Boston, Mass.*

In 1875, Dr. Kessel, of Jena, called the attention of the medical public to a case in which he had removed the drum-membrane, malleus, and incus. Attention to the same subject was again called in 1885 by Dr. Schwartze, who added the result of his own experience in performing the operation. July 20th, 1886, Dr. Sexton read a paper before this Society, describing what is practically the same operation as that performed by Drs. Kessel and Schwartze, although with a different object in view. This object was the cure of chronic otorrhœa.

During my term of service for Dr. Blake last spring at the Massachusetts Eye and Ear Infirmary, I had occasion to perform this operation for otorrhœa about twenty-five times, with general success. About June 19th, I undertook the operation on I. D., aged 12, whose ear had been discharging constantly since babyhood, the result of an attack of scarlet fever. Having removed portions of the membrana tympani, malleus, and incus, and curetted a few granulations from the attic, an examination with the probe showed the head of the stapes to be carious. Fearing the operation would not be successful if the stapes in such a condition were left in the ear, I determined to remove it. By passing a slender knife around the head of the bone, it was loosened from its adhesions; after this a very small hook was introduced behind it, and it was extracted with little effort. However, in its removal, there was observed an amount of suction which led me to fear that a portion of the

bony wall might have adhered to it. But this fear proved ungrounded. The removal of the stapes was undertaken in this case with the greater hope of success, as I had in mind an article recently published by a Frenchman,[1] in which it was stated that the stapes had been removed from animals safely, and also that their hearing had been thereby improved. Careful tests made before the operation had shown that there was very little hearing in the ear, as will appear by the report of the case later. On the morning following the operation the patient informed me that she now heard sounds which she had never before noticed. This fact struck me so forcibly that I was led to hope for good results from the removal of the stapes in other cases.

Some weeks previous to performing the above operation, I had two cases of chronic non-suppurative inflammation of the middle ear, from which had resulted a marked degree of deafness. From the ear in the worst condition I removed the entire drum-membrane, malleus, and incus. The history of this case is as follows : B. S. Thirty-five years old. Had been hard of hearing for fifteen years, but has grown rapidly worse within the last two years. Loud voice heard at a few feet. Both drumheads were dull in color and slightly sunken. Operation, April 2d, 1892. Left membrana tympani, malleus, and incus removed.

Operation followed in a few days by pain and slight mucous discharge. No improvement in hearing. Two months after the operation, the ear remaining without treatment during the time, granulations were discovered on the promontory. These were partially removed, touched with a solution of copper and dermatol insufflated. At the present time the ear is healed, but the hearing remains the same as before the operation.

---

[1]Boltey (Ricaedo). Expériences d'avulsion de l'étrier chez les animaux. Annales des maladies de l'oreille, No. 1, Jan., 1891.

Case II.—D. S. Fifty years old. Hearing much impaired for eight years by chronic non-suppurative inflammation of the middle ears. The drumheads were thickened and retracted. May 18th, 1892. Operation on the right ear the same as in the preceding case. The hearing was improved for several days and then gradually returned to the same condition. Patient experienced considerable pain for two nights and was annoyed for four weeks by a purulent discharge from the ear, which up to the present time continues to form crusts.

Notwithstanding the fact that these operations were performed with all care, and that there was in the second case an improvement in the hearing for a few days, both cases subsequently developed otorrhœa, and the second, tinnitus. Furthermore, in the second case, the drum-membrane had been entirely reproduced, with the exception of an extremely small opening in the centre. Led by these results, I resolved in future cases to see what would be the effect of removing but a small portion of the drum-membrane and the stapes only, leaving the malleus and incus; since which time I have performed operations in this way, with uniformly good results. Recently, I suggested to the two patients above mentioned the benefits to be derived from the removal of the stapes, with the hope of thus securing what would be perhaps the very best basis of comparison of the two operations. Unfortunately they declined to submit to further surgical treatment.

Not only is the simple removal of the stapes much better in its results, as shown by the operations already performed, but on the ground of conservative surgery, it is also much to be preferred. It produces greater improvement in the hearing, and, according to my experience up to the present, there has been no inflammatory reaction whatever, or any other bad results. So far as I have been able to discover, just such an operation as has been performed in these cases

has never been heretofore reported. Accordingly, the operation in detail may be here described, and is as follows :—

The first step is to make a cut shaped like an inverted V in the drum-membrane, just over the incudo-stapedial joint, and allow the part so loosened to fall outwards. This gives a clear view of the long process of the incus and the incudo-stapedial articulation, and also affords an excellent opportunity to observe directly the pathological conditions in this, the most important part of the ear for hearing. In fact, as one or two of the following cases illustrate, a condition is sometimes found which none of the ordinary tests for hearing could have revealed. It might be well then, in certain instances, even for diagnostic purposes alone, to make such an exploratory opening. But to return to the operation. It is important next to separate thoroughly the stapedius muscle from the head of the stapes. This is done by passing a very slender knife (Fig. 1) behind the head of the bone and then carefully cutting the muscle at a short distance from the neck of the bone. Experience shows that this muscle must be completely severed, otherwise, when the stapes is loosened, the muscle will pull its head out of sight and cause great trouble in its subsequent removal. Having cut the muscle, the articulation with the long process of the incus is then severed by passing through the joint from behind forwards a very small triangular knife bent in the shape of an obtuse angle (Fig. 2). If the stapes is not yet perfectly loose, it can be made so by passing a small pointed knife around the head (Fig. 3). A small hook (Fig. 4 or sometimes forceps shown in Fig. 5) now introduced behind the head will, with gentle traction, remove the stapes. However, in one case, the foot-plate remained. The bone usually comes away with some suction. It has been found seldom necessary to use cocaine to prevent bleeding in

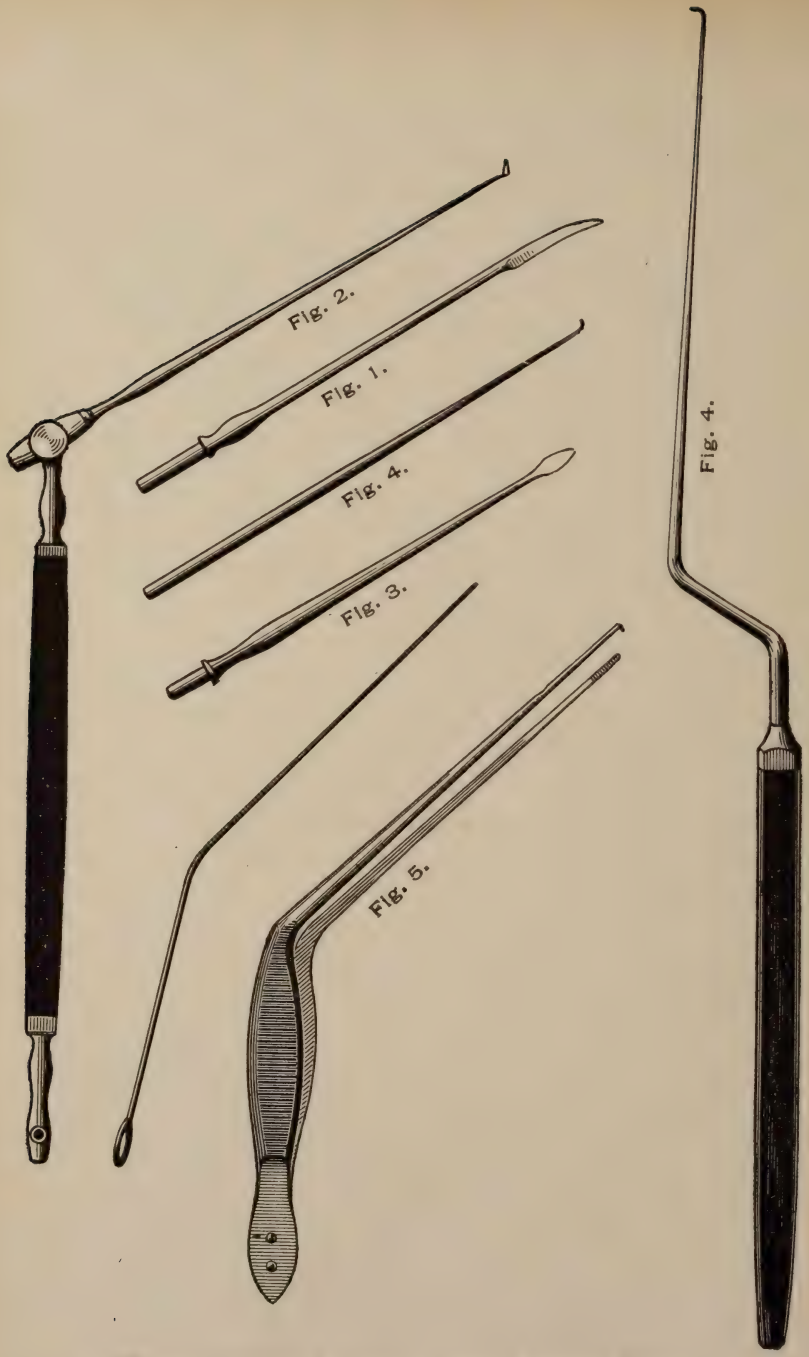

The above instruments were made by CODMAN & SHURTLEFF, Boston.

the small field of operation. Slowing of the pulse was noticed in two or three cases upon touching the stapes. This may have arisen because the patient was not thoroughly under ether. The patients usually remained quietly in bed two or three days, keeping the ear plugged with cotton undisturbed. A clot of blood was generally seen in the wound for a few days, but gradually disappeared. Experience has shown that in the cases where the ear has suppurated, the operation is rendered much more difficult by the conditions thus produced, than in cases of so-called chronic catarrh.

In performing these operations, valuable assistance and suggestions have been received from Dr. W. S. Bryant, for which I desire here to acknowledge my obligations.

Case I.—I. D., æt. 12, otitis media suppurativa chronica in the left ear for eight years. Hears only moderately loud voice. Ear continually discharging. The upper portion only of the drum-membrane is left.

Operation, June 3d, 1892. Remnant of the drum-membrane with the malleus and incus removed. Small amount of granulations curetted from the attic. Head of stapes found carious. It was separated from adhesions and removed with the hook. Slowing of the pulse was noticed upon moving the stapes. Soon after the operation, slight dizziness, probably due to the ether. No pain in the ear. Can now hear voices better than she can remember to have heard them before. Ear ceased discharging in two days. Nineteen days after the operation the middle ear was found perfectly dry.

Ordinary voice heard at twenty-one feet.

Five weeks after the operation the ear was still found perfectly dry and a moderately loud voice could be heard at twenty-five feet.

Case II.— A boy, 12 years of age, in poor physical condition. Chronic suppurative inflammation in the right ear for several years. Only a small portion of the membrana tympani was left and the manubrium of the malleus had sloughed away. He could distinguish words spoken in an ordinary voice at ten feet.

Operation, June 6th, 1892. The remains of the membrane and the malleus were removed after some difficulty because of thick bands of tissue around the head of the bone. The incus was found, after long searching, firmly adherent to the anterior superior portion of the attic. It was freed from its attachment by means of a slender curved knife and removed with a bullet-tipped incus hook. The head of the stapes was next loosened and the bone removed. Nothing peculiar was noticed about the pulse. The ear was syringed with a solution of corrosive sublimate (1 to 3000) and sealed with absorbent cotton. The operation lasted one hour and fifteen minutes. For the next twenty-four hours patient had considerable vertigo. Said, that on moving his head on the pillow objects in the ward went "round and round."

June 15th, nine days after the operation, the hearing remained good and the ear was only slightly moist.

July 8th, 1892. Hearing had improved since the operation, could then hear whispered voice, eight feet; ordinary voice, eighteen feet. Ear slightly moist and had not been syringed for one month.

Case III. — A boy, about 12 years old, with chronic suppurative inflammation in the left middle ear for nine months. A small perforation was discovered high up in the membrana flaccida, but the membrana tensa was whole.

Whispered voice, 18 inches; ordinary voice, 20 feet; H. a. s., $\frac{4}{60}$; tuning-fork, R. C. vertex, s. plus; mastoid, s. plus.

Operation, June 18th, 1892. The entire membrana was separated from the auditory ring. The tensor tympani was divided and the malleus brought forward by passing a blunt hook behind the neck. The incus was removed by means of a hook without difficulty. The head of the stapes was next loosened and removed by means of hook and forceps. It came away in three pieces, leaving in the window a small portion of the foot-plate. The attic was found crowded with granulations, a condition which was suspected before the operation. These were carefully removed with forceps and curette. Three weeks afterward the ear was discharging slightly and the hearing was as follows:

Whispered voice, 8 feet; ordinary voice, 20 feet; tuning-fork, bone, s. plus; mastoid, s. plus; H. a. s., $\frac{2}{60}$.

Case IV.—Female. Anæmic and worn out with pain from syphilitic iritis. The left middle ear showed the effects of an old suppurative process. Through a thin cicatrix the long process of the incus and the head of the stapes were seen.

Loud voice heard at 15 feet; H. a. s., $\frac{3}{60}$; König's rods, 35,000; tuning-fork by bone in left ear.

A triangular opening was made through the cicatrix. The tendon of the stapedius muscle was cut, then the incudo-stapedial joint divided and the head of the stapes freed from synechial bands. The bone was now quite movable, but eluded all attempt to engage the hook behind the head. It was, however, at last captured and removed entire. The trouble experienced here was undoubtedly due to the action of the stapedius muscle, which was not wholly divided. The bone being loosely held in the oval window, the action of the muscle naturally pulled the head out of sight. No change in the pulse was noticed. There was no bleeding. Nausea and vertigo were

complained of for twenty-four hours. She was somewhat dizzy in walking for six days. Hearing much improved.

H., $\frac{10}{60}$; whispered voice, 8 feet; ordinary voice, 20 feet; improvement in König's rods of 5,000.

Ear showed no signs of inflammation at the end of a week. Sixteen days after the operation the hearing remained good.

Case V.— Male, about 40 years old. He gave a history of having had chronic suppurative inflammation of the right middle ear for twenty-five years. He had been very hard of hearing in the ear ever since that time, and said he considered the ear dead. Complained of a disagreeable pressure on that side of the head. Examination of the ear showed extensive destruction of the membrana tympani. Malleus retracted and firmly adherent to the inner wall of the middle ear. The long process of the incus was not visible. Head of the stapes covered with a thick cicatricial membrane. Hearing very defective.

For H., $\frac{0}{60}$, contact; whispered voice not heard; ordinary voice, 1 foot; König's rods, 35,000; tuning-fork by air, 5″, bone, d. plus.

Operation, June 20th, 1892. A triangular opening was made in the membrane over the stapes. A very slender knife was carried around the head, and the tendon of the muscle divided. Owing to the prominence of the head it was grasped with small forceps and all but about one-half of the foot-plate was removed. This piece remained in the fenestra and was easily felt afterwards with the probe. Owing to this state of affairs, it was a surprise on the morning after the operation to find a marked improvement in all but one of the tests of hearing previously tried.

H., $\frac{1}{60}$; loud whisper, 2 feet; ordinary voice, 9 feet; loud voice, 20 feet; König's rods, 30,000, a loss of 5,000.

Four days after returning home, his hearing remained

the same and the pressure previously complained of in the head had disappeared. He volunteered the story that before the operation his wife had complained very much of the squeaking made by a pair of new slippers. He failed to hear the noise at that time, but on his return home he, also, found them too noisy.

July 8th, 1892. Said he had thrown the new slippers away. Hearing remained good and practically the same as when last tested. The ear was perfectly healed. The membrana tympani had somewhat contracted from the fenestra ovalis and was adherent to the inner bony wall of the middle ear. The anterior segment of the membrane was somewhat more sunken than when seen shortly after the operation. This condition made no apparent difference in the power of hearing and did not tend to produce the pressure in the head complained of before the operation.

Case VI.—Female, 20 years of age. Deafness due to the effects of a chronic suppurative inflammation. No discharge from either ear for two years. Said she could not hear anything in the left ear. Everything had ulcerated away except the stapes, the head of which was made out through a somewhat thick cicatrix. Hearing in the left ear as follows:

Whispered voice, not heard; ordinary voice, not heard; loud voice, 1 foot; H. a. s., $\frac{0}{60}$; tuning-fork, by air, not heard, by bone, in the better hearing ear.

Operation, June 11, 1892. Head of stapes loosened and stapedius muscle divided. A hook readily brought away the bone. June 20th, 1892. No pain or vertigo, hearing greatly improved.

Whispered voice, 1 foot; ordinary voice, 15 feet; loud voice, 20 plus; tuning-fork, air, 2″, bone, still heard in better hearing ear; H. a. s., $\frac{1}{60}$.

One month after the operation, hearing remained as when last tested. Ear perfectly dry with no crusts. Said she could now carry on her work of stenography without trouble.

Case VII. — A boy, 18 years of age. Patient was first seen on June 19th, for deafness in the right ear. Upon examination the right drum-membrane was found partially destroyed and the remaining portion was calcified. Thick tissue over the fenestra ovalis. Ear had ceased discharging some years ago and the hearing had been gradually growing worse.

Hearing, H., $\frac{c}{60}$; König's rods, 35,000; ordinary voice, 9 feet; tuning-fork, R. plus by bone.

Operation, June 20th, 1892. Head of stapes found with difficulty after cutting almost calcareous bands of tissue. The bone was found very firmly held in place. Crura were found so firmly fixed in the window that only portions could be removed. The head of the bone came away readily. The pulse was noticed to go slower upon moving the stapes.

June 21st, 1892. No pain complained of. Hearing much improved. Tests as follows:

H. a. d., $\frac{8}{60}$; König's rods, 40,000; whispered voice, 4 feet; ordinary voice, 30 feet plus.

Only slight redness observed at seat of operation.

Case VIII. — Girl, 17 years of age. Deafness in the right ear due to the effect of a chronic suppurative inflammation. A large perforation was found in the posterior half of the membrana tympani, through which the head of the stapes was distinctly seen. Complained of a buzzing tinnitus.

Hearing for whispered voice, 4 feet; ordinary voice, 20 feet; H. a. d., $\frac{5}{12}$; König's rods, 35,000.

Operation, June 21st, 1892. The head of the bone was thoroughly separated from adhesions and easily removed by means of a small hook inserted behind the head. No bleeding. Pulse was perceptibly slower while moving the stapes. June 22d, no symptoms.

Hearing, H., $\frac{13}{60}$; loud whisper, 15 feet; ordinary voice, 25 feet plus; König's rods, 30,000.

June 29th, hearing remained good and tinnitus nearly gone. No moisture in the ear. Improvement in hearing said to be noticed by members of her family and friends.

Seventeen days after the operation, ear was perfectly healed. Less tinnitus. Hearing the same as when last tested, except for the watch. Here there was apparently a loss of ten inches.

Case IX.—Male, 35 years old. Deafness in the left ear since boyhood, the effects of a chronic suppurative inflammation, following an attack of scarlet fever. A large perforation was found in the posterior upper quadrant of the drum-membrane. Head of stapes easily seen and removed in the manner previously described. Hearing before the operation:

H., $\frac{1}{60}$; whispered voice not heard; ordinary voice, 2 feet; loud voice, 12 feet.

On the next morning after the operation, the patient complained of slight dizziness when sitting up in bed. Hearing for the voice improved.

June 27th, no dizziness. Hearing better than immediately after the operation; no signs of inflammatory reaction in the ear. Can now hear:

Whispered voice, 1 foot; ordinary voice, 25 feet plus; tuning-fork by bone, d. plus; tuning-fork, air, 35″; H., $\frac{c}{60}$; König's rods, 30,000.

He was last seen nine days after the operation and was found to hear as well as when previously tested.

Case X.—J. M., 19 years old. She has been troubled with chronic suppurative inflammation off and on for fifteen years and has had trouble about hearing for two years. The posterior segment of the membrana tympani had ulcerated away. The round window and the long process of the incus were easily seen.

Hearing for H., $\frac{4}{60}$; whispered voice, 2 feet; ordinary voice, 6 feet; tuning-fork, bone, d. plus; König's rods, 30,000.

Operation, June 22d, 1892. Stapedius muscle was first cut and then the incudo-stapedial joint. Some trouble was experienced in removing the stapes from behind the long process of the incus. The incus was found so loose that in passing a hook above the head to remove it, it fell from its position to the bottom of the middle ear behind the drum-membrane and could not be removed with any instrument at hand. It was finally removed by syringing. On the following day she complained of some dizziness. Hearing better, with exception of watch, which could not be heard on contact.

Whispered voice, 3 feet; ordinary voice, 9 feet; loud voice, 25 feet; tuning-fork, vertex, s. plus, T., d. plus.

July 1st, slight dizziness; hearing the same, slight moisture in the ear. In two weeks the wound was found perfectly healed. Hearing remained good.

Case XI.—Female, 35 years of age. This case is one of the most interesting in the series. She gave a history of sudden loss of hearing in the left ear, six months before, accompanied with tinnitus and vertigo. Membrana tympani somewhat thickened. The hearing of this ear was very carefully tested by Dr. Bryant and others, and found to be absolutely gone for all sounds, except a very loud shout through a conversation tube. Tuning-fork by bone heard only in the right ear. The operation for removal

of the stapes was performed on the morning of June 23d, 1892. In the evening, much to our surprise, she could hear the voice in the ear, but the hearing was not carefully tested until the next morning, when it was found as follows:

H. a. s., $\frac{c}{60}$, lightly; whispered voice, 7 feet; ordinary voice, 10 feet; loud voice, 20 feet; tuning-fork, vertex and T., s. plus, air, T., 15″; König's rods, 45,000.

The patient was tested by the same gentlemen who saw her before the operation with results practically agreeing. She was entirely free from dizziness and tinnitus.

July 8th, fifteen days after the operation, the hearing remained good. Tuning-fork by bone now heard louder in the ear which was operated upon. Has had no attacks of dizziness and tinnitus. Wound perfectly healed.

Case XII.—F. D., 20 years old. For some years her hearing, in spite of treatment for the nose, as well as the ears, had been growing slowly worse. It was the result of chronic non-suppurative inflammation of both middle ears. The left was the worse,—ringing tinnitus at times in the left ear. No history of otorrhœa, but a small cicatrix was observed directly over the head of the stapes on the left side. Her hearing in the right ear was fair, and in the left ear as follows:

Ordinary voice, about 1 foot; loud voice, 4 feet; H. a. s., $\frac{2}{60}$; tuning-fork, air, 15″, through teeth in left ear; König's rods, 30,000.

Operation, June 26th, 1892. Triangular cut through the cicatrix and head of stapes separated from all attachments and the bone removed in one piece from the fenestra ovalis. No change in the pulse rate was noticed.

June 28th, complained of slight pain in the ear. Seat of operation covered with a dry clot of blood. Was somewhat dizzy on moving the head quickly. Temperature night before, one degree higher than normal. Said she

had noticed a great improvement in hearing. It was found to be as follows:

Low whispered voice, 1 foot; ordinary voice, 10 feet; loud voice, 18 feet plus.

Tuning-fork by bone heard louder in right ear; just the reverse was found before the operation; H. heard only on contact; König's, 30,000.

July 1st, still a little dizzy. Hearing the same. Ear a little tender to touch and secreting slightly a thin bloody fluid.

Ten days after the operation the hearing for the voice was found much better than when last tested. Could now hear whispered voice, 12 feet; ordinary voice, 30 feet.

Other tests about the same. No vertigo or tinnitus. July 10th, two weeks after the operation. Dry clot of blood covering seat of wound. A little tinnitus at times. Said that hearing had improved greatly since the operation. On returning home, could hear sounds of teams on the road much better than she could remember to have ever heard before. Friends and relatives all noticed great change in her hearing.

H., $\frac{c}{60}$; tuning-fork, air, 50″, bone, s. plus; whispered voice, 18 feet.

Case XIII.—A. C., 16 years old. Increasing deafness for two years. Worse in the left. Diagnosis, otitis media insidiosa.

H. a. s., $\frac{c}{60}$, lightly; tuning-fork, air, r. plus, vertex and T., s. plus; König's rods, 35,000; whispered voice, 2 feet; ordinary voice, 4 feet; loud voice, 10 feet.

Left drumhead quite transparent. Long process of incus made out with difficulty.

Operation, June 27th, 1892. Triangular opening made through the drum, long process of incus found firmly adherent to the inner wall. On being released by intro-

ducing a bent knife behind the process, it sprang outwards and backwards, probably by the action of the stapedius muscle, which, as we shall see, was a powerful one. The operation might have stopped here and been followed with marked improvement in hearing. The stapedius muscle was next separated, as was supposed, and the articulation with the incus divided. A small hook brought the stapes from the oval window, when the stapedius muscle immediately pulled it out of sight. This accident occasioned no end of trouble and portions of the bone were left in the ear, as less likely to cause subsequent trouble than further manipulations. A little dizziness was experienced after the operation, but only for a few hours.

A slight exudation was noticed for a few days. The hearing was greatly improved.

Whispered voice, 7 feet; ordinary voice, 12 feet; loud voice, 20 feet; tuning-fork by bone in the left ear; H. a. s., $\frac{c}{60}$; König's rods, 45,000.

July 5th, eight days after the operation, the hearing was as follows:

Whispered voice, 5 feet; ordinary voice, 15 feet; tuning-fork, bone, s. plus; H. $\frac{2}{60}$; König's rods, 50,000.

Case XIV.—A lady, 45 years old. She had been very deaf for twenty years, the result of otitis media insidiosa. The membrana tympani looked fairly well, though somewhat dull in color.

Whispered voice, not heard; ordinary voice, 6 inches; loud voice, 5 feet; ordinary voice, only 5 feet through large ear trumpet; tuning-fork by bone and air in the right; watch not heard in close contact; König's rods, 20,000.

Operation, June 28th, 1892. Small triangular opening made in the drum-membrane. Stapedius muscle was first divided and then the incudo-stapedial joint. A few adhesions were also separated from the head of the bone. The

stapes was removed in the usual way. Examination showed the absence of foot-plate. No attempt was made, however, to remove it, for a case already reported was in mind, where, with a portion of the foot-plate remaining, marked improvement in hearing resulted. Patient was up and dressed on the next morning, having experienced no dizziness or pain. Hearing considerably improved.

Whispered voice, 1 foot; ordinary voice, 7 feet; loud voice, 20 feet; tuning-fork, vertex, s. plus, teeth, r. plus; König's rods, 40,000; H., $\frac{0}{60}$, contact.

Says she can hear voices much clearer than before. No sign of inflammation in the ear. Nine days after the operation, the hearing was found the same as when last tested, except for tuning-fork and rods. Tuning-fork by bone was now heard alike in both ears. König's rods only 30,000. Ear perfectly dry.

Case XV.—Female. Effects of suppurative inflammation. In this case the stapes was not found. What was supposed to be the long process of the incus proved to be the displaced handle of the malleus. The end was somewhat bifurcated. The bone was freed from its attachments and removed, after which careful search with the probe failed to discover any trace of the incus or stapes. Slight dizziness was complained of for twenty-four hours.

Nine days after the operation, by careful tests the hearing was found improved six inches for the watch, and a few feet for the ordinary voice. This slight improvement was probably due to the loosening of the tissues about the round window. Slight discharge from the ear but less than three days before.

Case XVI.—Miss K. M., aged 47. She had been gradually growing more and more deaf for five years, the result of a progressive non-suppurative inflammation of both middle ears. Both drum-membranes were some-

what thin and lacked lustre. The incudo-stapedial joint seen in both ears.

In the right ear she heard loud voice only at 3 feet; watch not heard at all; tuning-fork, air, about 3″, bone, d. plus; König's rods, 30,000.

The usual operation was performed on June 30th, 1892. After removing the stapes the incus seemed to drop down from the attic and, being very loose, was removed. On the next day hearing for voice had wonderfully improved.

Whispered voice, 6 feet; ordinary voice, 19 feet; loud voice, 30 feet; tuning-fork by bone heard equally well in both ears; by air, in the right, 10″; H. d., $\frac{0}{60}$, contact; König's rods, 35,000.

No inflammatory reaction in the ear. Said she was made dizzy by lying on the right side. In a week the hearing for the voice seemed to have improved still more.

While recognizing the possibility of error in all human calculations, the results obtained in the cases whose history has been presented to you, are of such a nature as to lead me to be very hopeful of the future possibilities of this operation. Any fear of danger connected with the operation is obviated by the fact that even in the two of the above mentioned cases, where there was considerable suppuration at the time of performing the operation, there were absolutely no bad results; but, on the contrary, one of the ears healed entirely within four or five days, and the other was greatly improved. In three cases, the patients complained of vertigo after the operation, which, however, entirely disappeared within four or five days. In general, the cases showed little tendency toward inflammatory reaction, and the ears were, after a few days, entirely dry.

The effect of the operation on the hearing, as tested by the watch, in some was not marked in either way, indicating in some cases a slight gain, in others, a slight loss.

The test by König's rods met with a similar result.

In one of the above cases, a curious fact was brought to light. During the bone test with the tuning-fork, before the operation, the patient entirely failed to hear it in the worse ear; but on a repetition of the test after the operation, she heard it better in the ear operated on than in the other one.

Many of these cases were tested, both before and after the operation, by others than myself, with nearly the same results.

There still remains to be mentioned the one result of this operation, which gives it its importance and has led me to report those cases to this Society, and that is, the very marked improvement in hearing the human voice which is thereby accomplished. If persons who have heretofore heard only with difficulty can be made to hear with ease, by treatment unattended with danger, the operation as above described, which has accomplished this result, is certainly worth consideration. As to the reason why this effect is produced by the operation, I have no theory to offer, other than the simple supposition that it is by the removal of a mechanical obstruction to the sound-waves.

TABULAR VIEW.

(Tests of hearing before and after the operation.)

BEFORE.	AFTER.
CASE I.	
Moderately loud voice . . . 1 foot.	Moderately loud voice . . 25 feet.
CASE II.	
Ordinary voice . . . . . 10 feet.	Whispered voice . . . . . 8 feet.
	Ordinary " . . . . . 18 feet.
CASE III.	
Whispered voice . . . . 18 inches.	Whispered voice . . . . . 8 feet.
Ordinary " . . . . . 20 feet.	Ordinary " . . . . . 20 feet.
Watch . . . . . a. s. $\frac{4}{60}$.	Watch . . . . . a. s. $\frac{2}{60}$.
Tuning-fork, vertex . . . s. plus.	Tuning-fork, vertex . . . s. plus.
Mastoid . . . . . s. plus.	Mastoid . . . . . s. plus.
CASE IV.	
Loud voice . . . . . 15 feet.	Whispered voice . . . . . 8 feet.
Watch . . . . . a. s. $\frac{3}{60}$.	Ordinary " . . . . . 20 feet.
Tuning-fork by bone in left ear.	Watch . . . . . a. s. $\frac{10}{60}$.
König's rods . . . . . 35,000.	Tuning-fork by bone, left.
	König's rods . . . . . 40,000.
CASE V.	
Whispered voice, not heard.	Whispered voice . . . . . 2 feet.
Ordinary " . . . . . 1 foot.	Ordinary " . . . . . 9 feet.
Watch . . . . . a. d. $\frac{0}{60}$ contact.	Loud " . . . . . 20 feet.
Tuning-fork by air . . 5 seconds.	Watch . . . . . a. d. $\frac{1}{60}$.
By bone . . . . . d. plus.	König's rods 30,000
König's rods . . . . . 35,000.	

CASE VI.

Whispered voice, not heard.
Ordinary " "
Loud " . . . . . 1 foot.
Watch . . . . . a. s. $\frac{0}{60}$ contact.
Tuning-fork by air, not heard.
By bone, in the better hearing ear.

Whispered voice . . . . . 1 foot.
Ordinary " . . . . . 15 feet.
Loud " . . . 20 feet plus.
Watch . . . . . a. s. $\frac{1}{60}$.
Tuning-fork, air . . . . 2 seconds.
By bone, still in better hearing ear.

CASE VII.

Ordinary voice . . . . . 9 feet.
Watch . . . . . a. d. $\frac{\text{contact.}}{60}$
Tuning-fork by bone, right ear.
König's rods . . . . . 35,000.

Whispered voice . . . . . 4 feet.
Ordinary " . . 30 feet plus.
Watch . . . . . a. d. $\frac{8}{60}$.
Konig's rods . . . . . 40,000.

CASE VIII.

Whispered voice . . . . . 4 feet.
Ordinary " . . . . . 20 feet.
Watch . . . . . a. d. $\frac{25}{60}$.
König's rods . . . . . 35,000.

Whispered voice . . . . . 15 feet.
Ordinary " . . . 25 feet plus.
Watch . . . . . a. d. $\frac{15}{60}$
König's rods . . . . . 30,000.

CASE IX.

Whispered voice, not heard.
Ordinary " . . . . . 2 feet.
Loud " . . . . 12 feet.
Watch . . . . . a. s. $\frac{1}{60}$.

Whispered voice . . . . . 1 foot.
Ordinary " . . 25 feet plus.
Watch . . . . . a. s. $\frac{\text{contact.}}{60}$
Tuning-fork, air . . . 35 seconds.
By bone . . . . . d. plus.
König's rods . . . . . 30,000.

CASE X.

Whispered voice . . . . . 2 feet.
Ordinary " . . . . . 6 feet.
Watch . . . . . a. s. $\frac{4}{60}$.
Tuning-fork . . . . . d. plus.
König's rods 30,000

Whispered voice . . . . . 3 feet.
Ordinary " . . . . . 9 feet.
Loud " . . 25 feet plus.
Watch . . . . . a. s. $\frac{\text{contact.}}{60}$
Tuning-fork . . . . . s. plus.

CASE XI.

Hearing absolutely gone for all sounds, except for very loud voice through a conversation tube.

Whispered voice . . . . . 7 feet.
Ordinary " . . . . . 10 feet.
Loud " . . . . . 20 feet.
Watch . . . . . a. s. $\frac{\text{c lightly.}}{60}$
Tuning-fork, air . . . 15 seconds.
By bone . . . . . s. plus.
König's rods . . . . . 35,000.

CASE XII.

Ordinary voice . . . . . 1 feet.
Loud " . . . . . 4 feet.
Watch . . . . . a. s. $\frac{2}{60}$.
Tuning-fork, air . . . 15 seconds.
By bone in left ear.
König's rods . . . . . 30,000.

Loud whisper . . . . . 10 feet.
Ordinary voice . . . . . 30 feet.
Watch . . . . . $\frac{\text{contact.}}{60}$
Tuning-fork, air . . . 50 seconds.
By bone in left ear.
König's rods . . . . . 30,000.

CASE XIII.

Whispered voice . . . . . 2 feet.
Ordinary " . . . . . 4 feet.
Loud " . . . . . 10 feet.
Watch . . . . . a. s. $\frac{c}{60}$ lightly.
Tuning-fork by bone . . . s. plus.
König's rods . . . . . 35,000.

Whispered voice . . . . . 5 feet.
Ordinary " . . . . . 15 feet.
Loud " . . . . . 20 feet.
Watch . . . . . a. s. $\frac{2}{60}$.
Tuning-fork . . . . . s. plus.
König's rods . . . . . 50,000.

CASE XIV.

Whispered voice, not heard.
Ordinary " . . . . 6 inches.
Loud " . . . . . 5 feet.
Ordinary voice, only 5 feet through ear-trumpet.
Watch . . . . . a. d. $\frac{\text{O contact.}}{60}$
Tuning-fork by bone and air in the right.
König's rods 20,000

Whispered voice . . . . . 1 foot.
Ordinary " . . . . . 7 feet.
Loud " . . . . . 20 feet.
Watch . . . . . a. d. $\frac{\text{O contact.}}{60}$
Tuning-fork, vertex . . s. teeth d. plus.
König's rods . . . . . 40,000.

CASE XV.

Stapes not found.

Slight improvement in hearing.

CASE XVI.

Loud voice . . . . . 3 feet.
Watch . . . . . a. d. $\frac{\text{O contact.}}{60}$
Tuning-fork, air . . . . 3 seconds.
By bone . . . . . d. plus.
König's rods . . . . . 30,000.

Whispered voice . . . . . 6 feet.
Ordinary " . . . . 19 feet.
Loud " . . . . 30 feet.
Watch . . . . . a. d. $\frac{\text{O contact.}}{60}$
Tuning-fork, air . . . 10 seconds.
By bone, alike in both.
König's rods . . . . . 35,000.

MIDDLE EAR OPERATIONS.

By Clarence J. Blake, M. D., *Boston, Mass.*

From the time of Sir Astley Cooper's perforation of the membrana tympani, for the purpose of relieving deafness and subjective noises, and with a view to the maintenance of a permanent opening, the surgical treatment of diseases of the middle ear has had a definitely progressive history.

It is a notable fact that the first persistent efforts at surgical treatment of the middle ear, including the removal of a portion of its tissues, was made with the intention of improving the hearing, and not for the accomplishment of a purpose more directly in the line of a surgical procedure in the removal of diseased tissue consequent upon a suppurative process.

Based upon a comparatively imperfect anatomical and physiological knowledge, and dealing only with the more superficial part of the sound-transmitting apparatus, the simple myringotomy and myringectomy, as well as the trepanation of the mastoid, for the relief of deafness and subjective noises, fell into a deserved desuetude.

With an increase in the knowledge of the structure and functions of the middle ear, and with the impulse given to the investigation of this minutely interesting field for pathological research, came a better appreciation of the importance of surgical interference in cases of suppurative middle ear disease, including not only the use of means and measures for thorough cleansing and efficient drainage, but also for surgical procedures for the purpose either of removing necrotic, or even healthly, tissue, if the latter

served to retain morbid secretion or interfered with access to a diseased part.

These operations included, of necessity, the division of obstructive folds and adhesions in the middle ear, the use of the curette upon the bony walls of the tympanic cavity, the removal of the two larger ossicula, when diseased, or even when healthy if they proved obstructive, and, in addition, for the purpose of gaining better access to the fornix tympani, the removal of the upper and inner end of osseous canal. The observed cases of spontaneous evulsion of the malleus and incus, the stapes remaining in situ, and a consideration of the space occupied by the heads of these bones in that portion of the fornix tympani most subject to persistent suppurative disease, and their special liability, on account of their internal structure and nutrition, to become the seats of a necrotic process, are all in favor of their removal, under proper surgical indications. But the removal of the larger ossicula in cases of non-suppurative diseases of the middle ear and for the purpose for which Sir Astley Cooper perforated the membrana tympani, is entirely another question.

The improvement which has been effected in the cases of this kind already reported, is apparently due to two causes: namely, the relief afforded to the stapes by the removal of parts which, under conditions of disease, have come to interfere with its mobility, and, furthermore, the mobilization of the stapes itself incident to the operative interference.

Briefly put, so far as operation is concerned in suppurative disease where any interference with the ossicula is demanded, it is the removal of the incus, malleus, or malleus and incus which is generally important.

In the chronic non-suppurative disease of the middle ear, however, where surgical interference is determined upon on account of anchylosis, adhesions, general thick-

ening of the tympanic membrane, or other obstruction to the sound transmission through the ossicular chain, the removal of the malleus or incus may be considered either merely as incidental or as superfluous,—possibly, even as an unnecessary violence, since it is really the *stapes* that holds the key to the situation.

Experience in the surgical treatment of chronic suppurative disease of the middle ear, and the consequent appreciation of the extent to which the structures in that cavity may be safely interfered with, has gradually led to the consideration of the surgical invasion of this cavity in chronic non-suppurative disease, with a view to effecting an improvement in the hearing.

The surgery of the middle ear in this respect has, therefore, swung around a circle, but as all advance is in the form of a spiral, the objective point is no longer the membrana tympani, but, instead, the stapes, the termination—further end—of the sound-transmitting apparatus.

The experiments of Kessel[1], made very nearly twenty years ago and based upon carefully considered theoretical grounds, showed that the removal of the columella in birds could be effected without disturbance of co-ordination, and even where there was rupture of the basal membrane and exudation of peri-lymph, without permanent impairment of hearing, while his experiments on mobilization of the stapes in the human subject showed that considerable force could be exercised upon that bone without producing other than a temporary labyrinthine effect.

Since the first communication of Kessel, various procedures[2] for the mobilization of the stapes have been proposed and practiced, especially in cases of immobility of that ossicle as a consequence of suppurative disease of the middle ear. These have ranged from mechanical and

[1] Archiv für Ohrenheilkunde, Vol. XI., p. 199.

[2] Schwarze, Urbantschitch, Boucheron, Miot, Gellé.

auto-massage to the division of adhesions, tenotomy of the stapedius muscle, and "circumcision" of the stapes as practiced by Kessel, in the case operated upon by him in 1875.

But the question of the removal of the stapes itself has, until recently, been left out of serious consideration.

Various suggestions as to the possibility of this as a justifiable procedure have, from time to time, appeared in the literature of the subject, including mention of the accidental or intentional removal of the stapes in individual cases, but there has been no definitely planned series of clinical observations extending over a sufficient period to furnish that sound basis of conclusion by which such a question could be judged, or on which so important an addition to our means of treatment of a certain class of apparently hopeless cases could be based; and it had been my intention in continuance of previous observations to avail of the material afforded by the aural clinic of the Massachusetts Charitable Eye and Ear Infirmary during the spring term, April, May, and June of this year, for that purpose; but a temporary loss of the use of the right hand obliged me to place this, together with the greater part of the operative work of the clinic, in the very willing hands of Dr. F. L. Jack, the assistant aural surgeon then on duty, who thus had an opportunity to practically demonstrate the truth of his own previously conceived belief in the feasibility of the operation of stapedectomy on the human subject, and has performed the operation in a larger number of cases than has as yet been anywhere recorded.

These investigations by Dr. Jack were independently carried out by him and, with the addition of subsequent observation of the individual cases, will furnish a most valuable and original contribution to our practical knowledge of this subject.

The rational sequence of a definitely planned series of clinical observations, in cases where the fixation of the

stapes is the result of thickening and adhesions consequent upon suppurative disease, and where there is an existent perforation of the membrana tympani, would naturally be, firstly, separation of the stapes from the incus, if the latter bone remains in place, tenotomy of the stapedius muscle, and division of adhesions in the niche, and, as a consequent, or as a subsequent, procedure, the removal of the stapes itself.

Secondarily to this there would be the application of the same course of procedures to those cases of a high grade of deafness due to the fixation of the stapes, with or without a similar condition in the remainder of the ossicular chain, as the result of chronic *non-suppurative* disease of the middle ear.

The first step in this latter direction, historically considered, was made in the original attempt to maintain a permanent opening in the membrana tympani, which should allow the sound waves passing the obstructive portion of the ossicular chain to fall upon the base plate of the stapes and so set it in vibration.

The next step was the bolder one of Kessel's later suggestion, the success of which as a surgical procedure has been demonstrated in this country, and which included the removal, not only of the membrana tympani, but also of the two larger elements of the ossicular chain, thus, not only allowing the sound waves to fall upon the stapes directly, but also of relieving that bone of the super-incumbent weight and immobilizing effect of the larger ossicles; while the third step consists in the removal of the stapes itself.

The justifiability of this latter operation is to be premised from the fact that the stapes, situated as it is in its niche, is especially liable to be tied down by the thickening of those reduplications of the mucous membrane which are found in about eighty per cent. of normal ears

between the posterior crus of the stapes and the corresponding wall of the stapedal niche, extending usually from the tendon of the stapedius downward, and sometimes upward and forward, and from the fact that the removal of this bone, with all its possibilities of obstruction, allows the sound waves to fall directly upon a membrane which will, thus unhindered, respond more readily to sonorous vibrations; and, to the further fact, that this operation has been performed without injury and with more or less permanently good results.

Theoretically, in cases of non-suppurative disease of the middle ear with a high grade of deafness due to fixation of the sound-transmitting apparatus, and with good hearing by bone conduction, the removal of the membrana tympani and the whole of the ossicular chain would leave in the oval window a membrane in its condition more nearly corresponding, for response to vibrations, to that of the round window than would have been the case if the stapes had been left in place. Practically, this has been proven by the improvement in hearing which has followed the removal of the stapes.

My own experience in this matter includes a series of experiments in various cases, beginning with the observations having reference to diagnostic value of high musical tones[1] extending up to the present time and including operations in the following sequence: (1) Excision of the posterior segment of the membrana tympani, allowing the sound waves to fall directly upon the stapes. (2) Formation of a flap from the posterior segment of the membrana tympani and attachment of it to the descending process of the incus for the purpose of transmitting the vibrations of the membrane directly to that bone. (3) Division of the incudo-stapedal articulation through a small triangular opening in the membrana tympani. (4)

[1] Diagnostic value of high musical tones.—C. J. Blake, 1873.

Attachment of a flap from the posterior segment of the membrana tympani to the head of the stapes, the incus being either wanting or removed. (5) Division of the incudo-stapedal articulation, in cases of existing perforation of the membrana tympani, division of the stapedius muscle and of mucous folds or adhesions. (6) Removal of the stapes itself.

The one case which, perhaps, best illustrates the results of this latter procedure, because of the time which has elapsed since the operation, is that of a young man first seen in 1875, who was at that time ten years of age, and who had in both ears a suppurative process following scarlet fever.

In the right ear there was a large perforation in the posterior portion of the membrana tympani, the incus was wanting, and the stapedal niche was filled by a mass of tough granulation tissue; the hearing was much impaired, but was better for loud sounds of high pitch than for voice sounds of corresponding intensity.

The hearing for a tuning-fork (562 v. s.) was better by bone conduction than aerially. Thorough cleansing of the ear and cauterization of the granulations improved the hearing, but as the growth recurred with persistence, entire clearing of the oval niche was decided upon and effected by means of a wire snare and curved forceps; the result, in addition to the decrease of the secretion, which at this time came principally from this redundant growth,—the remaining portion of the middle ear being nearly dry,—was a marked improvement in the hearing, which increased with a subsidence of the remaining granulation tissue in the niche and has continued up to the time of the last observation of the case made, June 29, 1892, at which time the right ear was found to be perfectly dry, as it had been for several years, with an existing perforation of the membrana tympani, including the greater portion of the

posterior segment, the lower end of the malleus adherent to the inner tympanic wall, the round window free from encompassing adhesions, and the oval niche, which in this case was fortunately plainly visible, showing at its bottom the clear and shining membrane of the fenestra ovalis.

The left ear being tightly stopped, the hearing in the right ear was found to be, for the Politzer's acoumeter, 180 inches, for the tuning-fork (512 v. s.), 45/65 duration, the same fork being heard better aerially in the right ear, and better by bone conduction in the left ear, with both ears unstopped. König's rods were heard up to 40,000 v. s. in the right ear, and the voice in ordinary conversational tone at a distance of not less than fifteen feet.

Incidentally to the operation, it should be mentioned that the disturbance of the stapes was accompanied by marked but transient vertigo and a decided slowing of the pulse.

A review of the opinions expressed by the writers on this subject previously mentioned, and the results of personal experience thus far, lead to the conclusion that mobilization of the stapes, including stapedo-tenotomy and division of adhesions, are of value in cases the result of suppurative disease, where the mobility of the ossicle may be maintained either by occasional after-treatment or automatically, by making it the point of touch of an artificial membrane; and that the same procedure, surgical mobilization, is of comparatively little value in the chronic non-suppurative disease of the middle ear, either when the attempt is made to secure also a permanent opening in the membrana tympani, or to connect the stapes with the membrana tympani either by flap or cicatrix; and, therefore, of the surgical operations proposed for the improvement of hearing and the relief of tinnitus in severe cases of chronic non-suppurative diseases of the middle ear, the disarticulation and removal of the stapes, although it

seems the more heroic procedure, is one likely to be of more lasting benefit than the removal of the incus, or malleus and incus, or than merely tentative efforts at mobilization. Indeed, I should not, in the light of present experience, hesitate to recommend stapedectomy in cases where I had previously proposed dividing the articulation of the incus and stapes and division of the tendon of the stapedius muscle.

Of the operations of disarticulation and stapedo-tenotomy, or of stapedectomy itself, it may be briefly said that these vary very much in difficulty in individual cases, in reference to the position of the oval window and its relation upward or downward to the posterior-superior periphery of the membrana tympani; and that, all anatomical conditions being equal, the removal of the stapes is more easily effected in the chronic non-suppurative cases, than in those in which the fixation of the stapes is an incident of a long continued suppurative process.

The preliminaries to the operation in both the suppurative and non-suppurative cases should be the thorough cleansing of the ear with an antiseptic solution, by means of a cotton-tipped probe, syringing, especially in the latter class of cases, being avoided on account of the congestion which it causes.

The instruments, few in number, but of each of which there should be a duplicate, should be dipped in a solution of boracic acid and alcohol before using; there should be a number of cotton sticks at hand, and a weak solution of bicarbonate of soda may be provided in which to dip the instruments after using.

After the incision of the membrana tympani, which may be done according to the rule laid down by Miot, or by a triangular cut, the incudo-stapedal articulation should be divided by means of the angular knife, the principal cutting being done from behind forward, the pressure in this

direction being made against the pull of the stapedius muscle.

The tendon of the stapedius muscle may be next divided, and the straight knife used for that purpose also passed around the niche of the stapes, in order to divide any adhesions; the stapes may then be extracted either by means of the hook forceps, curved forceps, or by a blunt hook passed beneath the head of the stapes between the crura.

Traction should be made gently at first and accompanied by slight lateral movement to begin with, the bone where it comes away intact being finally lifted from its attachment with a sense of suction resistance, and usually without other evidence of reflex disturbance, if the patient is under ether, than the slowing of the pulse already mentioned and, possibly, a slight contraction of the upper extremities.

The removal of the incus in these cases is principally a question of its interference in the field of operation, its extraction being best effected after the division of the incudo-stapedal articulation and tenotomy of the stapedius muscle, by the use of the wire snare, stout curved forceps, or the hooked extractors of Ludewig, Ferrer, or some similar instrument. The removal of the incus under the conditions above mentioned is much more readily effected than when it has been preceded by the removal of the malleus, forcible extraction of the latter bone making a traction upon the fan-shaped posterior ligament of the incus which sometimes results, when the tension is relieved, in throwing the bone upward and backward into the comparatively inaccessible regions of the fornix tympani, and aditus ad antrum mastoideum.

After the operation, the field should be cleansed by means of dry absorbent cotton, and the ear tightly stopped with a cotton tampon which may be left in position for two or three days.

In the suppurative cases, the tampon should be removed within twenty-four hours after the operation, and the ear appropriately cleansed.

A consideration of the anatomy of the incudo-stapedal and stapedo-fenestral articulations shows that the operation of stapedectomy may be performed without that danger to the integrity of the labyrinth which has been so much dreaded as to prove a deterrent from the practical demonstration of its possibility; while the demonstration upon animals, and accidentally upon the human subject, of the fact that rupture of the basal fenestral membrane and outflow of peri-lymph is not of necessity fatal to the hearing, gives a still further assurance of safety.

The investigations of Rüdinger, Soemmering, Hueschke, Weber, Meckel, Eysell, Henle, and others, show in the adjustment of the base plate of the stapes in the oval window an arrangement somewhat analogous to that of the union of the malleus and the membrana tympani, the existence of a ligamentum orbiculare baseos stapedis, and of a distinct basal membrane, which conditions would permit of a direct removal of the stapes, with rupture of its superficial annular ligament, and without corresponding rupture, necessarily, of the basal membrane beneath it.

Another anatomical point of importance in this connection is the insertion of the tendon of the musculus stapedius, which, as has been shown by Rüdinger, is attached not only to the head of the stapes but also to the lenticular bone and, sometimes, also to the tip of the descending process of the incus; thus supplementing on its posterior side the capsular ligament of the incudo-stapedal articulation.

As differential diagnosis is the necessary prelude to successful surgical procedure, a definite opinion as to the value of stapedectomy can be arrived at only through the experience of a number of individual observers, and the

investigation must of necessity include further study of the stapedal articulation, both anatomically and pathologically, on the one hand, and on the other, careful record of the hearing power both immediately before and for a long time after the operation.

NOTE.

In view of information received since this paper went to press, the sentence crediting the work done should more justly read as follows: A temporary loss of the use of the right hand obliged me to place the greater part of the operative work of the Clinic in the very willing hands of Dr. F. L. Jack, the Assistant Aural Surgeon then on duty, who thus had an opportunity to practically demonstrate the feasibility of the operation of stapedectomy on the human subject in a larger number of cases than has as yet been anywhere recorded. These operations done by Dr. Jack were carried out at the suggestion of and with valuable advice from Dr. William S. Bryant, Aural Clinical Assistant, and will, with the addition of subsequent observation of the individual cases, furnish a most valuable contribution to our practical knowledge of this subject.

the required pitch. If the patient can not distinguish words, even in a loud voice, at twenty feet, I come closer. I have found, over and over again, that where the hearing was good in one ear and very bad in the other, it was

impossible to determine the degree of hearing in the very deaf ear. After I thought that I had gauged the hearing, I have told the patient to close both ears and have found the hearing to be the same as when the deaf ear was open. I have reported to the Society a case of closure of both external auditory canals. That patient was not excessively deaf. She could hear conversation carried on in a slightly elevated voice within a distance of two or three feet. This is a striking illustration of the fact that the ear may be closed in the most complete manner and yet the hearing be comparatively good.

Dr. Roosa: — I do not think that there is any department of our art, in which we are more interested at the present time than that on which we have had these interesting papers and demonstrations by Dr. Jack and Dr. Blake. When we are working in the field of mastoid operations, we are in a field where the ground has been cleared, and we are about as well established there as is the ophthalmologist in the treatment of cataract. When we come to this subject, however, we must confess that we are in the attitude of learners. That is the position which, for my part, I take. I am in an entirely receptive frame of mind. I think that any distrust or any doubt that has been expressed by any of us in regard to the feasibility, the propriety, or the success of these operations, has been due rather to the eagerness of some of their advocates in this country to assume, before it was proven, that they were entirely successful. There is not one of us but could largely increase his professional income during the coming year, if he could make himself believe that he could accomplish anything in the disease known as chronic non-suppurative progressive inflammation of the tympanum, attended with tinnitus and great loss of hearing, a disease against which so far, I think that we will all admit, our means of relief have been and continue to be so insignifi-

cant. We do not enter upon the treatment of these cases with interest, and we relinquish them with pleasure.

I think that the history of the operations of Dr. Jack is slightly defective in one respect, although I may be wrong. It was Kessel who proposed the removal of the bones for non-suppurative inflammation. It was Schwartze, not Sexton, who first advised the removal of all the bones for suppurative disease. Then came Lucae, who went over this subject of the removal of the ossicles, the malleus and incus, and sometimes the stapes, with great thoroughness. Two years ago I had the opportunity to converse with him at Berlin. I said to Prof. Lucae, "Do you perform this operation any more in these cases of non-suppurative inflammation?" He replied: "I do not. I found that the operation of removal of the bones in non-suppurative cases was not successful. So many cases were made worse and it was so difficult to make a prognosis, that I have abandoned it."

As to the removal of the bones for chronic suppuration, I do not believe that there is a surgeon here who has been sufficiently long in practice, who has not been in the habit, as early as 1871, of curetting the bones and granulations in chronic suppuration of the tympanum at times, without thinking that he was doing anything but an operation based on general surgical principles. Certainly of the good effects of this operation in a few such cases, I can emphatically testify. The criticism which I should make on the suppurative cases in which this operation has been hastily entered upon, and said to be the only operation, is that other means have not been first thoroughly tried. Every patient should have the benefit of a non-painful and non-dangerous treatment, before one which is painful and dangerous is resorted to. I think that there has never remained any question in our minds since we thought over the matter from a sound surgical standpoint, that that

operation was decidedly justifiable and occasionally indicated, but in aural disease, as all of us know, there has been a kind of fatuousness, a kind of disregard of general surgical principles, as exemplified for years in the discussions of diseases of the mastoid, which made it impossible for some men to approach this subject in an ordinary common sense way, as they would approach a surgical question relating to any other portion of the body.

Now we come to a decided change; whether an advance or not, at least a new method of treatment. We come to an operation, the simplicity of which in skillful hands has been demonstrated,—an operation which, in the opinion of the authors, promises more than other operations. As I understand the papers of Dr. Jack and Dr. Blake, I do not think that they claim that they have found, or hope to find, in this operation a remedy for these insidious cases of chronic non-suppurative inflammation to which they have given the name of *otitis media chronica insidiosa*, but in a class of cases where suppuration has put the tissues out of place, and where undue pressure has been exerted as a result of this dislocation, and where proliferation of tissue has occurred. Here I am in a perfectly receptive mood. The time is entirely too short since these operations were performed, for a determination as to their value. The tests of the hearing power in one-sided deafness are defective and more attention should be given to that. No one will welcome an advance in this direction more than will the speaker. If we can put this matter in the same position as it is even in chronic glaucoma, where we know about what we can accomplish, when we can operate and when we should not operate, otology will have made a great advance.

Dr. Dench:—I should like to cite a case met with a short time ago,—a case of chronic suppurative disease, in which the malleus and incus had been lost and the greater

part of the membrana tympani was wanting. There were also some carious spots in the tympanum and some granulation tissue and adhesions about the base of the stapes. I curetted this tympanum under ether, with the hope of removing the softened bone and establishing free drainage. The discharge had continued from childhood to the age of sixteen years. Before operation, I tested the hearing for whispered voice and the distance was eighteen or twenty inches. At the operation, I found no malleus or incus. The adhesions about the stapes were incised and then the head of the stapes was removed in the attempt to mobilize the stapes. There was considerable dizziness after the operation and the patient remained in bed for a day and a half. There was practically no disturbance aside from the dizziness. At the end of three weeks all discharge from the ear ceased, and there has been no discharge since. The operation was done two months ago. I tested the hearing two weeks ago and a low whisper was heard at the distance of eighteen feet instead of eighteen inches. I do not know what the hearing was on the other side before operation. There is one other point to which I should like to call attention, and that is an observation made two years ago by Cholewa of Berlin, that in certain cases of operation on the middle ear of one side, in patients affected with otitis media sclerosa (insidiosa), there was marked improvement of the hearing in the ear of the opposite side. In testing a number of my own cases of chronic non-suppurative inflammation of the middle ear, in which the malleus and incus had been removed by operation, I found that this was a fact. I have had my assistants test these cases also, and in a number of non-suppurative cases it was found that after operation upon the ear first affected there was improvement not only in the ear operated upon but also in the ear of the other side. What the cause of this

improvement is, I am not prepared to say. I offer it simply as a statement of fact. The operation performed upon my own cases, above referred to, was the removal of the membrana tympani, malleus, and incus, with mobilization of the stapes, and division of tense bands about the round window. These I incise with a short knife bent at a right angle.

Dr. Jack: — I have reported in my paper the results in two cases of removal of the drum-membrane, malleus, and incus. The operation for the cure of deafness, described by Dr. Sexton, not meeting with results sufficiently encouraging to continue in this direction, I determined to try the effects of such surgical interference in chronic suppurative affections of the middle ear. Very satisfactory results were obtained. Among these cases was one, in which, after removal of the drum-membrane, malleus, and incus, the head of the stapes was found carious. Its removal was followed by no unfavorable symptoms whatsoever, and the hearing for the voice, which was fair before the operation, was afterwards found slightly improved. In another case, the ear had healed, leaving the stapes in place. Hearing very poor. The operation was followed by marked improvement in hearing. In the cases reported, decided improvement was obtained in the chronic catarrh as well. The results seemed to me to justify bringing the matter before the Society.

Dr. C. E. Rider: — In cases where it is desirable to get a very precise measurement of the acuteness of hearing of one ear, the other ear being good, I suggest the use of a partition, impervious to sound and provided with a suitable opening. Against one end of this opening the ear to be examined is placed, the observer being stationed on the opposite side of the partition. In this way the direct access of the sound to the opposite ear will be pre-

vented and only bone conduction will remain as a possible source of error.

Dr. Blake: — I was glad to hear the remarks of Dr. Roosa. I think that the communication of Dr. Jack and that of myself may be regarded as the beginning of a series of investigations. The subject is new and demands full investigation. The element of time must come in, decidedly, and, more than that, we need the more definite knowledge as to the anatomy of the base of the stapes and its attachment. I think that we have entered upon quite a long course of scientific investigation and one which will interest the Society for probably several meetings to come.

Dr. Randall: — It has been surprising to me that in the discussion in regard to the excision of the drum-membrane and ossicles, I have heard so little of Gellé's test as to anchylosis of the stapes. In this test, with the tuning-fork held before the meatus, hearing is reduced either by pressure or suction conveyed by the Politzer bag or other method, to the air in the opposite meatus. He holds that anything interfering with the action of the stapes of one side will bring about spasmodic action of the stapedius of the other ear and reduce its hearing. I imagine that the silence is an evidence that the test has not proved a valuable one to those who have tried it. It has been uncertain in my own hands; but in a group of cases, I have seemed to obtain a teaching from it and an indication of the existence or non-existence of anchylosis of the stapes. This seems to me a point of crucial importance in determining whether we have before us a case with obstruction at one or other end of the chain of conducting apparatus. It gives us, if we can at all use it, an indication which we so seriously need, as to whether we should remove the drum-membrane to establish an opening through it and admit the sound waves in that way, or whether that is going to be absolutely useless, and that we must, if we do any-

thing, turn our attention to the stapes. It certainly has been to me in some cases a contra-indication to excision of the membrane, and has been an indication for an attempt to remove the stapes, — an operation which has failed, however, in my hands in those cases where it was clear from this test that this was anchylosed.

EXCISION OF MEMBRANE AND MALLEUS FOR CATARRHAL DEAFNESS, FOLLOWED BY SUPPURATION, MASTOID EMPYEMA, AND BURROWING ABSCESS OF THE NECK.

By B. Alexander Randall, M. D., *Philadelphia, Pa.*

For several years past papers have been presented in the societies and in the medical press urging the value and harmlessness of the excision of the drum-membrane and malleus for the relief of otherwise irremediable deafness from chronic catarrh and its associated symptoms of vertigo and tinnitus. The procedure is clearly rational for a considerable group of cases; its value has been shown to be very great in some instances, with the intimation that it rarely, if ever, fails to be of benefit; and but for the natural conservative inertia of profession and laity, it would be remarkable that its application has not become widespread. Doubtless it has been tried by many men in various sections, who have not seen fit to put their experiences upon record: either because isolated successes did not seem a sufficient basis for ardent advocacy, or because they have met negative or unfortunate results and did not care to hold themselves up as detractors, perhaps only to be told that, as all other workers succeeded, they had only their own bungling to thank for any failure. To many who look beyond the Atlantic for a part, at least, of their instruction, it has been very significant that a man like Lucae, who has been testing the matter nearly twenty years and in 1881 had done more of these operations than have probably yet been performed in America, is very lukewarm as to it, tries it in carefully selected cases only, and,

in spite of growing care and judgment, does not seem to be improving his results. Cases will undoubtedly occur, in the practice of each of us, where the question of such an operation will be pressed upon us, perhaps by urgent patients; and for my part I expect, as in the past, to operate in some instances, not moved to expect wonderful results by the enthusiasm of some, nor deterred from affording my patients any benefit which it may have for them, by the scepticism of others, who have never tried—perhaps not even fairly weighed—the procedure. The cases which I have thus far treated in this way are too few to be worthy of publication as throwing light upon the general question; but it seems well to report one notably unfortunate case, as did Dr. Würdeman in Detroit recently, in order that the harmlessness of the operation should not be too much relied upon by those who are putting it to the test.

Charles B. Watson, aged 19, came under my care on April 9th, 1891, complaining of growing bilateral deafness of five or more years' standing, with pain on the right at first, and constant tinnitus. Loud voice was unheard on the right, and was heard, but practically never understood, on the left. The loudly resounding A fork was barely heard on the left, probably only felt on the right. It was lateralized to the left doubtfully from the vertex, and good bone conduction was claimed on each side. Inspection showed some manubrial injection on each side, the drum-membranes depressed into contact with the congested inner walls, and the Politzer inflation, which passed more readily to the left, made no change in the appearances, in the hearing, or in the tinnitus. The right naris showed a septal spur in contact with the inferior turbinal (easily freed by shrinking the turbinal with cocaine and cauterizing), with a moderate hypertrophic condition of the naso-pharynx. A guarded, unfavorable prognosis was

given, but treatment instituted, with spraying and alteratives to the naso-pharynx, iodine vapor to the tympana, pneumatic massage, and, internally, small doses of hydrarg., bichl., and ammonii chlor. Treatment was rather occasional until January, 1892, when he was out of work and free to come daily for a week. Some relief was gained from tinnitus and vague discomforts, but deafness still remained practically total. Excision of the malleus and membrane was advised, as Gellé's test seemed to show mobility of the stapes, with the prognosis that this sole chance of gain justified the slight risk. After six weeks of hesitation he came for operation, which was done, under ether, at the Polyclinic, on February 23d. The incus-shank and stapes had not been visible, and the membrane congested badly under the etherization, which was ill-borne, so the disarticulation of the incudo-stapedial joint was not certainly accomplished as the first step, and the removal of the malleus and membrane was proceeded with. The free bleeding was then stayed and the articulation again sought, both to remove the incus and to attempt to mobilize the stapes. The stapes was still not visible and the incus could not be felt by moderate probing, having surely been displaced upward. The ear was dried and plugged with borated cotton.

No pain or reaction followed, and, as the weather was fair, he was allowed to go to his comfortable home in forty-eight hours—the hearing remaining unaffected, and the ear being clean and barely moist with blood-tinged serum. He came to my office on the two following days, apparently doing well, and not suffering at all from his hour's journey to and fro in the street cars; but on the 28th I was summoned by his brother, a medical student, who stated that he was in great pain, was coughing a little, and with a temperature of nearly 105°. I found profuse muco-purulent discharge from the ear, with some tender-

ness and swelling, little cough, and no lung symptoms, and the temperature had fallen from its morning height to about 100°. Hot syringing was instituted, with dry heat externally; and favorable progress reported by his family and by Dr. L. J. Hammond, who kindly saw him once or twice for me. There was little change during early March, when he was closely housed, and he seemed gaining when he called on the 21st and 24th; but on the 26th there was some fullness and tenderness back toward the occiput, and he wrote, on the 28th, "I am much worse. My ear pains me very much, and syringing it with hot water don't seem to do it much good. My worst trouble is in my neck; the side of my head has swelled very much and it pains me greatly. It gives me much pain when I try to eat anything, as I can hardly get my mouth open." Marked swelling was found, with some fluctuation, deeply beneath the uplifted sterno-mastoid, so he was sent to the Polyclinic Hospital again and operation done, under ether, on the 29th. Free incision was made to the bone near the back of the mastoid process, the digastric fossa freely opened and an ounce or more of thick, fetid pus evacuated from the neck abscess. Little or no burrowing backward toward the occiput was discovered. The bone sinus on the digastric surface of the mastoid was easily found and flabby granulation tissue and necrotic bone curetted away; then the gouge was applied to the lower, outward part of the mastoid process and its interior freely opened to the antrum. Irrigation had already passed freely out through the auditory canal and one syringeful of hot water so passed from the mastoid; then the fluid of another injection disappeared and the choking of the patient showed that it had entered the pharynx through some deep communication. No evidence of post-pharyngeal burrowing had been noted before, although the mouth could not be opened for very satisfactory inspection—the probe had not

revealed anything of the sort; and as the syringe employed had a long, sharp-edged canula, designed for use with the trochar, it had been used with a precaution which precluded any forcing of a passage, except by its stream of fluid. All granulations, necrotic spicules, and purulent debris were removed, the wound packed with iodoform gauze, and a dry dressing applied. His costiveness had not been overcome by the laxatives given, and on the rise of his temperature to 104° the next morning, an enema was successfully used, together with ice-cap and cold sponging of arms. Some lagging of the lids and globe of the left eye was noted immediately after the operation and facial paralysis was anticipated; but none occurred, while paresis of the oculo-motor continued for several weeks, with little change, and diplopia was at times much complained of. The fluctuating temperature continued, as shown by the chart, and he was kept in bed, with frequent dressings of the wound, until April 12th. He was allowed to go home on the 15th, with a temperature at or below normal, and all symptoms much ameliorated. Dressings were renewed every few days at his home and, later, at my office, until the end of May, when, after the removal of some spicules of the outer back part of the mastoid cortex, he was dismissed with the sinus closed, no discharge from the ear, and all pain, swelling, and tenderness gone. His hearing for loud sounds, shouted voice, or the loudly resounding tuning-fork remained the same as before excision—merely quantitive.

Two thoughts arise for explanation of this untoward result of what should, theoretically, be a simple and rather harmless operation. The acute onset of trouble may have been an influenza attack, to which, rather than to the operation, the mastoid empyema was to be ascribed. The other more probable and practical view is that the incus was displaced upward into the aditus ad antrum

and served to obstruct the outflow of the secretion from the antrum and mastoid, which, as usual in such cases, was increased decidedly by the reaction from the operation. A case of excision by my friend, Dr. L. J. Hammond, had very threatening symptoms, apparently due to the same cause, but escaped without mastoid empyema.

The teaching as to the incus in such cases may be of importance to future operators; and the advice to let it alone may have to be changed, even when its extraction proves very difficult.

DISCUSSION.

Dr. Roosa: — I should like to say that one of the reasons of the scepticism of those of us who have not practiced this operation very much, although not ignorant of it, is, that many years ago, as early as 1865, Dr. Hackley of New York removed the malleus and incus and, finally, the stapes for the relief of tinnitus, without the least benefit, even to the tinnitus, and in other cases just such other results as those that have just been narrated have followed.

I have now under my care three cases which were operated on by another practitioner, in which obstinate suppuration has followed in non-suppurative cases. This has added much to the discomfort of the patients. This is among the reasons that make us, who have seen the uselessness of a permanent opening in the drumhead, the uselessness of section of the intra-tympanic muscles, the uselessness of the eyelet, take perhaps too severe a view of the procedure which has been recommended as absolutely without harm, and which is said in the majority of instances to do a great deal of good.

Excision of the Membrana Tympani and Malleus. Mastoid Abscess burrowing into Digastric Fossa.



First chart of patient. Only in the house two days.

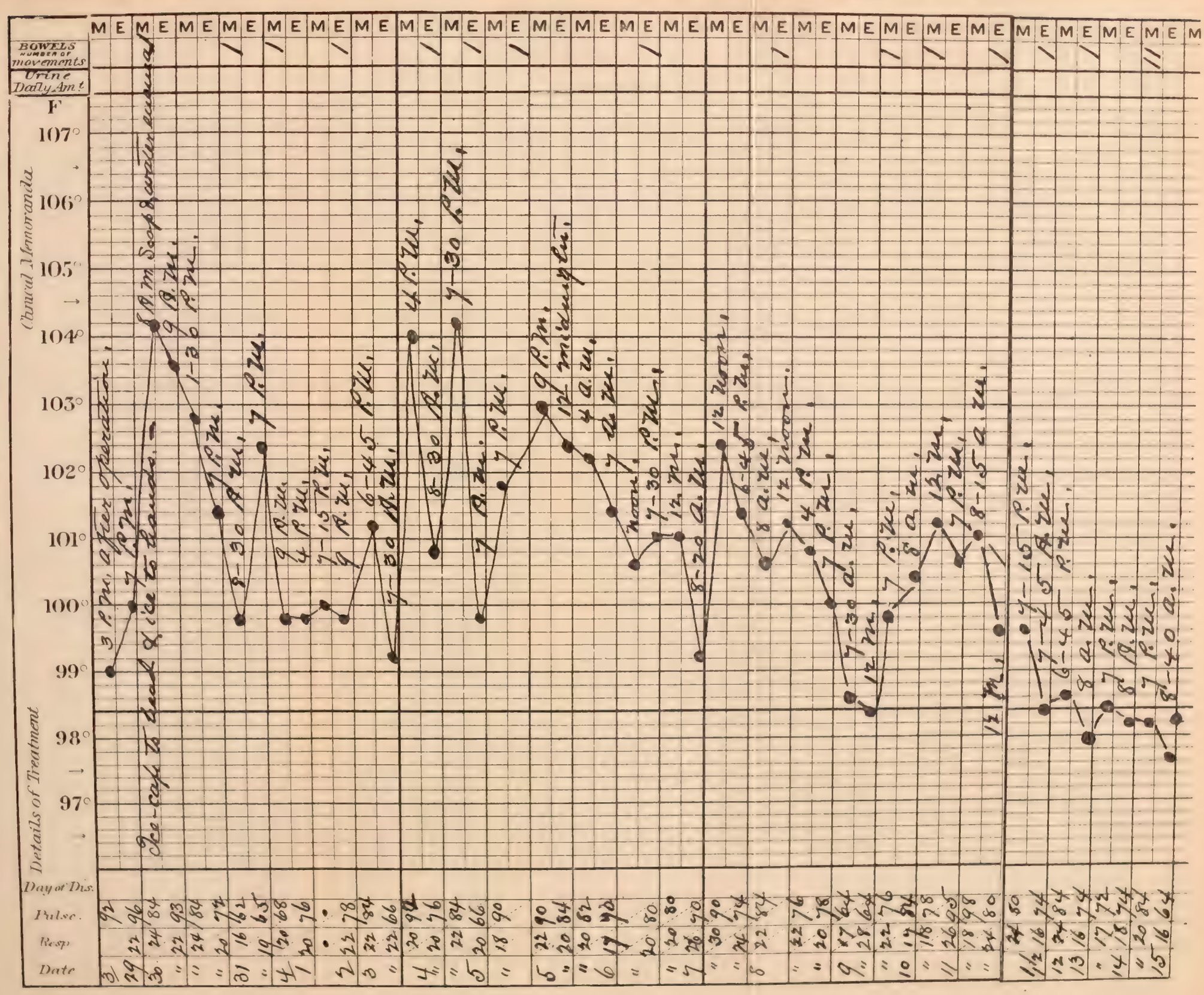
M E M E M E

A CASE OF EXOSTOSIS OF THE EXTERNAL AUDITORY CANAL. REMOVAL. CONSIDERABLE IMPROVEMENT IN THE HEARING POWER.

By D. B. St. John Roosa, M. D., LL. D., *New York.*

Mrs. M., of Huntsville, Alabama, consulted me, on April 20th, 1892, on account of a closure of the right auditory canal, and great impairment of hearing on that side. The patient was 46 years of age, with rather delicate general health. She thinks her lungs are not sound, and she states that she had a pulmonary hemorrhage sixteen years ago. She also states that she has had some trouble in her right ear, since she was 25 years of age, and that impairment of hearing has existed, on that side, for a long time, and that it is gradually increasing. She has tinnitus aurium, referred to the right ear, and, at times, pain in both ears. A year ago she had an abscess in the right ear. A tumor in the auditory canal in that side was discovered two years ago. The patient gives a very vague account of previous attacks of pain and discharge from the right ear. Her hearing distance is R $\frac{c}{40}$, L $\frac{40}{40}$. Her bone conduction is longer and louder than the aerial on the right side. The pharynx is slightly granular. On examination, the right auditory canal at the junction of the osseous and cartilaginous portion is closed, by a hard growth, evidently bony, almost hermetically. A very fine probe cannot be introduced between it and the anterior wall. It is sensitive to the touch. It was impossible for me to determine, by examination with the probe, whether this was a general filling up of the canal, or a

plate of bone stretching as a bridge or shelf across it. The patient consulted two aural surgeons besides myself, in New York, in regard to the removal of the obstruction in the canal. She had also consulted surgeons in other places and had received conflicting advice as to the necessity and propriety of an operation. Yet, according to the patient, the majority had favored removal of the growth. One authority, in consultation with me, wrote as follows:

"I am disposed to advise, in Mrs. M.'s case, that nothing be done with the bony growth until its removal, or the equivalent mastoid operation, becomes a necessity through the development of a purulent otitis media. If she were stronger, and cared very little about the annoyances attending and following such operation, I should consider the question somewhat differently."

I unhesitatingly advised an attempt at removal of the tumor. In this advise, I was strongly backed by my colleague, Dr. Emerson, of this Society. Our reasons for this were:

1. The patient was suffering considerably from the sense of fullness, tinnitus, and loss of hearing on that side.

2. An otitis media was very likely to recur, and an obstruction in the outlet of the pus would surely be dangerous and possibly fatal to her life.

I was not at all certain that the growth did not extend from the tympanum and fill up the whole canal. I informed the patient that the operation might be a tedious and difficult one, and that relief might not be all we hoped. In short, in this uncertainty as to the exact origin and size of the growth, I gave no flattering prognosis, but I stated decidedly that, in my opinion, the patient should be put under ether and an attempt at removal of the obstruction be made. The operation was desired by the patient, and it was undertaken four days after I first saw her. I was

assisted by Dr. Emerson and Dr. Frank N. Lewis. A sharp gouge and hammer were used. After division of the integument over this growth, five or six taps of the hammer on the gouge were sufficient to detach the growth from the posterior canal, when it was easily removed with a strong hook. Very slight hemorrhage followed. The obstruction was found to consist of a plate of bone, about one-twenty-fourth of an inch in thickness, fully closing the canal. I was not able, immediately after the operation, to determine whether the membrana tympani did or did not exist. The patient remained in bed two or three days. She had very little pain. The hot douche was used every three hours, until it subsided. The patient steadily improved, and on May 6th, eight days after the operation, I was able to determine that the drumhead existed, and that the canal was healed and entirely free from any obstruction. The hearing distance became $\frac{6}{40}$, and the obstructive symptoms were declared to be much alleviated.

REMARKS.

The Society may recall the writings of Blake and myself on this subject of exostosis, in which the etiology of these growths is fully discussed. Although judging from the writings of George P. Field and others, I have no such abundant opportunities to study these growths as are had in England, where bony growths in the auditory canal seem to be much more frequent, I have enough to cause me to adhere to my first opinions, that they are essentially local in origin and not particularly dependent upon any dyscrasia, such as gout or syphilis. The first process is probably a periostitis, induced by local irritation, which is intensified by want of proper antiphlogistic and cleansing treatment. This case, it seems to me, is plainly one of this character, although that there may be congenital causes I do not deny.

DISCUSSION.

Dr. Reeve:—Last year I reached the meeting too late to report one or two cases of osteoma or exostosis of the meatus. One case appeared to be especially interesting, because it seemed to furnish a special indication for operative interference not given in the text-books. The growth was of some years standing, in a young man. When quite young he had had an abscess in the ear. Rather rough attempts to remove the growth had been made and a good deal of inflammation had followed. When I saw him, the mass almost absolutely closed the meatus but a very fine probe could be passed at the anterior-superior quadrant. The growth was attached posteriorly and inferiorly and had grown anteriorly and superiorly and had pierced the integument of the anterior wall, impinging upon the periosteum, giving rise to severe pain. I did not find in the authorities to which I referred that this was laid down as an indication for operative interference. The pain was so great that the patient could not open his mouth. The growth was of ivory-like texture. In its removal I utilized what is termed a cleaver by dentists. I made an opening and then with different burrs smoothed it off. This was a year ago. Hearing at this time was bad. Now he can hear ordinary conversation at about twenty feet. The ear is still well and the meatus large.

The second case is one that bears upon a point referred to by Dr. Roosa. I considered the exostosis in this case due to transformation. The patient reported that a year before, a medical man had removed what he called a wart of the meatus. When I saw the patient, the meatus was occluded by a bony growth. In this case, by the use of a fine drill and making two or three openings, a light touch with the chisel and mallet brought it away. I found it cancellated in texture and apparently a transformation from granulation tissue.

Dr. Knapp:—I should like to say a word about the development of these exostoses. Lately I have had the opportunity to see them develop in a case of catarrhal attic disease. The patient had been affected for three months. When the inflammation had subsided so that the parts were no longer red but only slightly pinkish, then in one ear a whitish cone developed in the upper anterior fold and pointed in such a way that I thought that it was pus. In the other ear a like projection was seen, only more spherical in shape. I told the patient that if they pointed more, it would be better to open them. A week later they had grown and, as the patient had no objection, I attempted to lance them. I found that it was bony, with a thin periosteum. For three months I have watched the patient. He has neither gout nor syphilis. The affection was a simple catarrhal affection of the attic. The exostoses are symmetrically placed in Rivinii's notch, conical in shape in one ear and spherical in the other. This case suggests the idea that attic disease in its further course is essentially a periostitis.

Dr. Pomeroy:—I should like to briefly report a case of an exostosis of each meatus in a Bohemian, 40 years of age, with no previous history of ear affection of any kind. The exostosis occupied the posterior portion of the meatus of each ear very near the cartilaginous portion. Each canal was about two-thirds filled. Hearing was not lowered. The point of interest relates to their removal. In the left ear, under ether, I proceeded to remove it with the chisel. My first thought was to remove it by shaving off the bone, as in opening the mastoid, but I got a firm hold of the base and a few cautious taps cracked it off completely. It had the appearance of a split pea. In the other ear I attempted the same method but failed. I had to remove it in successive portions, using some violence. There was considerable reaction, but the patient recovered.

Here I could not raise the question of previous inflammation. I can not affirm or deny in regard to syphilis. The case is of interest from the absence of any well marked etiological factor.

Dr. Randall :—I have met a number of small exostoses which were trifling in size, chronic and apparently not progressing ; and I have also had a few cases where there was a large rapidly growing occluding mass, one or two of which I have wanted to operate on, and one of which (hyperostosis, perhaps, rather than exostosis) formed the main subject of my communication last year, where the growth figured as a factor in a fatal case of mastoid trephining. Since then I have had several cases at the university clinic, in one of which we removed a mass as large as the finger tip, attached by a small base. This was operated on by the instructor, Dr. Brown, who will report the case. I rather hampered him in the removal, for he wished to drill, but my impression was that there was very little bone between the mass and the dura mater. A light use of the chisel brought the tumor away after the base had been weakened by the drill. For my part, I am afraid of the mallet about the head in anything but the gentlest manner. I would ask those who have seen more of the use of the mallet, whether they have not met with cases of reaction or brain shock that was excessive and which might possibly be referred to the violence done the head by the chisel and mallet.

Dr. Knapp :—I can answer the question of Dr. Randall from operations on the frontal sinus. In one case where I removed, with the chisel, an exostosis larger than a walnut from the frontal sinus, there was no reaction. In other cases of exostoses of the orbit, I have seen no brain trouble. If there is suppuration, it in all probability comes from the disease itself. For instance, in diseases of the nose, polypi, sarcomata, etc., those who attempt to get them out will

find that they extend into the recesses of the cavities and can not be removed entirely and are liable to be followed by suppuration and meningitis. In mastoid disease the infection is from pathogenic germs that are there and separated from the cranial cavity only by a thin and defective bone. I do not think that anything mechanical produces the trouble and, in my opinion, the so-called shock is merely a euphonism.

Dr. Roosa:—I am glad that this subject has been reopened, as it gives me an opportunity to express views which I am sorry to say are not in unison with those generally held by otologists in this country, who have accepted Schwartze's dictum in mastoid disease as though it was the voice of infallibility.

Before I say anything on the subject, I should like to express my interest in what Dr. Knapp says in regard to the growth of exostoses in catarrhal affections of the upper part of the tympanum, and to bring to the attention of the Society a case under my observation, not of catarrh, but of suppuration where there was a hyperostosis of primary development and where the drumhead finally healed over it. I still occasionally see the patient and the case was forcibly brought to my mind when I heard Dr. Knapp's remarks.

A word or two about the chisel and the mallet. When Schwartze took up his investigations in mastoid disease, Jacoby in his own country and Agnew and myself in this country were ahead of him. Then came Buck. It has come to be held that Schwartze is the owner of the mastoid operation and that his statements are law. But I have never followed him with the chisel. I think the proper method of operating is still an open question, in spite of Dr. Knapp's case, but I do not think that one swallow makes a summer, and because his patient escaped, I do not think that every person will inevitably escape. I think

that the operation of Schwartze is bad in its inception, faulty in its carrying out, and not so good as Dixy Crosby's old gimlet operation. He was the first one in this country, and the first one since the Danish surgeon, to open the mastoid. He found a patient in New Hampshire suffering with mastoid disease, made an opening with a gimlet and got out the pus. I oppose the chisel and the mallet because it makes an unnecessarily large opening. It does not follow nature. Very often we find a fistula which we enlarge. I think that a good fistula with a funnel shaped orifice is the best opening to drain the tympanum. Another argument against the chisel is the large scar which remains. It comes to all of us to operate on young women where a scar over the mastoid is no unimportant matter. Then, it is a waste of energy. If you ever saw some general surgeon attack the mastoid, it would open your eyes to the terrible consequences that may follow. I have seen the lateral sinus unnecessarily opened, in consequence of too large an opening in the bone. A general surgeon once remarked to me that he was surprised at the good results obtained by aural surgeons in mastoid disease. Certainly we did try to avoid the lateral sinus at the first click. In spite of all that is said for the chisel I am willing to compare my cases, some one hundred twenty in number, most of which have been published, with those operated upon with the chisel. I have always used the drill, the trephine, a stiff probe, or the small gouge and spoon. Considering the size of the field of operation and the work to be done, I say with all due deference to the opinion of others, I think that the drill or trephine, or gouge and sharp spoon, is a better instrument theoretically than the chisel and hammer.

I have often thought of Dr. Randall's criticism. If tapping the head in meningitis causes pain, it stands to reason that hammering with a mallet, where there is hyperæmia

of the dura mater, may aggravate the trouble. It is a maxim in all surgery, political economy, and war, never to use any means beyond the necessity or the requirements of the case. Those who use the chisel and mallet, I think use means beyond the requirements of the case, and those which have no special advantages, but some disadvantages.

Dr. Knapp: — I want to say a word in favor of the chisel and mallet. A fine sharp chisel has decided advantages over all other ways of opening the mastoid. During the operation, you overlook your field; it leaves a clean surface; you see, as you advance, the condition of the bone, whether it is black (necrosed), red (vascular), or greenish-yellow (infiltrated with pus), compact or cancellous. You can enlarge the opening in any direction. Many clever operators, as Bergmann, use the chisel for all kinds of opening of the skull, for tumors, hemorrhage, and abscess, because they think it safer, and they can overlook their work better. Those who have used the chisel will bear me out in regard to the ease with which the little chips come off, almost without any movement of the skull. I am quite sure that the general adoption of the chisel by people who do a great deal of this work is in its favor.

Dr. Howe: — With the exception of a few operations, done perhaps ten or fourteen years ago, I have not used the chisel at all. It seems to me rather odd that it should be discussed, when we have an instrument so infinitely its superior, in the drill which the dentists have given us. I have used that a number of times. This instrument we have under perfect control and we know exactly the amount of pressure exerted. There is, to my mind, no comparison between the dentists' drill and the chisel.

REMOVAL OF THE ENTIRE AURICLE AND A PART OF THE LOBE BY THE BITE OF A HORSE.

By E. E. Holt, M. D., of *Portland, Me.*

On the 8th of June, 1892, I was asked at the telephone if an ear bitten entirely off would live if it were sewed on.

The party came into the city three hours later, and I found that a hitherto kind and gentle horse, on the preceding evening had suddenly seized the lady's ear while she was hitching him and bitten it entirely off. They supposed the horse had swallowed the ear but it was found the next morning. You will see by the ear here shown that the horse did his work well. The removal of a little cartilage and uniting the wound with interrupted sutures was all there was left to be done. The wound healed by first intention. By combing the hair a little lower than customary the disfigurement is but little noticed, and, the hearing being good, there is no noticeable loss in the function of the organ.

NOMENCLATURA MORBORUM AURIS ET NOMENCLATURA MORBORUM NASI ET NASO-PHARYNGIS.

By E. D. Spear, M. D., *Boston, Mass.*

(The following Nomenclature of Diseases of the Ear and the Naso-Pharynx, having been used at the Massachusetts Charitable Eye and Ear Infirmary in Boston, has been presented to the Society at its Annual Meeting in 1892, with request for suggestions of additions or changes, looking toward the acceptance of a general "Nomenclature" by the members of the Society.

By vote of the Society it was ordered that the Nomenclature should be printed in the Transactions of the Annual Meeting of the Society, in order to bring the subject more directly under the consideration of its members.

The Publishing Committee.)

NOMENCLATURA MORBORUM AURIS.

I. Morbi Auris Externæ:

Auriculæ — cutis:

Congestiones, activæ:

Congelatio.

Erythema.

passivæ:

Angioneurosis.

Cyanosis ex corde.

" vaso-paralytica.

" ex emphysema pulmonum.

Inflammationes:

Abscessus lobulæ.

Dermatitis congelationis.
" erysipelatosa.
" phlegmonosa.
" traumatica.
Eczema papulosum.
" pustulosum.
" rubrum.
" vesiculosum.
" squamosum :
acutum vel chronicum.
Herpes Zoster.
Intertrigo.
Lupus exulcerans.
" hypertrophica.
" vulgaris.
Fibroma lobulæ.
Fissura "
Syphilis gummosa.
" papulosa.
" pustulosa.
" squamosa.

Auriculæ — perichondrii et cartilaginis :
Inflammationes :
Hæmatoma idiopathicum.
" traumaticum.
Perichondritis.
Deformitates :
Imperfectæ :
Microtia.
Profusæ :
Polyotia.
Neoplasmata :
Angioma.
Atheroma.

Calcificatio.
Cornu.
Enchondroma.
Epithelioma.
Fibroma.
Lipoma.
Myxo-fibroma.
Ossificatio.
Sarcoma.

Meatus — cutis :
Anomaliæ secretionum :
Accumulatio ceruminis.
Diminutio ceruminis.
Inflammationes :
Eczema papulosum.
" pustulosum.
" rubrum.
" squamosum.
" vesiculosum : acutum vel chronicum.
Granulatio.
Herpes Zoster.
Syphilis ; condyloma.
" gummosa.
" ulceratio.
Otitis externa desquamativa.
" " diphtheritica.
" " diffusa :
acuta.
chronica.
" " erysipelatosa.
" " follicularis.
" " hæmorrhagica.
" " parasitica.

Contractio membranosa.
" ossea.
Corpus adventitium:
animalis.
inanimalis.
Pruritus.
Trauma:
directa.
indirecta.
Verruca.

Neoplasmata:
Cystis.
Enchondroma.
Epithelioma.
Sarcoma.
Deformitates:
Atresia acquisita.
" congenita.
Fistula auris congenita.
Meatus — ossis:
Caries.
Exostosis circumscripta.
Hyperostosis circumscripta.
" universalis.

II. Morbi Auris Mediæ:
Membranæ Tympani:
Myringitis acuta.
chronica.
Trauma directa.
indirecta:
ex fractura calvariæ.
ex ictu aërio.
ex vi opposita.

Tympani, Tubæ Eustachii et Portionis Mastoideæ:

Otitis catarrhalis secernens:
- mucosa acuta.
  - chronica.
- serosa acuta.
  - chronica:
    - ex inflammatione.
    - ex tuba.

Otitis catarrhalis adhæsiva:
- ex secernente.
- insidiosa:
  - cum morbo labyrinthi.
  - sine " "

Otitis media acuta simplex.

Otitis media suppurativa:
- acuta:
  - cum perforatione.
  - sine "
- chronica:
  - cum carie mastoidea.
  - cum " meatus.
  - cum " ossiculæ.
  - cum " tympani.
  - cum exostose meatus.
  - cum granulatione meatus.
  - cum " membranæ tympani.
  - cum " tympani.
  - cum hyperostose meatus.
  - cum " universale.
  - cum ostitide mastoidea.
  - cum periostitide "
  - cum perforatione membranæ flaccidæ.
  - cum " " tympani.
  - cum polypo tympani.
    - fibromatoso.

mucoso.
myxomatoso
cum polypo membranæ tympani.
Effectus otitidis mediæ acutæ simplicis:
cum perforatione.
Effectus otitidis mediæ suppurativæ:
cum perforatione.
cum " conglutinata.
Surditas senilis.

Neuroses Auris Mediæ:
Sensoriæ:
Otalgia dentalis.
" ex anæmia.
" ex carie calvariæ.
" ex carie vertebræ.
" ex ictu aërio.
etc.
" ex tumore cerebri.
" perineuritide.
" ex pressu nervi.
" hysterica.
" laryngealis.
" nasalis.
" pharyngealis.
Motoriæ:
Contractiones musculorum auriculæ.
" " tubæ.
" " tympani.
Vaso-motoriæ:
Congestio vaso-affecta.

III. Morbi Labyrinthi et Acustici:
Anæmia labyrinthi.
Cochlitis.

Concussio :
- ex fractura calvariæ.
- ex ictu aërio.
- ex vi opposita.

Hæmorrhagia.
Hyperæmia labyrinthi :
Labyrinthitis :
- acuta :
  - primaria.
  - secundaria.
- chronica :
  - primaria.
  - secundaria.

Morbus Acustici.
Neoplasmata in labyrintho.
Neuroses acustici :
- Hyperæsthesia.
- Paralysis :
  - angioneurotica.
  - hysterica.
  - rheumatica.

Panotitis :
- diphtheritica.
- idiopathica.
- scarlatinosa.

Propriæ notæ Ménière.
Trauma layrinthi :
- directa.
- indirecta.

NOMENCLATURA MORBORUM NASI ET NASO-PHARYNGIS.

I. Rhinitis Anterior, Posterior :
- acuta :
  - traumatica.
  - diphtheritica.
  - hæmorrhagica.
  - mucosa.
  - serosa.
  - suppurativa.
  - vaso-motoria.
- chronica :
  - serosa.
  - sicca.
  - suppurativa.
- athrophica :
  - syphilitica :
    - acquisita.
    - congenitalis.
  - tuberculosis cum carie.
  - ulcerosa scrofulosa cum carie.
- hyperplastica.
- hypertrophica :
  - cum polypo :
    - fibroso.
    - fibroso-mucoso.
    - mucoso (myxoma).
- ethmoiditis :
    - necrotica.
    - cum polypo.

Corpus adventitium :
- animalis.
- inanimalis.

Epistaxis.

Neuroses:

- anosmia.
- parosmia.

Neoplasmata:

- carcinoma.
- cystis.
- enchondroma.
- exostosis.
- fibro-sarcoma.
- granuloma:
  - simplex.
  - syphilitica.
- hyperostosis.
- lupus.
- osteo-sarcoma.
- papilloma.
- rhinoscleroma.
- sarcoma.

Septum nasi:

- abscessus.
- hæmatoma.
- inflammatio.
- scoliosis.
- ulcus perforans.

Deformitates nasi ingenitæ.

Synechiæ fossæ nasalis.

Naso-pharyngitis:

- acuta:
  - arthritica.
  - rheumatica.
  - simplex.
- chronica:
  - atrophica.
  - follicula.
  - granulosa.

hypertrophica.
sicca.

cum carcinoma.
" enchondroma.
" hyperplasia tonsillæ pharyngeæ.
" polypo:
fibro-mucoso.
fibroso.
mucoso (myxoma).
" sarcoma.

NOTICE.

The Lenval Prize.

1. **Baron Leon de Lenval** of Nice offers the sum of **3000 francs** as a **prize for the most thorough application of microphonic principles in the construction of an easily portable apparatus for the improvement of hearing.**

2. Instruments intended for competition for this prize must be sent **before December 31, 1892,** to the President of the Jury, or to Prof. Victor v. Lang, Vienna.

3. Only **fully completed** instruments will be admitted for competition, and in their examination, account will be taken of the degree of perfection in mechanical construction, the right application of physical laws, and especially of the improvement of hearing, effected by these instruments.

4. The findings of the Jury will be published, and the prize awarded at the V. International Otological **Congress, in Florence (September, 1893).**

5. Should none of the Instruments be considered worthy of the prize, the Jury reserves the right to call in 1893 for a new competition, unless Baron de Lenval should otherwise dispose of the prize.

MEMBERS OF THE JURY.

Prof. Dr. Adam Politzer, President of the Jury, Vienna.
Prof. Victor v. Lang, Vienna.
Dr. Benni, Warschau (16 Bracka).
Dr. Gellé, Paris (19 Rue Boulard).
Prof. Urban Pritchard, London.
Prof. St. John Roosa, New York.
Prof. Grazzi, Florence.

ALPHABETICAL INDEX

OF

OTOLOGICAL LITERATURE, FROM JULY 1, 1891, TO JULY 31, 1892,

COMPILED BY

GORHAM BACON, M. D., New York, N. Y.

Acal. Modifications de la voix dans les différentes maladies de l'oreille. Revist. de Sanidad militar. Madrid, Nov. 15, 1891.

Albespy. Tumeurs adenoïdes et hypertrophie des cornets ayant provoqué des phénomènes de stase sanguine cérébrale et une conjonctivite catarrhale, sans troubles auriculaires. Rev. mens de laryn., d'otol. etc. Jan. 1, 1892.

Allport, F. Some new ear instruments, with remarks on the treatment of chronic purulent inflammation of the middle ear. N. Y. Med. Record, May 28, 1892.

American Otological Society. Twenty-fourth annual meeting, held at Arlington Hotel, Washington, D. C., Sept. 22, 1891. N. Y. Med. Record, Sept. 26, 1891.

American Otological Society. Twenty-fifth annual meeting, held at New London, Conn., July 19, 1892. N. Y. Med. Record, Aug. 6, 1892.

American Otological Society. Twenty-fifth annual meeting, held at New London, Conn., July 19, 1892. Boston Med. and Surg. Journal, Sept. 15, 1892.

Artigalas et Rémond. Note sur un cas d'hémorrhagies auriculaires, oculaires et palmaires, provoquées par suggestion. Revue de l'hypnotisme, Feb. 1892.

Ayres, S. C. Primäre Periostitis des Warzenfortsatzes. Zeitschr. f. Ohrenh. Bd. 22, p. 39.

Bacon, Gorham. Notes on the use of the Leiter coil in the early stage of mastoid disease. N. Y. Med. Journal, Oct. 10, 1892.

Bacon, Gorham. Idem. Tr. Amer. Otol. Soc. New Bedford, 1891, V. pt. 1. 108–109.

Bacon, Gorham. Ueber Erkrankung des Warzenfortsatzes; mit Krankengeschichten. Zeitschr. f. Ohrenh. Bd. 22, p. 47.

Bacon, Gorham. Otitis externa hæmorrhagica. Zeitschr. f. Ohrenh. Bd. 22, p. 24.

Baginsky, A., und Gluck, Th. Ein Fall von geheiltem Schläfenlappenabscess. Berlin. Klin. Wochenschr. No. 48, 1891.

Baratoux. Guide pratique pour l'examen des maladies du larynx, du nez et des oreilles. Paris, 1892.

Barth, A., and Hartmann, A. Report on the progress of otology during the second half of the year 1890. Archives of Otology, Oct. 1891.

Barth, A., and Hartmann, A. Report on the progress of otology during the first half of the year 1891. Archives of Otology. Apr. 1892.

Barth, A., and Hartmann, A. Report on the progress of otology during the second half of the year 1891. Archives of Otology. July, 1892.

Barth, A. Bericht über die Leistungen und Fortschritte im Gebiete der normalen und pathol. Anatomie und Histol. etc., in der zweiten Hälfte des Jahres 1890. Zeitschr. f. Ohrenh. Bd. 22, p. 130.

Barth, A. Bericht über die Leistungen und Fortschritte im Gebiete der normalen u. pathol. Anatomie und Histologie, etc. in der ersten Hälfte des Jahres 1891. Zeitschr. f. Ohrenh. Bd. 22, p. 323.

Barth, A. Bericht über die Leistungen und Fortschritte im Gebiete der normalen und pathologischen Anatomie und Histologie, sowie Physiologie des Gehörorganes und Nasenrachenraumes in der zweiten Hälfte des Jahres 1891. Zeitschr. f. Ohrenh. Apr. 1892.

Barth, A. First meeting of the North German Aurists in Berlin, Apr. 22, 1889. Archives of Otology, Oct. 1891.

Barth, A. Ueber Doppelthören. Sitzungsber. d. Gesellsch. zur Beförderung d. gesammten Naturwissensch. Marburg. No. 4, 1892.

Barth, A. Report of the Sessions of the Otological Section of the Tenth International Congress at Berlin. Aug. 4–10, 1890. Archives of Otology, Oct. 1891.

Bates, W. H. A case of traumatic deafness. Recovery. N. Y. Med. Journal, Jan. 16, 1892.

Baumgarten, E. Seltene Neurosen und Reflexneurosen des Ohres, der Nase und des Rachens. Monatschr. f. Ohrenh. Sept. 1891.

Baumgarten, E. Seltene Infection des Labyrinthes, wahrscheinlich durch den Scharlach des Kindes entstanden. Gyógyàszal. No. 40, 1891.

Baumgarten, E. Eine seltene Erkrankung des Labyrinthes wahrscheinlich durch die Scharlachaffection des Kindes entstanden. Zeitschr. f. Ohrenh. Bd. 22, p. 209.

Baxter, W. E. The use of electricity in chronic affections of the middle ear, with a report of the first ten cases so treated. Archives of Otology, July, 1891.

Baxter, W. E. Fall lebender Larven im Ohr. Zeitschr. f. Ohrenh. Bd. 22, p. 120.

Beckmann, H. Ueber Schliessung und Oeffnung der Rachenmündung der Tuba Eustachii. Zeitschr. f. Ohrenh. Bd. 22, p. 83.

Bericht über die an der k. k. Wiener Universitäts-klinik für Ohrenkranken des Prof. Dr. Josef Gruber im Jahre 1890, ambulatorisch behandelten kranken. Monatschr. f. Ohrenh. June and July, 1892.

Bezold, F., and Scheibe, A. A case showing extensive destruction of the nerve in all turns of the cochlea. Archives of Otology, July, 1892.

Bezold, F., and Scheibe, A. Ein Fall von hochgradigen Nervenschwund in sämmtlichen Windungen der Schnecke. Zeitschr. f. Ohrenh. Bd. 22, p. 230.

Bezold, F. The treatment of cholesteatoma of the middle ear. Archives of Otology, Oct. 1891.

Bezold. Statistischer Bericht über die in den Jahren 1887-1889 incl. behandelten Ohrenkranken. Arch. f. Ohrenk. Bd. 33, Heft 2.

Bezold, F. Ueber operative Entfernung von Fremdkörpern aus der Pankenhöhle mit Ausschälung der den knöchernen Gehörgang auskleidenden Weichtheile und Abmeisselung des Margo tympanicus. Berlin Klin. Wochenschr. No. 36, 1891.

Bezold. Ueber das Verhalten der im Verlauf von Phthisis Pulmonum auftretenden Mittelohreiterungen unter dem Einfluss der Koch-'schen Behandlung. Deut. Arch. f. klin. Medicin, Bd. XLVII. S. 622.

Bing, A. Ein neuer Stimmgabelversuch. Wien. Med. Blaetter. No. 41, 1891.

Bing, A. Vorlesungen über Ohrenheilkunde. Wien. 1890. Verlag von W. Braumüller. Review. Monatschr. f. Ohrenh. July, 1891.

Bishop, S. S. Improved ear electrodes. Jour. Amer. Med. Assoc. Oct. 31, 1891.

Blake, C. J. Mastoid cases. Tr. Amer. Otol. Soc. New Bedford, 1891, V. pt. 1. 23–65.

Blake, C. J. Neubildung von Schleimhaut in der normalen Paukenhöhle. Zeitschr. f. Ohrenh. Bd. 22, p. 104.

Blake, C. J. Otalgia. Boston Med. and Surg. Journal, Aug. 13, 1891.

Blake, C. J. Mechanical treatment of tension anomalies. Archives of Otology, April, 1892.

Bowie, John. Influenza and ear disease in Central Africa. London Lancet, July 11, 1891.

Brésgen, M. Ueber die Verwendung von Anilinfarbstoffen bei Nasen,-Hals-und Ohrleiden. Wiesbaden, 1891.

Bresgen. Sur l'emploi des couleurs d'aniline dans les maladies du nez, de la gorge et de l'oreille. (Review.) Revue de laryn., d'otol. Apr. 15, 1892.

Bryant, W. S. Bemerkungen zur Topographie der normalen menschlichen Paukenhöhle. Zeitschr. f. Ohrenh. Bd. 22, p. 91.

Buck, A. H. A contribution to the technique of mastoid operations. N. Y. Med. Record, July 23, 1892.

Buck, A. H. Aural therapeutics: 1. Heat. Internat. Med. Magazine, March, 1892.

Bucklin, C. A. A new universal double-acting snare. Archives of Otology, Oct. 1891.

Bull, Chas. Stedman. Report on progress of otology. N. Y. Med. Journal, June 11, 1892.

Bürkner, K. Das Aristol bei Ohren- und Nasen-Krankheiten. Berlin klin. Wochens. No. 26, 1891.

Bürkner, K. Lehrbuch der Ohrenheilkunde. Mit 136 Holzschnitten. Enke in Erlangen. M. 9.

Bürkner, K. Ueber den Missbrauch des Politzer'schen Verfahrens bei der Behandlung von Ohrenkrankheiten. Berl. klin. Wochenschr. 3 Nov. 1891.

Burnett, C. H. Excision of the membrana tympani and necrotic malleus in four cases of chronic suppurative otitis media. Tr. Amer. Otol. Soc. New Bedford, 1891, V. pt. 1, 117–124.

Burnett, C. H. Excision of the membrana tympani, malleus, and incus as a means of treatment in otitis media catarrhalis chronica and in otitis media purulenta chronica. Jour. Amer. Med. Assoc. Sept. 26, 1891.

Burnett, C. H. Excision of the membrana tympani and necrotic malleus in four cases of chronic suppurative otitis media. Annals of Ophth. and Otol. Jan. 1892.

Cardoso, M. Su alcune modalità funzionàli nelle lesioni del nervo acustico. Lo Sperimentale, 1891, Fasc. V. and VI.

Cazenave, W. Fracture du crâne, Fracture oblique de la base du rocher. Otorrhagie abondante. Bull. de la Soc. Anat. de Paris, Oct.-Nov. 1891, p. 594.

Caseuave. Fracture perpendiculaire du rocher avec fracture de l'occipital du même côté, consécutive à une chute sur la partie postérieure de la tête. Séparation et mobilité du fragment interne du rocher. Bull. de la Soc. Anat. de Paris, June, July, 1891.

Charazac. Considérations sur la syphilis de l'oreille interne. Sem. Méd. 7 May, 1892.

Charazac. Considérations sur l'otite interne syphilitique. Rev. de laryn., d'otol. June 15, 1892.

Charazac. Contribution à l'étude des tumeurs malignes de l'oreille. Rev. de laryn., d'otol. etc. Jan. 1st and 15th, 1892.

Charcot, J. Coup de revolver tiré dans l'oreille. Bullet. Méd. Dec. 30, 1891.

Charcot. Vertige de Ménière. Jour. de Méd. et de Chir. prat. July 10, 1891.

Chatellier. Sur l'anatomie de l'oreille moyenne. Coupes en série. Présentation de pièces. Bull. et Mém. de la Soc. de laryn., d'otol. etc. Paris, Feb. 1892.

Cheval. Nouvelle méthode pour la recherche de la surdité dans les conseils de revision. (Review.) Revue de laryn., d'otol. etc. May 1, 1892.

Cholewa, R. Weitere Erfahrungen über Menthol bei Otitis externa furunculosa und Otitis media acuta purulenta. Monats. f. Ohrenh. March and April, 1892.

Clark, E. S. A case of injury to the ear by a stroke of lightning, with perforation of the membrana tympani. Arch. of Otology, Jan. 1892.

Clark, C. F. Verlust von Trommelfell, Hammer, Ambos und Steigbügel, mit gutem Gehör. Zeitschr. f. Ohrenh. Bd. 22, p. 41.

Cohn, M. Ueber Nystagmus bei Ohraffectionen. Berlin Klin. Wochenschr. 1891, No. 43 and 44.

Cohnstädt, E. Beitrag zur Tuberculose des Labyrinths. Monatschr. f. Ohrenh. May, 1892.

Collineau. Le sourd-muet. Tribune Méd. Dec. 17, 1891.

Compte-rendu de la Société française d'Otologie et de Laryngologie. Revue de laryn., d'otol. etc. July, 1891.

Compte-rendu de la Société française d'Otologie et de Laryngologie. Revue de laryn., d'otol. June 1, 1892.

Compte-rendu de la Société Parisienne de Laryngologie et d'Otologie. Rev. de laryn., d'otol. etc. Dec. 1 1891.

Compte-rendu de la Société Parisienne d'Otologie et de Laryngology. Rev. de laryn., d'otol. Aug. 15, 1892.

Compte-rendu de la Société Belge d'Otologie et de Laryngologie. Rev. de laryn., d'otol. July 15, 1892.

Compte-rendu de la Société d'Otologie d'Amérique. Rev. de laryn., d'otol. Jan. 1, 1892.

Compte-rendu de la 63e reúnion des médicins et naturalistes Allemands. Rev. de laryn., d'otol. etc. Aug. 1, 1891.

Compte-rendu de la 63e reúnion des médecins et naturalistes Allemands. Rev. de laryn., d'otol. etc. Jan. 15, 1892.

Compte-rendu de la 63e reúnion des médicins et naturalistes Allemands. Revue de laryn., d'otol. etc. March 1, 1892.

Condamin, R. Note sur les suppurations à pneumocoques. Lyon Méd. Feb. 7, 1892.

Corradi. La sensibilità per i toni acuti e per i toni bassi qual criterio diagnostico nelle malattie d'orecchio. Napoli, 1891.

Corradi, C. Le malattie dell'orecchio in raporto a quelle del nase ed all eredita. Il Sordomuto, Nos. 10 and 11, 1891.

Cozzolino. Contribution à la pathologie et à la chirurgie de l'apophyse mastöide. Il Sordomuto, 18, 19, 1891.

Cozzolino. Hygiene des Ohres. Ins Deutsch übertragen von Dr. Frick. Besprochen von Blau. Arch. f. Ohrenh. Bd. 33, Heft 2.

Cresswell Baber, E. A tragus retractor. Arch. of Otology, Jan. 1892.

Dabney, S. G. Ein Fall von permanenter Taubheit wahrscheinlich in Folge von Chinin. Zeitschr. f. Ohrenh. Bd. 22, p. 33.

Dalbey, J. W. Impacted cerumen invading the mastoid process and producing facial paralysis. N. Y. Med. Journal, July 18, 1892.

Davidson, H. Dermatol bei Ohrenkrankheiten. Therap. Monatshefte, Dec. 1891.

Delstanche. A propos de quelques instruments employés dans le traitement des affections de l'oreille et du nez. Bruxelles, Manceaux, édit. Paris, Georges Carré. 1885.

Dench, E. B. A head and shoulder support for use in operations upon the ear and upper air passages. N. Y. Med. Journal, July 9, 1892.

Dench, E. B. Chronic non-suppurative inflammation of the middle ear. An analysis of cases of this disease treated at the N. Y. Eye and Ear Infirmary. N. Y. Med. Journal, Sept. 26, 1892.

Dench, E. B. Two new aural instruments. Archives of Otology, April, 1892.

Dench, E. B. Some suggestions concerning the prognosis and treatment of chronic non-suppurative inflammation of the middle ear. Archives of Otology, April, 1892.

Dench, E. B. Two unusual cases of intracranial inflammation following purulent otitis media with mastoiditis. Archives of Otology, July, 1892.

Dench, E. B. Operative Massnahmen bei Schwerhörigkeit. Zeitschr. f. Ohrenh. Bd. 22, p. 110.

Dionissio. Des hémorrhagies de l'oreille. Gazz. med. di Torino, July, 1891.

Donaldson, H. H. Anatomical observations on the brain and several sense organs of the blind deaf-mute Laura Dewey Bridgman. Besprochen von H. Steinbrügge. Zeitschr. f. Ohrenh. June, 1892.

Duplay. La mastoidite suppurée. Union Méd. Feb. 1892.

Duplay. Traité de chirurgie. Oreilles et annexes. Rev. de laryn., d'otol. etc. July 15, 1891.

Eichler, O. Anatomische Untersuchungen über die Wege des Blutstromes im menschlichen Ohrlabyrinth. Abhandl. der math.-phys. Klasse der Kgl. sächs. Ges. der Wissench. Bd. XVIII. No. 5.

Eisner. Ein Beitrag zur Beurtheilung des Weber'schen und Rinne'schen Versuches in Bezug auf ihren Werth für die Diagnose der Ohrenerkrankungen. Diss. inaug. Leipzig, 1891.

Eitelberg, A. Otiatrische Mittheilungen. Wiener Med. Presse, No. 6 1892.

Ewald. Physiologische Untersuchungen über das Endorgan des Nervus octavus. Besprochen von S. Moos. Zeitschr. f. Ohrenh. June, 1892.

Ferrer, H. Ein Fall von idiopathischer Perichondritis der linken Ohrmuschel. Zeitschr. f. Ohrenh. Bd. 22, p. 30.

Ferrer, H., and Clark, E. S. Report of cases of disease of the mastoid process. Arch. of Otology, Jan. 1892.

Ferrer, H., and Clark, E. S. Report of cases of disease of the mastoid process. With remarks. Archives of Otology, April, 1892.

Ferreri, G. I medici e l'otologia. Bollet. delle Mal. dell'orecchio. No. 12, 1891.

Field. Labyrinthine deafness treated by pilocarpine. Brit. Med. Journal, Apr. 2, 1892.

Foster, M. L. Traumatic occlusion of the external auditory meatus. N. Y. Med. Journal, July 18, 1891.

Foster, M. L. Application of antisepsis in ophthalmic and aural surgery. N. Y. Med. Record, June 18, 1892.

Freund und Kayser. Ein Fall von Schreckneurose mit Gehörsanomalien. Deut. Med. Wochenschr. No. 31, 1891.

Friedenwald, H. Ein Fall von Cholesteatom und ausgedehnter Caries des Warzenfortsatzes ohne örtliche Entzündungszeichen. Tod durch Sinus-thrombose und Meningitis. Zeitschr. f. Ohren. Bd. 22, p. 121.

Gabbio. Athérome du pavillon de l'oreille. Il Sordomuto, No. 23, 1892.

Garnault. De l'application thérapeutique des sels solubles de bismuth en particulier dans les otorrhées. Bull. et mém. de la Soc. de laryn., d'otol. etc. No. 3, 1892.

Garrigo-Désarènes. Du grattage du rocher dans l'otorrhée chronique. Revue de laryn., d'otol. June 1, 1892.

Gellé. Clinique otologique annexe de la Salpêtrière, année 1890. Progrès Méd. 29 Sept. 3 and 10 Oct. 1891.

Gellé. Le signe otique dans les maladies cérébrales. Annales des mal. de l'oreille, May, 1892.

Gellé. L'audiphone appliqué au diagnostic otologique. Annales des mal. de l'oreille, July, 1892.

Gellé. Clinique otologique annexe. Le Progrès Méd. Sept. 19, 1891.

Gellé. Otite suppurée, accidents cérébraux à la suite du tamponnement postérieur dans une épistaxis grave. Annales des mal. de l'oreille, Jan. 1892.

Gifford, H. Note on the operation for reforming the auditory meatus. Archives of Otology, July, 1892.

Gilles. Présentation d'un appareil servant à faire des insufflations d'air antiseptique ou chargé de vapeurs médicamenteuses et des injections dans la caisse du tympan par la trompe d'Eustache. Bull. et mém. de la Soc. de laryn., d'otol. etc. Paris, Feb. 1892.

Gilles de la Tourette. Notes sur quelques paroxysmes hystériques peu connus: attaques à forme de névralgie faciale de vertige de Ménière. Le Progrès méd. Aug. 1, 1891.

Gomperz, B. Pathologische Histologie des Gehörorganes. Sep. Abdruck aus Weichselbaum's Grundriss der path. Anat. Wien. 1892.

Gomperz, B. Zur Frage der Regeneration der Substantia propria in Trommelfell-Narben. Monatschr. f. Ohrenh. Apr. 1892.

Goris. Sur quatre opérations pratiquées à l'Hôpital du Calvaire. Revue Internat. de Rhinol. Otol. etc. June, 1892.

Gonreau. Contribution à l'étude de la toux auriculaire. Bouchon cérumineux ayant donné lieu au faux diagnostic de tuberculose pulmonaire. Actualité Méd. Aug. 15, 1891.

Gradenigo. Ueber die Formanomalien der Ohrmuschel. Arch. f. Ohrenh. Bd. 33, Heft. 1.

Gradenigo. Des anomalies de formation du pavillon de l'oreille. Il Sordomuto, No 14, 1891.

Gradenigo, G. Ueber die Conformation der Ohrmuschel bei den Verbrecherinnen. Zeitschr. f. Ohrenh. Bd. 22, p. 179.

Gradenigo. Caractères internes cliniques offerts dans l'affection du nerf acoustique. Il Sordomuto, No. 22, 1892.

Gradenigo. A contribution to the morphology of the human auricle. Archives of Otology, July, 1891.

Gradenigo. Diagnosis, prognosis, and treatment of progressive deafness in chronic non-suppurative inflammation of the middle ear. Archives of Otology, July, 1891.

Gradenigo, J. Ueber die Classification und Aetiologie der Mittelohrentzündungen im Allgemeinen. Allg. Wien. Med. Zeitung. No. 30 and 31, 1891.

Gradle, H. On the significance of the odor of the discharge in the treatment of chronic suppurative otitis; with comments on treatment. Archives of Otology, April, 1892.

Grant, Dundas. The Eustachian self-inflator. Jour. of Laryn., Rhinol. and Otology, Jan. 1892.

Grunert. Weitere Mittheilungen über die Hammer-Ambossextraction mit besonderer Rücksickt auf die Diagnose des Ambosscaries. Arch. f. Ohrenheil. Bd. 33, Sept. 3 and 4.

Gruening, E. Notes on operations upon the mastoid process. 24th annual meeting of the Amer. Otolog. Society. N. Y. Med. Journal, Jan. 2, 1892.

Gruening, E. Idem. Tr. Amer. Otol. Soc. New Bedford, 1891, V. pt. 1, 66–69.

Gruening, E. Ueber die chirurgische Behandlung der diffusen, phlegmonösen Entzündung der Ohrmuschel. Zeitscher. f. Ohrenh. Bd. 22, p. 34.

Grünwald, L. Ueber perforirte Ohrpolypen. Zeitschr. f. Ohrenh. Bd. 22, p. 173.

Guye, A. Zwei Fälle von Bezold'scher Perforation des Antrum mastoideum. Zeitschr. f. Ohrenh. Apr. 1892.

Guye. Two cases of Bezold's perforation of the mastoid antrum. Archives of Otology, July, 1892.

Habermann. Ueber Erkrankung des Gehörorgans infolge von Tabes. Arch. f. Ohrenh. Bd. 33, Heft 2.

Hagopoff. Un cas d'oreillons. Gaz. des Hôp. Sept. 8, 1891.

Hammond, L. J. Report of six cases of excision of tympanic membrane and ossicles. Annals of Ophth. and Otol. July, 1892.

Harris, T. J. The bougie as a mode of treatment in diseases of the middle ear. Annals of Opth. and Otol. July, 1892.

Hartmann, A. Report on the progress of otology during the first half of the year 1890. Archives of Otology, July, 1891.

Hartmann, A. Bericht über die Leistungen und Fortschritte der Pathologie und Therapie im Gebiete der Krankheiten des Gehörorganes in der zweiten Hälfte des Jahres 1890. Zeitschr. f. Ohrenh. Bd. 22, p. 144.

Hartmann, A. Bericht über die Leistungen und Fortschritte der Pathologie und Therapie im Gebiete der Krankheiten des Gehörorganes in der ersten Hälfte des Jahres 1891. Zeitschr. f. Ohrenh. Bd. 22, p. 336.

Hartmann, A. Bericht über die Leistungen und Fortschritte der Pathologie und Therapie im Gebiete der Krankheiten des Gehörorganes und der Nase in der zweiten Hälfte des Jahres 1891. Zeitschr. f. Ohrenh. June, 1892.

Haug, R. Die Perichondritis tuberculosa auriculæ. Langenbeck's Archiv. Bd. XLIII. Jubil. Heft.

Haug. Beiträge zur operativen Casuistik der bei Tuberculose und Morbillen auftretenden Warzenfortsatzerkrankungen. Arch. f. Ohrenh. Bd. 33, Heft 3 and 4.

Haug. Zur mikroskopischen Anatomie der Geschwülste des aüsseren Ohres. Arch. f. Ohrenh. Bd. 33, Heft 2.

Hausberg. Beitrag zur Sinus-thrombose. Monatschr. f. Ohrenh. Jan. and Feb. 1892.

Heaton, G. Congenital malformation of the auditory apparatus. Jour. of Laryn., Rhinol. and Otology, Apr. 1892.

Hechelman, H. W. Foreign body in auditory canal for twenty years. Archives of Otology, Oct. 1891.

Hecker. L'enseignement auriculaire. Il Sordomuto, July, 1891.

Hecke. Beiträge zur Heilung der metastatischen Pyämie bei Mittelohrerkrankungen. Arch. f. Ohrenh. Bd. 33, Heft 2.

Hecke. Ueber extradurale Eiteransammlungen im Verlauf von Mittelohrerkrankungen. Arch. f. Ohrenh. Bd. 33, Heft 2.

Heiman, Th. A case of partial development of both auditory organs. Archives of Otology, Oct. 1891.

Heiman, Th. Fünf Fälle von otitischen Hirnabscessen nebst kurzer Beschreibung der otitischen Hirnabscesse im Allgemeinen. Zeitschr. f. Ohrenh. June, 1892.

Hermet, P. Leçons sur les maladies de l'oreille faites à l'hôpital des enfants malades. O. Doin, editeur. Paris, 1891.

Hessler. Ueber extradurale Abscesse nach Otitis. Arch. f. Ohrenh. Bd. 33, Heft 2.

Hessler. Affectionen des Ohrs nach einfachen Operationen in der Nase. Münchener Med. Wochenschr. No. 50, 1891.

Hertzog, M. Einige Fälle letaler Folgeerkrankungen bei Otitis media purulenta. Dis. inaug. Halle a. S. 1892.

Herzfeld. Ein neuer Catheter für die Tuba Eustachii. Monatschr. f. Ohrenh. June, 1892.

Heurtaux. Tumeur de derrière l'oreille. Gaz. méd. de Nantes, Dec. 12, 1891.

Jaenicke. Ueber die therapeutische Verwerthung der Borsaüre nebst Mittheilungen über ein neues Borpräparat. N. Therapeut. Monatshefte. Sept. 1891.

Jack, F. L. Operative treatment for the relief of chronic suppurative affections of the middle ear; report of three cases. Boston Med. and Surg. Journal, June 2, 1892.

Jacobson, L. Einige neue Apparate und Instrumente zur Galvanokaustik und elektrischen Beleuchtung. Berlin Klin. Wochenschr. 1892, No. 13.

Jacquemart. Des suppurations anciennes des oreilles. Comment on peut arriver à les guérir absolument. Revue de laryn., d'otol. etc. Feb. 15 and Mar. 1, 1892.

Jansen. Ueber otitische Hirnabscesse. Berlin Klin. Wochenschr. No. 49, 1891.

Jones, H. MacNaughton. The practitioner's handbook of diseases of the ear. 4 edit. London, 1892.

Jones & Stewart. The practitioner's handbook of diseases of the ear. 4th edition. London.

Jourdanet, L. G. Contribution a l'étude des abscès du cervelet consécutifs aux otites. Thèse de Lyon, July, 1891.

Jurka. Ueber einen Fall von Carcinom des aüsseren Gehörgangs mit tödlichem Ausgange. Inaug. Diss. Halle, 1891.

Kafemann. Ueber die Behandlung der chronischen Otorrhœ mit einigen neuen Borverbindungen. Aus der Poliklinik des Herrn Prof. Berthold. Danzig, 1891.

Kafemann. Sur le traitement de l'otorrhée chronique avec les tétraborates de soude. (Review.) Revue de laryn., d'otol. July 1, 1892.

Kaiser, O. Das Epithel der Cristae und Maculae acusticae. Arch. f. Ohrenh. Bd. 32, Heft 3 and 4.

Kanasugi, H. Klinische Beobachtungen über Eröffnung des Proc. Mastoideus. Verhandl. der phys. med. Ges. zu Würzburg. N. F. XXV. Bd. No. 5, Dissert. inaug. 1891.

Katz, L. Mikrophotographischer Atlas der normalen und pathologischen Anatomie des Ohres. Besprochen von S. Moos. Zeitschr. f. Ohrenh. June, 1892.

Katz, L. Microphotographischer Atlas der normalen und pathologischen Anatomie des Ohres. Review. Monatschr. f. Ohrenh. July, 1891.

Katz, L. Microphotographic atlas of the normal and pathological anatomy of the ear. Reviewed by S. Moos. Archives of Otology, April, 1892.

Katz, L. Bemerkungen zu dem Artikel von Bezold: Ueber operative Entfernung von Fremdkörpern aus der Paukenhöhle mit Ausschälung der den knöchernen Gehörgang auskleidenden Weichtheile und Abmeisselung des Margo tympanicus. Therap. Monatshefte. Dec. 1891.

Katzenstein. Ueber Pyoktanin bei Stirnhöhleneiterung. Therapeut. Monatshefte. Sept. 1891.

Kayser, R. Zur Technik der Knochenleitungsprüfung. Monatschr. f. Ohrenh. March, 1892.

Kayser, R. Bericht über die im Kalenderjahre 1890 in der Prof. Gottstein'schen Privatpoliklinik für Hals-, Nasen-, und Ohrenkrankheiten behandelten Krankheitsfälle. Monatschr. f. Ohrenh. July, 1891.

Kern. Simulation de la surdité d'une oreille. Bull. Méd. de Paris, Nov. 16, 1891.

Kiesselbach. Ueber die Verwerthbarkeit der Hörprüfungsmethode bei der Beurtheilung von Schwerhörigkeit infolge von Unfällen. Münch. Med. Wochenschr. No. 13, 1892.

Klingel, C. Two cases of adenoma of the sebaceous glands of the external ear. Archives of Otology, July, 1891.

Knapp, H. A case of so-called Bezold variety of mastoiditis. Opening of mastoid. Craniotomy. Death. Autopsy. Abscesses in temporal bone and cerebellum. Sinus thrombosis on the other side. Archives of Otology, July, 1892.

Knapp, H. Two cases of acute mastoid inflammation; both operated on. In one, otorrhœa and fatal meningitis. Death, as shown by autopsy, preventable. In the other, the drumhead unbroken. Perfect recovery. Tr. Amer. Otol. Soc. New Bedford, 1891, V. pt. 1. 13–42.

Knapp, H. Verknöcherung d. Ohrmuschel infolge serös-eitriger Perichondritis. Zeitschr. f. Ohrenh. Bd. 22, p. 67.

Koch, P. Quelques observations sur le mutisme hystérique. Annales des mal. de l'oreille, July, 1892.

Koehler. Un singulier corps étranger dans une oreille. Charité Annales, t. XV. p. 518.

Koehler. Furunculotom für den aüsseren Gehörgang. Monats. f. Ohrenh. March, 1892.

Körner, O. Untersuchungen über einige topographische Verhältnisse am Schläfenbein. Dritte Reihe. Zeitschr. f. Ohrenh. Bd. 22, p. 182.

Körner, O. Bericht über die constituirende Versammlung der deutschen otologischen Gesellschaft. Zeitschr. f. Ohrenh. June, 1892.

Krakauer, A. Ein Fall von multipler Exostosenbildung am Schädel mit halbseitiger Gesichtsatrophie. Monats. f. Ohrenh. Oct. 1891.

Kreidl, A. Beiträge zur Physiologie des Ohrlabyrints auf Grund von Versuchen an Taubstummen. Pfluger's Archiv. 57 Bd. Heft 1 and 2.

Krepuska, G. Ein bei der operativen Eröffnung des Warzenfortsatzes vorgekommenes seltenes Verhältniss. Monatschr. f. Ohrenh. June, 1892.

Kuhn, A. Cholesteatoma of the ear. Archives of Otology, Oct. 1891.

Lake, Richard. On the structure of aural polypi. Archives of Otology, April, 1892.

Laker. Die innere Schleimhautmassage und ihre Heilerfolge bei den chronischen Erkrankungen der Nase, des Rachens, des Ohres und des Kehlkopfes. Prager Med. Wochenschr. Nos. 5–9, 1892.

Laker. Die Heilerfolge der inneren Schleimhautmassage bei den chronischen Erkrankungen der Nase, des Rachens, des Ohres und des Kehlkopfes. Besprochen von Blau. Arch. f. Ohrenh. Bd. 33, Heft 3 and 4.

Lamann, W. Die Glühlampe und das Einschalten des Widerstandes bei Benutzung der Accumulatoren. Monatschr. f. Ohrenh. Nov. 1891.

Lane, W. Arbuthnot. Antrectomy as a treatment for chronic purulent otitis media. Archives of Otology, April, 1892.

Lannois. Sur une cause d'erreur possible dans l'épreuve de Valsalva. Rev. de laryn., d'otol. May 15, 1892.

Lannois, M. Complications auriculaires au cours de la leucocythémie. Annales des mal. de l'oreille, Jan. 1892.

Laurenti. Contribution clinique a l'étude des complications cérébrales de l'otite moyenne. Gazz. degli Ospitali. No. 52, 1892.

Lépine. Mutisme hystérique avec agraphie. Revue de Médecine, Oct. 10, 1891.

Lichtenberg. Collapsus de la membrane du tympan. Rev. de laryn., d'otol. etc. Oct. 15, 1891.

Lichtenberg. Un cas d'ostéome de la portion cartilagineuse du conduit auditif externe. Revue de laryngol. Oct. 1, 1891.

Lichtenberg, Kornel. Ueber Gehörsstörungen des Betriebspersonals der Eisenbahnen, mit Bezug auf die Sicherheit des reisenden Publikums. Monatschr. f. Ohrenh. Nov. and Dec. 1891.

Lœwenberg, B. Influenza-otitis in 1891. Tr. Amer. Otol. Soc. New Bedford, 1891, V. pt. 1. 70–83.

Lœwenberg. L'otite grippale observée à Paris en 1891. Annales des mal. de l'oreille. Nov. 1891.

Lœwenberg. D'une forme particulière de vertige auriculaire. Bull. Méd. 26 and 30 August, 1891.

Lubet-Barbon. Technique rhino-otologique: de l'anesthésie générale par le bromure d'éthyle et de ses applications. Arch. Internat. de Laryn. etc. Jan.–Feb. 1892.

Maggiora, A., and Gradenigo, G. Observations bactériologiques sur les furoncles du conduit auditif externe. Giornale della R. Accademia di Medicina di Torino. July, Aug. 1891.

Maloney, J. A. Otacoustic treatment in chronic deafness. Annals of Ophth. and Otol. Jan. 1892.

Manificat, L. Des complications auriculaires au cours de la leucocythémie. Thèse de Lyon, Nov. 1891.

Marais. Traumatisme de l'oreille et rupture du tympan. Rev. gén. de clin. et thérap. Feb. 3, 1892.

Martha. Note sur deux cas d'otite moyenne purulente contenant le bacille pyocyanique à l'état de pureté. Arch. de méd. expér. et d'anat. pathol. June 1, 1892.

Masini. Sur l'union du manche du marteau avec la membrane du tympan. Il Sordomuto, No. 23, 1892.

Max, E. Kritische Bemerkungen über die Anwendung des Natrium tetraboricum bei chronischen Ohreneiterungen. Internat. Klin. Rundschau, Nos. 2 and 3, 1892.

McBride. Diseases of the throat, nose, and ear. London, 1891.

McMahon, J. B. Zwei Fälle von Perichondritis der Ohrmuschel, behandelt mit dem scharfen Löffel und Drainage. Zeitschr. f. Ohrenh. Bd. 22, p. 28.

Ménière, E. Observation d'un corps étranger de l'oreille. Arch. Internat. de Laryn. etc. July, Aug. 1892.

Merian. Bericht über die in den Jahren 1887–1890 behandelten Ohrenkranken. Arch. f. Ohrenh. Bd. 33, Heft. 2.

Mills, C. K. Le centre de la perception auditive des mots. Brain. Jan. 1892. Revue Gén. de Méd. de Chirurg. Mar. 2, 1892.

Miot. De la surdité déterminée par le tympan ou les osselets dans l'otite moyenne sèche et des moyens d'y remédier. Rev. Mens. de laryn., d'otol. etc. Aug. 1, 15, and Sept. 1, 1891.

Moll. Trépanation de l'apophyse mastoïde. Rev. de laryn., d'otol. July 15, 1892.

Mongardi, R. Contributo alla cura del morbo di Ménière. Boll. delle mal. dell'orecchio. No. 2, 1892.

Moos, S. Weitere Untersuchungen über Labyrinthbefunde von sechs Felsenbeinen an Diphtherie verstorbener Kinder. Zeitschr. f. Ohrenh. Bd. 22, p. 72.

Moos, S. Further examinations of the labyrinth of six petrous bones from children who had died from diphtheria. Arch. of Otology, Jan. 1892.

Moos, S. Ueber die histologischen Befunde in zwei Felsenbeinen eines drei Jahre nach vollständiger Scharlachertaubung gestorbenen Mädchen. Tod durch eitrige Basilar-und Convexitätsmeningitis. Zeitschr. f. Ohrenheilkunde, Apr. 1892.

Moos, S. Ueber einige durch Bacterieneinwanderung bedingte Veränderungen im menschlichen Gehörorgan, insbesondere im Labyrinth. Virchow's Archiv. Bd. 124, Heft 3.

Moreau. Sur un nouveau cas d'extirpation de polype de l'oreille par torsion. Gaz. Méd. de Strasbourg, Oct. 1, 1891.

Mounier. Hygiène de l'oreille. Review. Annales des mal. de l'oreille, July, 1892.

Moure. Otite moyenne suppurée. Tribune Méd. May 5, 1892.

Moure. De l'enseignement des maladies des oreilles, du larynx et du nez en Allemagne. Jour. de méd. de Bordeaux, Aug. 2, 1891, et tirage à part. O. Doin, éditeur.

Müller. Das Absehen der Schwerhorigen. Besprochen von S. Moos. Zeitschr. f. Ohrenh. Bd. 22, p. 377.

Müller. Das Absehen der Schwerhörigen. Besprochen von Blau. Arch. f. Ohrenh. Bd. 32, Heft. 3 u. 4.

Müller. Einiges über die klinische Bedeutung bestimmter Trommelfellperforationen. Arch. f. Ohrenh. Bd. 33, Heft 2.

Mygind, Holger. Ein Fall von Taubstummheit nach Masern nebst dem Obductionsbefund. Zeitschr. f. Ohrenh. Bd. 22, p. 196.

Mygind, Holger. A case of deaf-mutism caused by measles with post-mortem examination. Archives of Otology, Oct. 1891.

Mygind, Holger. Die Taubstummen in Dänemark. Zeitschr. f. Ohrenh. Bd. 22, p. 237.

Nimier, H. Prophylaxie de la surdité. Revue générale. Gaz. hebd. de méd et chir. Dec. 5, 1891.

Nimier. Quelques remarques sur les affections de l'oreille dans l'armée et la population civile. Arch. de méd et pharmacol. milit. Nov. 1891.

Nothers, J. J. Traumatische Perforationen des Trommelfells. Zeitschr. f. Ohrenh. April, 1892.

Olivenbaum. Un moyen d'extraction des perles de verre ayant pénétré dans le conduit auditif. La Sem. méd. Aug. 26, 1891.

Ostmann. Die Bedeutung der Incisurae Santorini als Schutzvorrichtungen. Arch. f. Ohrenh. Bd. 33, Heft 3 and 4.

Panse. Jahresbericht über die Thätigkeit der Kgl. Universitäts-Ohrenklinik in Halle a. S. von 1 April 1890 bis 31 Mäi 1891. Arch. f. Ohrenheil. 33 Bd. 1 Heft.

Parant. Hématome de l'oreille et sa pathogénie. L'Union Méd. Aug. 27, 1891.

Parker, Rushton. Two cases of pyæmia following suppuration of the middle ear, treated by ligature of the internal jugular vein and cleansing out of the lateral sinus, with complete success in one of the cases. Liverpool, Jan. 1892.

Patterson. Intracranial complications of chronic otitis media. Glasgow Med. Jourual, Feb. 1891.

Pégon. Contribution à l'étude du traitement de l'otite moyenne suppurée par le salol camphré. Thèse de Paris, July, 1891.

Pépin. Thrombose des sinus de la dure-mère, consécutive à une otite moyenne purulente chronique avec carie de l'apophyse mastoïde chez un enfant de trois mois. Jour. de Méd. de Bordeaux. Dec. 13, 1891.

Politzer, A. The anatomical and histological dissection of the human ear, in the normal and diseased condition. Translated by Geo. Stone. (Review.) Archives of Otology, Jan. 1892.

Politzer, A. Die Eröffnung des Warzenfortsatzes bei acuten Mittelohrentzündungen nach Influenza. Wiener Med. Presse, Nos. 10–11, 1892.

Politzer, A. De l'ouverture de l'apophyse mastoide dans les cas d'otites moyennes aigues survenant à la suite de l'influenza. Annales des mal. de l'oreille, May, 1892.

Politzer, A. Stimmgabelversuch zur Konstatirung der Wegsamkeit der Ohrtrompete. Wiener Med. Wochenschrift, June 25, 1892.

Politzer, A. Expérience de diapason pour la constatation de la perméabilité de la trompe d'Eustache. Annales des mal. de l'oreille, March, 1892.

Polo. Trépanation du crâne et de l'apophyse mastoïde, suite d'une otitie suppurée. Rev. de laryn., d'otol. Jan. 15, 1892.

Pomeroy, O. D. On the value of tests of hearing in the diagnosis of certain ear affections. Annals of Ophth. and Otol. Apr. 1892.

Pomeroy, O. D. On some points in the pathogenesis of aural vertigo. N. Y. Med. Journal, June 20, 1891.

Pooley, Thos. R. Perichondritis auriculæ affecting both ears. With two illustrations. N. Y. Med. Record, Feb. 6, 1892.

Pritchard, Urban. Handbook of diseases of the ear, for the use of students and practitioners. (Review.) Archives of Otology, Jan. 1892.

Pritchard, Urban. Knochengeschwülste des Gehörgangs und deren Entfernung. Zeitschr. f. Ohrenh. Bd. 22, p. 114.

Pritchard, Urban. Zwei Fälle von Hirnabscess in Folge lang dauernder Otorrhoe. Operation. Heilung. Zeitschr. f. Ohrenh. Bd. 22, p. 36.

Pritchard, U. A handy form of intra-tympanic syringe. Arch. of Otology, Jan. 1892.

Rafin et Rougier. Ostéome de l'oreille. Lyon Méd. Sept. 27, 1891.

Randall, B. A. A case of suppuration, exostosis, and otitic epilepsy; mastoid trephining followed by fatal septic meningitis. Tr. Amer. Otol. Soc. New Bedford, 1891, V. pt. 1, 93–107.

Ray, J. M. Acute suppuration of the middle ear—meningitis—death—autopsy—no involvement of the temporal bone. Tr. Amer. Otol. Soc. New Bedford, 1891, V. pt. 1, 90–92.

Raymond, F., et Netter, A. Otite moyenne suppurée avec perforation de la membrane du tympan ayant amené une infection streptococcique. Bull. et Mém. de la Soc. de méd des hôp. de Paris, Feb. 11, 1892.

Reinhard. Beitrag zur Hammer-Ambossexcision. Arch. f. Ohrenh. Bd. 32, Heft 2.

Rémond, A. Note sur un cas d'hemorrhagies auriculaires, oculaires et palmaires de nature hystérique. Languedoc médical, 11 Dec. 1891.

Report of the second meeting of North German Aurists, Berlin, April 7, 1890. Translated and abridged by Dr. J. A. Spalding. Archives of Otology. Oct. 1891.

Richards, H. A concluding report of the anatomy of the elephant's ear. Tr. Amer. Otol Soc. New Bedford, 1891, V. pt. 1. 139–148.

Richardson, C. W. Excision of the membrane and ossicles in suppurative diseases of the attic. Archives of Otology, July, 1892.

Robertson. The Eustachian bougie. Jour. of Laryn., Rhinol. and Otology, Jan. 1892.

Robin, A. Complications cérébrales des otites. Médecine Moderne. 26 Nov. 1891.

Robinson, B. Some nasal, throat and aural symptoms and disorders met with in influenza. N. Y. Med. Journal, April 16, 1892.

Rohrer. Contribution à la pathologie du cholestéatome de l'oreille. Revue de laryn., d'otol. etc. April 1, 1892.

Rohrer, F. Text book on otology. Review by A. Barth. Archives of Otology, Apr. 1892.

Rohrer, F. Lehrbuch der Ohrenheilkunde. Besprochen von A. Barth. Zeitschr. f. Ohrenh. Bd. 22, p. 373.

Roosa, D. B. St. John. A practical treatise on the diseases of the ear. (Review.) N. Y. Med. Journal, Feb. 13, 1892.

Rougier. Polype osseux du conduit auditif externe. Bull. Méd. et Administr. Sept. 1891.

Rupp, A. On syphilis of the external ear. Jour. of cutaneous and genito-urinary diseases. Oct. 1891.

Schäfer. Ein Versuch über die intracranielle Leitung leisester Töne von Ohr zu Ohr. Zeitschr. d. Physiol. Physiol. d. Sinnesorgane. Bd. II. S. 111.

Scheibe. Ueber die Influenzabacillen bei Otitis media. Münch. med. Wochenschr. No. 14, 1892.

Scheibe, A. Bacteriologisches zur Otitis media bei Influenza. Centralb. f. Bacteriologie u. Parasitenkunde, Bd. VIII. No. 8, S. 225.

Scheibe, A. A case of deaf-mutism with auditory atrophy and anomalies of development in the membranous labyrinth of both ears. Arch. of Otology, Jan. 1892.

Scheibe, Arno. Zur Pathogenese der Transsudatbildung im Mittelohr bei Tubenverschluss. Zeitschr. f. Ohrenh. Apr. 1892.

Scheibe, Arno. Ueber die Erreger der Knochenerkrankung des Warzentheils bei der acuten genuinen Mittelohrentzündung, insbesondere den Diplococcus pneumoniae. Zeitschr. f. Ohrenh. Apr. 1892.

Scheibe, A. Ein Fall von Taubstummheit mit Acusticusatrophie und Bildungsanomalien im haütigen Labyrinth beiderseits. Zeitschr. f. Ohrenh. Bd. 22, p. 11.

Schwabach. Ueber Influenza Otitis. Deut. Med. Wochenschr. No. 19, 1892.

Schwabach. Ueber Gehörstörungen bei Meningitis cerebrospinalis und ihre anatomische Begründung. Zeitschr. f. klin. Medicin. Bd. XVIII. Heft 3 and 4.

Schmiegelow, E. On the perforations of the membrana flaccida Shrapnelli, with remarks on the formation of cholesteatoma. Archives of Otology, July, 1891.

Schmiegelow, E. Beiträge zur chirurgischen Behandlung der Ohrenkrankheiten. Zeitschr. f. Ohrenh. June 1, 1892.

Schneider. Ueber den Einfluss des Fiebers auf das Gehörvermögen. Diss. inaug. Bern. 1891.

Scholze. Ueber Ohrenerkrankungen nach Grippe. Militärärztl. Zeitschr. 1891. No. 39.

Schwartz, E. Ein Fall von Otitis media acuta purulenta mit Caries des Warzenfortsatzes in Folge eines cariösen Dens molaris II. Zeitschr. f. Ohrenh. June, 1892.

Sexton, S., and Duane, A. Deafness and discharge from the ear. (Review.) Archives of Otology, July, 1892.

Sexton, S. Ueber Operationen zur Verbesserung sowohl der Schwerhörigkeit, wie von Affectionen des Kopfes und der Ohren–Schwindel, veranlasst durch chronischen Catarrh des Trommelfells. Zeitschr. f. Ohrenh. June, 1892.

Sheild, A. Marmaduke. A case of sarcomatous growth in the external auditory canal. Arch. of Otology, Jan. 1892.

Sheppard, J. E. Head injuries with aural complications. Archives of Otology, July, 1892.

Siebenmann. Die Corrosions-Anatomie des knöchernen Labyrinths des menschlichen Ohres. Besprochen von Blau. Arch f. Ohrenh. Bd. 32, Heft 3 and 4.

Siebenmann, F. Hörprüfungsresultate bei reinem Tubencatarrh. Zeitschr f. Ohrenh. Bd. 22, p. 308.

Siebenmann, F. Beiträge zur functionnellen Prüfung des normalen Ohres. Zeitschr. f. Ohrenh. Bd. 22, p. 285.

Siebenmann, F. Die Metallcorrosion Semper'schen Trockenpräparate des Ohres. Anat. Hefte von Merkel u. Bonnet. Heft 3, 1892.

Siebenmann, F. Das Cholesteatom des Mittelohres und seine Behandlung. Correspond. f. Schweizer Aerzte. Oct. 1, 1891.

Sitzungsprotokoll der Abtheilung für Ohrenheilkunde auf der 64 Versammlung deutscher Naturforscher und Aerzte zu Halle a. S. 21–25 September 1891. Archiv. f. Ohrenh. Bd. 33, Heft 2.

Smith, S. MacCuen. Traumatic hæmorrhage of the tympanum causing deafness with subsequent restoration of hearing with report of cases. Annals of Ophth. and Otol. Jan. 1892.

Société Française d'Otologie et de Laryngologie. Séances des 4 et 5 Mai 1891. Annales des mal. de l'oreille, July, 1891.

Société Française d'Otologie et de Laryngologie. Session des 2, 3 et 4 Mai 1892. Le Progrès Méd. 14 May, 1892.

Société Française de Laryngologie et d'Otologie. Séance Annuelle tenue à Paris du 2 au 4 Mai 1892. Revue Internat. de Rhinol., Otol. etc. May, 1892.

Société de Laryngologie, d'Otologie et de Rhinologie de Paris. Annales des mal. de l'oreille, July and September, 1891.

Société d'Otologie, de Laryngologie et de Rhinologie de Paris. Annales des mal. de l'oreille, Jan. and Feb. 1892.

Société d'Otologie, de Laryngologie et de Rhinologie de Paris. Séance du 8 Jan. 1892. Annales des mal. de l'oreille, March, 1892.

Société d'Otologie, de Laryngologie et de Rhinologie de Paris. Séance du 4 mars 1892. Annales des mal. de l'oreille. May, 1892.

Société d'Otologie, de Laryngologie et de Rhinologie de Paris. Séance du 6 mai 1892. Annales des mal. de l'oreille. July, 1892.

Souls, F. Contribution à l'étude des otomycoses. Thèse de Bordeaux, 1891.

Spalding, J. A. Foreign body remaining wedged in the external auditory canal twenty-four years without injuring the hearing. Removal with a hook and syringe. Archives of Otology, July, 1891.

Spalding, J. A. Some remarks on the use of styrone in chronic suppuration of the middle ear, especially in perforation in Shrapnell's membrane. Archives of Otology, July, 1891.

Spalding, J. A. On the use of benzoinol for moistening the cotton artificial membrana tympani. Archives of Otology, July, 1891.

Spalding, J. A. On the connection between diseases of the nose and naso-pharynx and some diseases of the eye and ear. Archives of Otology, July, 1892.

Spalding, J. A. Three cases of epithelioma of the auricle. Archives of Otology, July, 1892.

Spear, E. D. A new aural forceps. Tr. Amer. Otol. Soc. New Bedford, 1891, V. pt. 1, 149–150.

Sperber, R. Ueber Fremdkörper im Ohr. Dissert. inaug. Halle a. S. 1891.

Spratling, W. P. Aural hallucinations cured by removal of foreign bodies from the ear. N. Y. Med. Record, June 3, 1891.

Steinbrügge. The pathological anatomy of the hearing organ. Archives of Otology. Oct. 1891.

Steinbrügge, H. Die pathologische Anatomie des Gehörorganes. Besprochen von A. Kuhn. Zeitschr. f. Ohrenh. Bd. 22, p. 168.

Steinbrügge, H. Ein Fall von Zerstörung und theilweiser Verknöcherung beider Labyrinthe, muthmasslich in Folge einer Meningitis. Zeitschr. f Ohrenh. Bd. 22, p. 192.

Steinbrügge, H. A case of destruction and partial ossification of both labyrinths, probably in consequence of meningitis. Archives of Otology, July, 1892.

Suchannek, H. Differentialdiagnostische Merkmale zur Unterscheidung zwischen normalem und pathologischem menschlichen Riechepithel, resp. respiratorischem Flimmerepithel. Zeitschr. f. Ohrenh. Bd. 22, p. 4.

Suchannek, H. Differential diagnostic points between human olfactory epithelium and respiratory ciliated epithelium. Archives of Otology, Oct. 1891.

Suchannek, H. Praktischer Handgriff bei Verwendung des Kabierske'schen Pulverbläsers, sowie des Tröltsch'schen Zerstaübungs apparats. Zeitschr. f. Ohrenh. Bd. 22, p. 205.

Suñé y Molist, Tympan artificial de collodion. Revist. de Laring., Otol. etc. Aug. 1891.

Suñé y Molist. Symptômes auriculaires dans la neurasthénie. Revist. Laring. Otol. etc. Sept. 1891.

Swain, H. L. Vesicles in the external auditory meatus. Archives of Otology, July, 1891.

Swinburne, R. E. The relation of aural and nasal affections based on one thousand cases of otitis media. N. Y. Med. Record, Aug. 6, 1892.

Szenes, S. Bericht über die Verhandlungen der Abtheilung für Ohrenheilkunde der 64 Versammlung der Gesellschaft deutscher Naturförscher und Aerzte in Halle a. S. 1891. Monatschr. f. Ohrenh. Nov. and Dec. 1891.

Szenes, S. Bericht über die Verhandlungen der Abtheilung für Ohrenheilkunde der 64 Versammlung der Gesellschaft deutscher Naturförscher und Aerzte in Halle a. S. 1891. Monats. f. Ohrenh. Jan. 1892.

Szenes, S. Bericht über die Verhandlungen der ersten Versammlung der deutschen Otologischen Gesellschaft. Zu Frankfurt a. M. 1892. Monats. f. Ohrenh. July, 1892.

Szenes, S. Bericht über die erste Versammlung der deutschen Otologischen Gesellschaft. (17 u. 18 Apr. 1892.) Arch. f. Ohrenh. Bd. 33, Heft. 3 u. 4.

Szenes, S. Ueber therapeutische Ergebnisse einiger neuer ohrenärztlicher Heilmittel. Allg. Wien. med Zeitung. May 3, 1892.

Szenes, S. Ohrenärztliche Mittheilungen. Allg. Wien. Med. Zeitung, June 14, 1892.

Szenes, S. Ueber eine heilungsbefördernde Complication der acuten eitrigen Paukenhöhlenentzündung. Internat. Klin. Rundschau. No. 22, 1892.

Szenes, S. Ueber Otitis media acuta migrans. Internat. Klin. Rundschau. No. 21, 1892.

Szenes, S. Zur chirurgischen Behandlung der acuten Paukenhöhlenentzündung. Centralbl. f. d. ges. Therapie. 1891. Heft 5.

Theobald, S. An unusual form of dislocation of the malleus handle. Tr. Amer. Otol. Soc. New Bedford, 1891, V. pt. 1, 137–138.

Theobald, S. Some partially successful attempts to promote the healing of old perforations of the tympanal membrane. Tr. Amer. Otol. Soc. New Bedford, 1891, V. pt. 1, 125–133.

Toeplitz, Max. A case of primary labyrinth necrosis with facial paralysis. Archives of Otology, April, 1892.

Toeplitz, Max. Symmetrical congenital defects in the anterior pillars of the fauces. Arch. of Otology, Jan. 1892.

Trautmann. Demonstration eines kleinen transportablen Accumulators zur Galvanokaustik und Beleuchtung. Deut. militärarztliche. Zeitschr. 1891, H. 6, S. 459.

Trautmann. Die Anwendung des Jodtrichlorid bei Ohreneiterungen mittelst einer neuen aseptischen Spritze. Deut. Med. Wochenschr. No. 29, 1891.

Treitel. Ueber Diplacusis binauralis. Arch. f. Ohrenh. Bd. 32, Heft 3 and 4.

Trifiletti, A. L'otite externe chez les névropathes. Bollett. delle malat. dell'orecchio, Oct. 1891.

Troisième Réunion Annuelle des Otologistes et Laryngologistes Belges. Annales des mal. de l'oreille, July, 1892.

Trouchet. Vertige de Ménière consécutif à une fracture du crâne. Bull. Méd. 16 Aug. 1891.

Truckenbrod, C. Bericht über die otiatrische Section der 64 Versammlung der Gesellschaft deutscher Naturförscher und Aerzte in Halle a. S. von 21 bis 25 September 1891. Zeitschr. f. Ohrenh. Bd. 22, p. 316.

Truckenbrod, C. Report of the proceedings of the otological section of the 64th meeting of German Naturalists at Halle, September 21st to 25th, 1891. Archives of Otology, Apr. 1892.

Truckenbrod, C. Cerebral abscess after otitis media acuta healed after operation. Archives of Otology, Apr. 1892.

Truckenbrod, C. Operativ geheilter Hirnabscess nach Otitis med. acuta. Zeitschr. f. Ohrenh. Bd. 22, p. 212.

Tsakyroglous, M. Aus meiner Praxis. Aetiologische Momente der Ohrenkrankheiten. Monatschr. f. Ohrenh. July, 1892.

Turnbull, L. Artificial drums. Medical News, Aug. 1, 1891.

Turnbull, L. Progress of otology. Annals of Ophth. and Otol. April, 1892.

Turnbull, L. Deafness the result of the poison of syphilis; its treatment by muriate of pilocapine in acute syphilitic and labyrinthine disease of the internal ear, etc. Annals of Ophth. and Otol. Jan. 1892.

Uchermann, V. Three cases of dumbness (aphasia) without deafness, paralysis or mental debility; also a case of deaf-mutism, the result of fright, etc. Archives of Otology, Oct. 1891.

Uchermann, V. Anatomischer Befund in einem Falle von Taubstummheit nach Scharlach. Zeitschr. f. Ohrenh. Apr. 1892.

Umpfenbach. Ueber die tuberculösen Erkrankungen des Ohres. Diss. inaug. Halle, 1891.

Urbantschitsch. Ueber den Einfluss schwacher Schalleinwirkungen auf die akustische Empfindungsschwelle. Archiv. f. Ohrenk. Bd. 33, Heft 3 and 4.

Vali. Versuch der Bildung eines künstlichen Gehörgangs bei angeborenem Mangel des aüsseren Gehörgangs und beiderseitige mangelhafte Entwicklung der Ohrmuschel. Arch. of Ohrenheil. Bd. 33, Heft 1.

Variot. Un cas de malformation congénitale et un cas d'anomalie du pavillon de l'oreille chez des enfants. Gaz. méd. de Paris, Nov. 14, 1891.

Verdos Mauri. De la surdi-mutité et de son traitement. Gaz. méd. de Catalogne, July 31, 1891.

Vizerie. De l'exploration de l'appareil auditif. Thèse de Bordeaux Dec. 1891.

Wagenhaüser. Pathologische Anatomie des Gehörorgans. (Blau.) Arch. f. Ohrenh. Bd. 33, Heft 2.

Wagnier. Contribution à l'étude des rapports des tumeurs adénöides naso-pharyngiennes avec l'otite moyenne purulente chronique. Rev. de laryn., d'otol. etc. Aug. 15, 1891.

Ward, Consins. A new method of extracting foreign bodies from the ear. The Lancet, Oct. 3, 1891.

Wilson, F. M. Three cases of acute suppurative otitis with complications and one death. Tr. Amer. Otol. Soc. New Bedford, 1891, V. pt. 1, 84–89.

Wolf, Oscar. Removal of a revolver bullet from the temporal bone by the use of the chisel. Recovery with preservation of hearing. Archives of Otology, July, 1891.

Wolf, O. Ausmeisselung einer Revolverkugel aus dem Felsenbein mit Erhaltung des Gehörs. Zeitschr. f. Ohrenh. Bd. 22, p. 1.

Wroblewski. Contribution à l'étude des végétations adénoïdes. Les végétations adénoïdes chez les sourds-muets. Revue laryn., d'otol. etc. May 1, 1892.

Würdemann, H. V. Condylomata of the auditory canal. Archives of Otology, July, 1892.

Zarniko, C. Ueber den Einfluss des Tuberculins auf tuberculöse Mittelohrerkrankungen. Deut. Med. Wochenschrift, No. 44, 1891.

Zaufal, E. Zur Geschichte der operativen Behandlung der Sinusthrombose in Folge von Otitis media. Prager Med. Wochenschr. No. 3 1891.

Zimmerman, C. A case of orbital cellulitis and primary mastoiditis interna complicating influenza; opening of mastoid process: recovery. Arch. of Otology, Jan. 1892.

TRANSACTIONS

OF THE

AMERICAN OTOLOGICAL SOCIETY,

TWENTY-SIXTH ANNUAL MEETING.

FORT GRISWOLD HOUSE, NEW LONDON, CONN.,

JULY 18, 1893.

VOL. V., PART 3.

PUBLISHED BY THE SOCIETY:
MERCURY PUBLISHING COMPANY, PRINTERS,
NEW BEDFORD, MASS.
1893.

Extra copies may be had by addressing the secretary, Dr. J. J. B. Vermyne, 2 Orchard street, New Bedford, Mass., or the Mercury Publishing Company, 112 and 114 Union street, New Bedford, Mass.

CONTENTS.

Members of the American Otological Society 379
Minutes of the Twenty-Sixth Annual Meeting 382
The strongly counter-irritant effects of the usual mastoid operation. By Albert H. Buck, M. D., New York, N. Y. 387
Discussion 399
Two cases of ear disease with brain symptoms; mastoid operations in both: recovery in one, death in the other. By H. Knapp, M. D., New York, N. Y. 403
Discussion. 409
Autopsies in two cases of complicated middle ear disease. By T. Y. Sutphen, M. D., Newark, N. J. 414
Discussion. 416
A case of septic thrombosis of the lateral sinus. With autopsy. By E. Gruening, M. D., New York, N. Y. 419
Discussion. 422
Notes of two fatal cases of suppurative middle ear disease with brain complications, and operation. By Clarence J. Blake, M. D., Boston, Mass. 425
Statistics of the aural department of the Massachusetts Charitable Eye and Ear Infirmary, from April 1, to July 1, 1893, with remarks. By Clarence J. Blake, M. D., Boston, Mass. . . 429
A contribution to the brain surgery of ear disease. By Thomas R. Pooley, M. D., New York, N. Y. 439
Notes on the comparative anatomy of the ossicles. By Lucien Howe, M. D., Buffalo, N. Y. 450
Demonstration of pathological specimens. By J. Orne Green, M. D., Boston, Mass. 454
Discussion. 461
Stapedectomy and other middle ear operations. By Clarence J. Blake, M. D., Boston, Mass. 464
Further observations on removal of the stapes. By Frederick L. Jack, M. D., Boston, Mass. 474
Discussion. 485

CONTENTS.

The surgical treatment of chronic tympanic vertigo, often miscalled Ménière's disease. By Charles H. Burnett, M. D., Philadelphia, Pa. 488
On the difficulty of operation in the depth of the ear canal; with description and drawing of new instruments for surmounting it. By Robert Barclay, A. M., M. D., St. Louis 500
A case of aural reflex of unusual character due to impacted cerumen. By Samuel Theobald, M. D., Baltimore, Md. 508
Discussion. 510
The statistics of ear disease. By B. Alexander Randall, M. D., Philadelphia, Pa. 511
Discussion. 515
Alphabetical index of otological literature, from July 31, 1892, to July 31, 1893. Compiled by Gorham Bacon, M. D., New York, N. Y. 517

MEMBERS

OF THE

AMERICAN OTOLOGICAL SOCIETY.

Names of members deceased while in membership in italics.

HONORARY MEMBERS.

PROF. A. GRAHAM BELL,	1336 Nineteenth St.,	Washington, D. C.
Dr. E. H. Clarke.		
PROF. ALFRED M. MAYER,	Stevens Institute,	Hoboken, N. J.
PROF. OGDEN M. ROOD,	Columbia College,	New York, N. Y.
Dr. E. Williams.		

ACTIVE MEMBERS.

DR. FRANK W. ABBOTT,	523 Franklin St.,	Buffalo, N. Y.
DR. JOHN L. ADAMS,	17 West 45th St.,	New York, N. Y.
Dr. C. R. Agnew.		
DR. HARLAN P. ALLEN,	73 East State St.,	Columbus, O.
DR. A. ALT,	3036 Locust St.,	St. Louis, Mo.
DR. J. A. ANDREWS,	9 West 22d St.,	New York, N. Y.
DR. S. C. AYRES,	64 West 7th St.,	Cincinnati, O.
DR. GORHAM BACON,	63 West 54th St.,	New York, N. Y.
DR. BENJAMIN J. BALDWIN,	13 South Perry St.,	Montgomery, Ala.
DR. ROBERT BARCLAY,	3211 Lucas Av.,	St. Louis, Mo.
DR. EDWIN W. BARTLETT,	422 Jefferson St.,	Milwaukee, Wis.
DR. CLARENCE J. BLAKE,	226 Marlborough St.,	Boston, Mass.
DR. R. O. BORN,	163 West 34th St.,	New York, N. Y.
DR. ALBERT H. BUCK,	19 East 38th St.,	New York, N. Y.
DR. CHARLES H. BURNETT,	127 South 18th St.,	Philadelphia, Pa.
DR. FRANKLIN P. CAPRON,	203 Washington St.,	Providence, R. I.
DR. W. H. CARMALT,	87 Elm St.,	New Haven, Conn.
DR. J. ELLIOTT COLBURN,	808-812 Venetian Building,	Chicago, Ill.
DR. WM. COWEN,	35 East 60th St.,	New York, N. Y.
DR. EDW. B. DENCH,	17 West 46th St.,	New York, N. Y.

Dr. J. H. Dix.
Dr. E. Dyer.
Dr. E. P. Ely.
Dr. J. B. Emerson, . . . 20 East 30th St., ... New York, N. Y.
Dr. Edw. Fridenberg, . 2019 5th Av., ... New York, N. Y.
Dr. B. E. Fryer, U. S. A., S. W. cor. 9th and Cherry Sts., ... Kansas City, Mo.
Dr. John Green, ... 2670 Washington Av., . St. Louis, Mo.
Dr. J. Orne Green. . . . 182 Marlborough St., . . Boston, Mass.
Dr. Emil Gruening. . . 109 East 23d St., ... New York, N. Y.
Dr. G. W. Hale, ... 235½ North Summer St., Nashville, Tenn.
Dr. George C. Harlan, 1515 Walnut St., ... Philadelphia, Pa.
Dr. David Harrower, Jr., 9 Elm St., ... Worcester, Mass.
Dr. Neil J. Hepburn, . . 369 West 23d St., . . . New York, N. Y.
Dr. Edward L. Holmes, 112 South Clark St., . . Chicago, Ill.
Dr. E. E. Holt, ... 723 Congress St., . . . Portland, Me.
Dr. Wm. H. Hotchkiss, . 3813 Washington Av., . St. Louis, Mo.
Dr. Lucien Howe, . . . 183 Delaware Av., . . . Buffalo, N. Y.
Dr. Frederick L. Jack, 437 Boylston St., . . . Boston, Mass.
Dr. W. B. Johnson, . . . 170 Broadway, ... Paterson, N. J.
Dr. Samuel J. Jones. . . Montauk Bl., 115 Monroe St., Chicago, Ill.
Dr. Charles J. Kipp, . . 534 Broad St., ... Newark, N. J.
Dr. Herman Knapp, . . . 26 West 40th St., ... New York, N. Y.
Dr. J. W. Lawton.
Dr. J. A. Lippincott, . . 435 Penn Av., ... Pittsburg, Pa.
Dr. W. S. Little.
Dr. F. B. Loring, ... 1420 K St., North West, Washington, D. C.
Dr. C. J. Lundy.
Dr. Arthur Mathewson, 139 Montague St., . . . Brooklyn, N. Y.
Dr. Read J. McKay, . . N. E. cor. 9th and Market Sts., Wilmington, Del.
Dr. C. S. Merrill, . . 23 Washington Av., . . Albany, N. Y.
Dr. H. G. Miller, . . . 262 Benefit St., ... Providence, R. I.
Dr. B. L. Milliken, . . . 278 Prospect St., ... Cleveland, Ohio.
Dr. W. W. Morland.
Dr. H. L. Morse, ... 112 Marlborough St., . . Boston, Mass.
Dr. Robert C. Myles, . 25 West 36th St., ... New York, N. Y.
Dr. Henry D. Noyes, . . 233 Madison Av., ... New York, N. Y.
Dr. J. F. Noyes, ... 14 Jackson St., ... Providence, R. I.
Dr. Oren D. Pomeroy, . 316 Lexington Av., . . . New York, N. Y.
Dr. Thomas R. Pooley, . 107 Madison Av., ... New York, N. Y.
Dr. J. S. Prout, ... 26 Schermerhorn St., . . Brooklyn, N. Y.
Dr. B. Alexander Randall, 1806 Chestnut St., . . . Philadelphia, Pa.

Dr. Wm. Rankin, Jr., . . 23 Cedar St., ... Newark, N. J.
Dr. J. M. Ray, ... 414 W. Chestnut St., . . Louisville, Ky.
Dr. R. A. Reeve, ... 22 Shuter St., cor. Victoria, ... Toronto, Canada.
Dr. Huntington Richards, 19 East 38th St., ... New York, N. Y.
Dr. S. O. Richey, ... 732 Seventeenth St., . . Washington, D.C.
Dr. Charles E. Rider, . 53 South Fitzhugh St., . Rochester, N. Y.
Dr. Wheelock Rider, . 53 South Fitzhugh St., . Rochester, N. Y.
Dr. Frank W. Ring, . . 101 Park Av., ... New York, N. Y.
Dr. S. D. Risley, ... 1722 Walnut St., ... Philadelphia, Pa.
Dr. D. B. St. John Roosa, 20 East 30th St., ... New York, N. Y.
Dr. John D. Rushmore, 129 Montague St. . . . . Brooklyn, N. Y.
Dr. Wm. W. Seely, . . . S. E. cor. 4th and Broadway, Cincinnati, O.
Dr. Ralph W. Seiss, . . 213 South 17th St., . . . Philadelphia, Pa.
Dr. Samuel Sexton, . . 12 West 35th St., ... New York, N. Y.
Dr. J. B. Shapleigh, . . 2608 Locust St., ... St. Louis, Mo.
Dr. Henry L. Shaw, . . 431 Boylston St., . . . Boston, Mass.
Dr. E. D. Spear, ... 20 Mt. Vernon St., . . . Boston, Mass.
Dr. H. N. Spencer, . . . 2725 Washington Av., . St. Louis, Mo.
Dr. George T. Stevens, 33 West 33d St., ... New York, N. Y.
Dr. S. B. St. John, . . . 26 Pratt St., ... Hartford, Conn.
Dr. George Strawbridge, 1500 Walnut St., ... Philadelphia, Pa.
Dr. T. Y. Sutphen, . . . 999 Broad St., ... Newark, N. J.
Dr. J. O. Tansley, . . . 28 West 43d St., ... New York, N. Y.
Dr. Samuel Theobald, . 304 West Monument St., Baltimore, Md.
Dr. William Thomson, . 1426 Walnut St., ... Philadelphia, Pa.
Dr. Robert Tilley, . . . 125 State St., ... Chicago, Ill.
Dr. J. Vanduyn, ... 111 South Salina St., . . Syracuse, N. Y.
Dr. J. J. B. Vermyne, . 2 Orchard St., ... New Bedford, Mass.
Dr. David Webster, . . 327 Madison Av., ... New York, N. Y.
Dr. W. H. Wilmer, . . . 1330 New York Av., N. W., Washington, D. C.
Dr. F. M. Wilson, . . . 317 State St., ... Bridgeport, Conn.

American Otological Society.

The Twenty-Sixth Annual Meeting of the American Otological Society was held at the Fort Griswold House, New London, Conn., on Tuesday, July 18, 1893, at 10 A. M. The President, Dr. Gorham Bacon, of New York, N. Y., in the chair.

The following members were present:

Drs.	Gorham Bacon,	New York, N. Y.
	Clarence J. Blake,	Boston, Mass.
	Albert H. Buck,	New York, N. Y.
	W. H. Carmalt,	New Haven, Conn.
	John Green,	St. Louis, Mo.
	J. Orne Green,	Boston, Mass.
	Emil Gruening,	New York, N. Y.
	David Harrower, Jr.,	Worcester, Mass.
	E. E. Holt,	Portland, Me.
	Lucien Howe,	Buffalo, N. Y.
	Frederick L. Jack,	Boston, Mass.
	W. B. Johnson,	Paterson, N. J.
	Herman Knapp,	New York, N. Y.
	Arthur Mathewson,	Brooklyn, N, Y.
	H. G. Miller,	Providence, R. I.
	B. L. Milliken,	Cleveland, O.
	H. D. Noyes,	New York, N. Y.
	J. F. Noyes,	Providence, R. I.
	J. S. Prout,	Brooklyn, N. Y.
	B. Alex. Randall,	Philadelphia, Pa.
	Wm. Rankin, Jr.,	Newark, N. J.
	J. M. Ray,	Louisville, Ky.
	R. A. Reeve,	Toronto, Canada.

Drs. S. D. Risley, ... Philadelphia, Pa.
S. B. St. John, ... Hartford, Conn.
T. Y. Sutphen, ... Newark, N. J.
Samuel Theobald, ... Baltimore, Md.
J. J. B. Vermyne, ... New Bedford, Mass.
F. M. Wilson, ... Bridgeport, Conn.

And by invitation:

Drs. F. Baker, ... San Diego, Cal.
E. Fridenberg, ... New York, N. Y.
J. E. Sheppard, ... Brooklyn, N. Y.
F. P. Sprague, ... Providence, R. I.

The President appointed as the Business Committee, Drs. John Green, J. Orne Green, and H. G. Miller.

The Treasurer's Report was read and referred to Dr. B. A. Randall as Auditing Committee. This Committee subsequently stated the accounts to be correct and properly vouched for and the Treasurer's Report was then accepted.

A communication from the Secretary of the Executive Committee of the Third Congress of American Physicians and Surgeons was read and ordered to be placed on file.

The New Nomenclature of Diseases of the Ear and the Naso-Pharynx offered by Dr. E. D. Spear at the last meeting of the Society, was referred to the Business Committee.

The Committee on Membership reported favorably on the names of

Drs. Edward B. Dench, of New York, N. Y.
Wm. Cowen, of New York, N. Y.
John L. Adams, of New York, N. Y.
Edward Fridenberg, of New York, N. Y.
W. H. Wilmer, of Washington, D. C.

who were all duly elected on ballot.

The invited guests were requested to take part in the discussions and the reading of papers was then taken up in the following order:

I. Dr. Lucien Howe, of Buffalo, N. Y. Note on the Comparative Anatomy of the Ossicles.

II. Dr. A. H. Buck, of New York, N. Y. The Strongly Counter-Irritant Effects of the Usual Mastoid Operation.

Discussed by Drs. B. A. Randall, A. Mathewson, S. Theobald, H. Knapp, and E. Gruening.

III. Dr. Thomas R. Pooley, of New York, N. Y. A Contribution to the Brain Surgery of Ear Disease.

Read by title:

IV. Dr. H. Knapp, of New York, N. Y. Two Cases of Ear Disease with Brain Symptoms. Mastoid Operation in Both. Recovery in One, Death in the Other.

Discussed by Drs. J. Orne Green, C. J. Blake, R. A. Reeve, E. Gruening, and B. A. Randall.

V. Dr. T. Y. Sutphen, of Newark, N. J. Autopsies in Two Cases of Complicated Middle Ear Disease.

Discussed by Drs. E. Gruening, H. Knapp, A. Mathewson, S. Theobald, and C. J. Blake.

VI. Dr. Emil Gruening, of New York, N. Y. A Case of Fatal Thrombosis of the Lateral Sinus, with an Autopsy.

Discussed by Drs. H. Knapp, J. Orne Green, F. L. Jack, R. A. Reeve, and A. Mathewson.

VII. Dr. C. J. Blake of Boston, Mass. Report of the Aural Clinic of the Massachusetts Charitable Eye and Ear Infirmary for the quarter ending July 1, 1893.

At 1 P. M., adjourned to 2.30 P. M.

AFTERNOON SESSION.

The Society met in afternoon session at 2.30 P. M. The Records of the morning session were read and approved, and the reading of papers was continued in the following order:

VIII. Dr. J. Orne Green, of Boston, Mass. Demonstrations of Pathological Specimens.

Discussed by Drs. H. Knapp, E. Gruening, C. J. Blake, and B. A. Randall.

Dr. Blake suggested the reproduction of this valuable collection, if possible, by photogravures or some other process, for the Transactions, and on his motion the matter was referred to the Publishing Committee.

IX. Dr. C. J. Blake, of Boston, Mass. Stapedectomy and other Middle Ear Operations, and

X. Dr. F. L. Jack, of Boston, Mass. Further Observation on the Removal of the Stapes.

Both papers were discussed by Drs. L. Howe and B. A. Randall.

XI. Dr. Robert Barclay, of St. Louis, Mo. On the Difficulty of Operating in the Depth of the Ear, with Description and Drawing of New Instruments for Surmounting it.

Paper read by title and instruments exhibited.

XII. Dr. C. H. Burnett, of Philadelphia, Pa. Surgical Treatment of So-called Ménière's Disease (Aural Vertigo).

Read by title:

XIII. Dr. Samuel Theobald, of Baltimore, Md. An Unusual Case of Aural Reflex, due to Impacted Cerumen.

Discussed by Dr. B. A. Randall.

XIV. Dr. B. Alexander Randall, of Philadelphia, Pa. The Statistics of Ear Disease.

Discussed by Dr. S. D. Risley.

Dr. Gorham Bacon presented an incus hook devised by Dr. Hewitt; Dr. C. J. Blake, a rubber bag for application of ice, or hot or cold water to the ear, devised by Dr. F. P. Sprague; and Dr. F. L. Jack, a new electric head lantern.

All papers were referred to the Committee on Publications and the Society went into Executive Session.

In the matter of the New Nomenclature for Diseases of the Ear and the Naso-Pharynx, it was, on the recommendation of the Business Committee, laid on the table.

The Business Committee reported the following list of officers for the ensuing year, who were duly elected on ballot:

President:	DR. GORHAM BACON, of New York, N. Y.
Vice President:	DR. ARTHUR MATHEWSON, of Brooklyn, N. Y.
Secretary and Treasurer: . .	DR. J. J. B. VERMYNE, of New Bedford, Mass.
Committee on Membership:	DR. A. H. BUCK, DR. SAMUEL THEOBALD, DR. S. B. ST. JOHN.
Committee on Publications:	DR. C. J. BLAKE, DR. J. ORNE GREEN, THE SECRETARY, EX OFFICIO.

The Business Committee announced that the next meeting of the Society would be held on the last Tuesday in May, 1894, at Washington, D. C., in connection with the Third Congress of American Physicians and Surgeons.

After reading of the records of the afternoon session, the Society adjourned at 6 P. M.

J. J. B. VERMYNE, *Secretary.*

THE STRONGLY COUNTER-IRRITANT EFFECTS OF THE USUAL MASTOID OPERATION.

By Albert H. Buck, M. D., *New York, N. Y.*

The main object kept before the mind of the surgeon in opening into the mastoid process is the establishment of a free channel between the outer world and the centre of disease, which latter, in most instances, is situated either in some part of the middle ear or in the mastoid bone itself. Through this channel the products of inflammation find a much easier way of escape than by any route that nature may establish through ulcerative action, and through it, besides, the surgeon is able to introduce such remedial or mere cleansing fluids as he may think likely to exert a curative effect. But in certain cases, and they are by no means rare, the good effects of the operation are not confined to the benefits directly attributable to good drainage and thorough cleansing of the parts; the derivative or counter-irritant influence of the operation plays, I believe, a very important part in effecting a cure of these cases, and it is for the purpose of directing attention to this point that I have prepared the present paper.

Setons and issues were looked upon as valuable therapeutic agents even so recently as twenty-five years ago, but nowadays one scarcely ever hears them mentioned. In operating upon the mastoid we may establish an issue on a comparatively large scale. A gaping wound, two or three inches in length, is made in the skin, and a pit large enough to admit the end of the forefinger is exca-

vated in the underlying bone itself. This deep excavation may be left gaping, and afterwards, for a time at least, be treated as an open wound. When this course is adopted, we have all the essential conditions of a large issue; and if there be any virtue in the principle of counter-irritation, the beneficial effects that flow from it will be provided in liberal measure to the patient thus operated upon. On the other hand, if the edges of this gaping wound are stitched together in accurate coaptation, only a small outlet for the discharge being left at the lower angle; and then, if, in addition, such dressings are applied that no micro-organisms can by any possibility find an entrance into the wound, our patient will certainly be deprived in large measure, if not wholly, of whatever good effects counter-irritation is competent to supply. In the majority of cases, as I have already intimated, the disease will be cured without the aid of such additional counter-irritation, but in those cases in which the disease of the ear has set up more or less active intra-cranial inflammation, this counter-irritant power may be sufficient to turn the scale from a fatal to a favorable issue.

While I cannot hope to furnish from my case book convincing proofs of the correctness of this doctrine, I believe that the histories of the following three cases will go far towards establishing its soundness.

Case I.—The patient, a vigorous man, about 38 years of age, consulted me in March, 1890, for the relief of a discharge from the left ear, of at least thirty years' standing. Aside from the discharge and some impairment of the hearing, the ear, he said, had given him no trouble until within a few days, when a certain amount of bleeding became associated with the discharge, and had continued since. On examination I found the left external auditory canal filled with a large and very vascular poly-

poid growth. I removed it with the snare and found that it sprang from what was left of the drum-membrane, in the neighborhood of the hammer. I recommended the daily use of Angelo's ear douche, and under this *régime* the ear gave him no further trouble during the subsequent three years.

On April 15th or 16th of the present year, he sat at an open window, with a current of air blowing upon the left side of the head. Soon afterward the ear became painful, and the pain continued to increase steadily until the 18th, when he called upon me to obtain relief. On examination I found that the upper cutaneous wall of the left external auditory canal was markedly collapsed. There was a scanty, rather thin, pinkish, foul-smelling discharge in the canal. The body temperature was 103° F., and the pulse, 102. The pain was referred to the deeper parts of the ear, and to the whole left side of the head. There was no tenderness over the mastoid region.

The treatment adopted, and carried out by my associate, Dr. Robert Lewis, was the following: A free, curving incision was made across the cutaneous wall of the canal at the point of greatest prolapse, and through this opening a slightly curved silver cannula was introduced. Through this a stream of a 1 to 4,000 bichloride of mercury solution was forced by air pressure generated through the instrumentality of a rubber foot bag. This irrigation brought away an appreciable quantity of foul, cheesy material; the stream apparently escaping directly from the middle ear. Three leeches were also applied behind and below the ear, as close as possible to the auricle; and the patient was instructed to have hot flax-seed poultices applied continuously for three hours. Internally, he was given one grain of calomel, to be followed, the next morning early, by a full dose of Rubinat Condal water.

On April 19th, the patient was found to have less pain,

and the temperature had fallen to 102° F. The probe, passed through the opening in the collapsed portion of the wall of the canal, encountered everywhere roughened bone. Dr. Lewis therefore attempted, by passing a small-sized Volkmann's spoon (bowl=3 mm. in diameter) through the artificial opening, to gnaw away so much of the intervening ridge of bone—presumably carious—that the stream of water from his cannula would play directly upon the contents of the antrum. In this he apparently succeeded, for in the subsequent washing he drove out considerable quantities of foul, cheesy material.

During the next two or three days all the local symptoms improved greatly. The discharge almost entirely lost its foul odor, the prolapsed wall of the canal returned to its natural position, the temperature and pulse became nearly normal, and the pain had very decidedly diminished in severity. The appetite, however, did not return, and the patient showed no desire to leave his bed. His tongue also remained heavily coated. The urine had been examined by his regular medical attendant, Dr. Samuel K. Lyon, and found to be normal.

On April 25th, the temperature again rose to 103° F., and the patient seemed to have passed into a state of semi-stupor. As the ear had improved so markedly, it was thought that there might be a malarial element underlying the rise in temperature and the mental hebetude. Accordingly quinine was administered in divided doses until he had taken, during the twenty-four hours, twenty grains. An ice-cap was also kept constantly applied to his head. These measures produced no perceptible effect upon either the temperature or the drowsiness, and, at the suggestion of his physician, he was given two doses (about four hours apart, the one from the other) of the hydro-bromide of hyoscine, $\frac{1}{120}$ grain in each dose. This was on April 26th.

On April 27th, the patient was found to be greatly improved in every way. The temperature had fallen to normal. The drowsiness had disappeared, the dusky color of his face had changed to a natural ruddy hue. His eyes were bright. He asked for food. In a word, he seemed at last to be on the high road to getting well.

The visible parts of the ear having shown no signs of inflammatory action for at least three or four days, and apparently not requiring any other treatment than the frequent use of the warm douche with a very weak sublimate solution, the patient was left in charge of his regular attendant.

As we afterwards learned, the improvement noted above lasted only about twenty-four hours. The fever and drowsiness then returned, the right side of the body became paralyzed, and the patient died on the third or fourth day after we had last seen him.

This case is brought forward on account of the indirect testimony which it furnishes of the correctness of the statement that in those cases where the ear disease has already set up a certain amount of inflammation at the base of the brain, it is not sufficient to thoroughly drain and cleanse the original seat of the disease in the ear. Something more potent is required to bring about a subsidence of the deep-seated inflammation, and this is to be found, I believe, in the counter-irritation furnished by the usual mastoid operation. In direct confirmation of this belief I will give the details of a second case in which the local conditions of disease in the ear were very much the same as those noted in Case I., while the evidences of intra-cranial disease, at the time of the operation, were more pronounced. In fact, there was already well-marked paralysis on the opposite side of the body, and yet the patient recovered.

Case II.—The patient, a man 22 years of age, and of good general health, consulted me at my office, on January 7th, 1893, on account of long-standing trouble in the left ear. He gave the following history: There had been a discharge from the left ear since childhood, and on several occasions he had experienced pain in the ear, lasting perhaps for two or three days and then passing off. The last of these attacks had occurred during the previous November and had been of unusual severity. From that time to the present he had experienced a great deal of dizziness, and at times he had felt decidedly chilly, without having, however, a distinct chill. At other times he had felt feverish. The discharge, during this period, had remained unchanged in quantity, but from time to time he had found it streaked with blood. His general health had deteriorated appreciably during this period, and he had lost flesh to the extent of twenty pounds. Quite recently there had developed a new symptom which had given his family some alarm. I refer to the sensation observed on the right side of walking on cushions. His gait, too, had become somewhat unsteady, through his inability to perfectly control the motions of the right leg.

When the patient called at my office, I observed that he dragged the right leg a little, and that he presented the facial aspect of one who was seriously ill. An examination of the ear revealed the existence of a large polypoid mass which nearly filled the left external auditory canal. After it had been removed, it was found that an opening into the tympanic cavity existed in the vicinity of Shrapnell's membrane. A slender probe was introduced, but no exposed bone was encountered. Hyperostosis of the inner half of the external auditory canal concealed a large part of the drum-membrane. The odor of the discharge coming through the sinus was very offensive. There was no

tenderness or redness at any point in the immediate neighborhood of the ear. Mastoid operation advised.

On January 10th, three days later, I found the patient at his home in the country, materially worse. There was a moderate elevation of temperature (about 101.5° F.), and his pulse varied from 100 to 110 beats per minute, being at the same time quite weak. He had scarcely any power over the movements of the right leg, and he expressed himself as feeling very ill. Shortly afterwards he had a distinct chill.

Ether was administered and the operation of opening into the mastoid antrum was performed in the usual manner. The bone was found to be everywhere of ivory-like consistence, requiring considerable force of the mallet to drive the chisel through it. Volkmann's spoons proved to be of no use until the antrum had actually been reached. They were then used in enlarging the opening into this cavity. By repeated injections of a warm 1 to 4,000 bichloride of mercury solution, and by the frequent employment of the slender middle ear probe, which was pushed as far as possible in all directions, the cavities of the middle ear were finally cleared of their foul cheesy contents. It was surprising how large a quantity of this material was stowed away in this comparatively small space. A careful exploration was made for the purpose of ascertaining whether, through destructive ulceration, an opening had not been established in the bony tegmen tympani. No such opening, however, could be found.

The edges of the wound were left gaping; iodoform gauze dressings were applied; and daily cleansing of the parts constituted the essential feature of the after-treatment. (The patient was under the care of Dr. T. H. Andress, of Sparta, N. J.) About the fifth or sixth day, when it was found that the case was progressing favorably in every respect, the edges of the granulating wound

were approximated by means of a silver suture, which had been put in place (ready to be utilized at some later date) at the time of the operation. On February 16th, five weeks after the operation, the patient called to see me at my office. The external wound had entirely healed, but there was still a very slight discharge from the external auditory canal. All pain in the ear and head had disappeared, and the right leg had returned to an entirely normal condition. His general health was excellent.

In the following case, thanks to an error which I made in the diagnosis, I am warranted in excluding wholly from consideration the possible effects of drainage and cleansing upon the favorable course pursued by the obscure deeper-lying disease. Absolutely no ear disease whatever was found to exist in this case at the time of the operation, and consequently, in weighing the therapeutic effects of the latter, we are perfectly justified in speaking of it as an issue pure and simple.

The history of the case is as follows:

Case III.—The patient, a lady about 50 years of age, and, up to the time of the attack, in good general health, contracted a bad cold in the head early in April, 1892. This was soon followed by tinnitus and pain in the left ear, and impairment of the hearing. The pain resisted the ordinary measures employed for its relief, and gradually increased in severity. It involved the entire left side of the head, but was referred more particularly to the mastoid region. When the patient was seen by Dr. Thomas E. Satterthwaite, about May 1st, he found decided swelling and tenderness of the auricle and neighboring soft parts; the motions of the jaw caused pain in the left ear; the glands on the side of the neck, below the ear, were swollen; and there was a tense swelling on the

posterior wall of the pharynx, behind the left tonsil. An incision of this swelling afforded escape to a considerable quantity of creamy pus. The posterior wall of the left external auditory canal was found to be swollen, and an incision in this region also gave vent to a certain amount of pus. From this time onward, for a period of nearly three weeks, the patient experienced comparatively little pain in the ear or in any part of the head. The hearing, on the left side, soon returned to a fairly normal condition. Pus, however, continued to escape from the opening in the posterior pharyngeal wall, and the patient steadily grew weaker. The constant escape of pus into the fauces rendered her less and less desirous to take food. In fact, she had to be coaxed a great deal before she could be induced to take the necessary amount of nourishment. It was observed, too, that her mind was beginning to be perceptibly affected, and the pupil of the left eye was noticeably larger than that of the right. The body temperature did not at any time during her illness rise above 99.5° F. The pulse rate was about 80, and the pulsations, as might be expected, were feeble. About May 20th, she was seen by Dr. Robert Abbe, of this city. He was disposed to refer the source of the pus, which continued to flow abundantly from the opening in the pharyngeal wall, to disease of the sphenoid bone. He advised against operative interference. Shortly after this, the patient again began to complain of pain in the left mastoid region, and it was found that the hearing of the left ear had again become somewhat affected. There was also some redness of skin behind the left ear, together with slight tenderness on pressure. As these symptoms persisted, I was asked (May 26th) to see the case in consultation with Dr. Satterthwaite and Dr. Terhune, of Passaic, N. J. I found the patient in a condi-

tion of semi-stupor, whether from simple physical weakness or not, I could not determine. Her pulse was 80 and decidedly weak. There seemed to be some redness and swelling of the left mastoid integuments, but as a blister had been applied over the lower part of the process, and some distance below it, two or three days previously, I could not feel sure of the correctness of my observation. The external auditory canal and the membrana tympani were entirely free from any evidence whatsoever of inflammatory action. The spitting-cup, filled with water, was shown to me, and in it, floating as a separate mass, was about a tablespoonful of thick yellow pus. This represented, I was told, the entire quantity that the patient had spat out during the previous twenty-four hours. An examination of the pharynx revealed no points of special interest. The exact spot from which the pus escaped could not be verified by mere ocular inspection.

In the presence of such conflicting evidence—a history pointing strongly to the left ear as the primary seat of all the trouble, and yet, at the time of my examination, an almost entire absence of any recognizable disturbance in the ear—I felt considerable hesitation about putting forward even a diagnosis of probabilities. Nevertheless, from the sequence of pathological events, and especially from the recent return of mastoid pain and tenderness, I felt disposed to believe that there was still, in the substance of the mastoid process, a small remaining centre of osteitis, the purulent products of which were escaping through some opening in the under part of the process, presumably in the vicinity of the digastric fossa, and were seeking an outlet through the unhealed opening made with the knife in the post-pharyngeal abcess. This centre, I assumed, must necessarily be somewhat removed from the mastoid antrum, and from that part of the process which constitutes the posterior wall of the external

auditory canal; for otherwise it would have betrayed its existence by redness or swelling of the soft parts of this canal, both of which conditions (as already stated) were absent. I further argued that if, perchance, this diagnosis should prove to be correct, the more direct drainage and ultimate healing of this centre of mastoid inflammation which we might reasonably expect to obtain by an operation, would in all probability cause the post-pharyngeal abscess to heal.

On the following day, May 27th, the operation was performed. A curving incision, about two and a half inches in length, was made through the skin and periosteum, the outer surface of the mastoid bone was freely exposed, and by means of the chisel and mallet and Volkmann's spoons, a large part of the bone substance lying external to the antrum was removed. Not a trace of anything like diseased bone was found, either in the main body of the bony prominence or in the direction of its tip, a large part of which was removed with the Volkmann's spoons. There was not even any recognizable congestion of these parts. In a word, the mastoid was found to be in a perfectly heathly condition.

The edges of the wound were left gaping, and simple iodoform gauze dressings were applied. From this time forward the patient, who remained under the care of her regular attendant at first, and then for a brief period under that of my associate, Dr. Robert Lewis, improved steadily, although not rapidly. In the course of from four to five weeks the outside wound had healed, the discharge from the post-pharyngeal abscess had ceased, the mental disturbances had disappeared, and she had fully regained her general health and strength.

By way of summing up, let me rehearse briefly the salient distinguishing features of the foregoing three cases.

In the first two, it is highly probable that the intra-cranial lesions were very nearly alike in extent and intensity. In the one, the original centre of carious bone, with its accumulation of foul *débris*, was effectively cleansed and drained, and yet the intra-cranial disease pursued its course to a fatal termination without manifesting any but a transient tendency to quiet down under the influence of this drainage and cleansing. It had acquired so great an independent momentum that it no longer needed, for a continuance of its harmful course, the stimulus of the adjacent centre of middle ear disease. The same remarks, I believe, apply with equal correctness to the second case. Here, too, the original centre of carious bone disease in the middle ear was drained and cleansed, but the intra-cranial disease, instead of growing worse, underwent a steady and permanent change for the better. To what shall we attribute this favorable change if not to the powerful counter-irritant effect furnished by the presence of an extensive issue in the immediate neighborhood?

Finally, in the third case, the conditions of our problem in therapeutics are rendered peculiarly simple by the entire absence, so far as could be ascertained, of any centre of disease in the middle ear or mastoid bone. In this case, therefore, the establishment of an issue pure and simple is the only therapeutic procedure of which there can be any question. Indisputable, too, is the existence of some deep-seated and serious disease; whether at the base of the brain, or in the sphenoid bone, or where, is just now a matter of no special importance. The patient's full, and, on the whole, rather quick recovery completes the series of facts. Do they not warrant the conclusion that counter-irritation, in the form of an extensive issue, effected the cure obtained in this case?

DISCUSSION.

Dr. Randall:—In relation to the third case reported, it must not be forgotten that there may be mastoid cells on the inner side of the digastric fossa. In view of the clear history of mastoid symptoms, it is possible that a further study of the digastric fossa would have shown that some of the cells in that direction were the ones involved. The cells communicating with the other cells of the mastoid and the antrum may also extend into the occipital bone and be the source of discharge. The only cases that I have seen of abscess in the pharynx have been where the pus has burrowed from the inner side of the digastric fossa, forming post-pharyngeal abscess. I have also seen suppuration occur in the more remote cells posteriorly, giving rise to meningitis and extra-dural abscess, and in these cases there was at no time more than slight evidence of tympanic trouble. The examination showed only congestion of the handle of the malleus and yet mastoid suppuration was present and went on to a fatal termination.

I should like in this connection to show to the Society a compact case of instruments for mastoid operations, which I have found useful, consisting of a nicked pan with a lid to which the instruments are fastened by metal loops. It contains scalpels, forceps, hæmostats, chisels, rongeur, trephine, and burrs, spoons, etc., yet will go into a large pocket.

Dr. Mathewson:—I have formerly reported to the Society a case which presents some point of similarity to the third case described by Dr. Buck. In my case, after long continued pain and suffering, there was an opening in the pharynx, with discharge lasting a long time. An opening was made in the mastoid, and while there was no carious bone or pus in the mastoid—it seemed to be a case

of hyperostosis—the operation gave relief, although not so complete and immediate as in the case of Dr. Buck, but still doing a great deal towards relieving the pain, and leading in the end to complete recovery. I mention the case as bearing upon the therapeutic part of the discussion.

Dr. Theobald:—I think that Dr. Buck's view is borne out by many cases in which the mastoid is opened. It is a common thing to open the mastoid and find no pus, and even where pus does not afterwards make its appearance, the case is greatly benefited by the operation and the change for the better manifests itself at once. These cases would rather sustain Dr. Buck's view that much of the benefit is due to counter-irritant effect, like that of an issue.

Dr. Knapp:—The term "revulsive" effect is rather a vague one. It is well known that we often find a condition of congestive mastoiditis. This is a chronic process leading to persistent headache and disability to think or do work. When we operate, we find nothing but blood, but the result is almost always satisfactory. The opening of the bone contributes materially to the healing of the congestive mastoiditis. The result is from the direct physical effect of the operation.

With regard to the question of suppurative processes in the brain, we must have a long series of observations before we shall know how much benefit is afforded in intra-cranial processes by removing the source of the suppuration. I believe that in many cases where we destroy the source of the suppuration, the brain affection is beneficially influenced. There are a number of cases, and even cases of pyæmia, of which I have had some myself, where I have seen this statement distinctly demonstrated. I think that in many of the cases where the cranial cavity, the mastoid, the lateral sinus, and the internal jugular vein

have been opened, a good termination might have been obtained by leaving those things alone, for we know that pyæmia may get well spontaneously. Furthermore, in cases where the cranial cavity and the lateral sinus have been opened, I have seen meningitis develop and soon terminate fatally. This gave me the suspicion that perhaps too much is done in this direction. This principle, that the destruction of the source of suppuration has a tendency not only to prevent, but to act curatively on, the extension of the suppuration, I believe in and have taken as a rule of guidance for many years.

Dr. Gruening:—I think that the observations of chemotaxis referred to by Dr. Knapp, and which I think were first made by Leber, may be well applied to these mastoid cases. It has been demonstrated that in the presence of a bacterial focus, leucocytes gather from the neighboring vessels, migrating and forming a focus, as, for instance, in the anterior chamber of the eye. In cases of corneal infection we may find a collection of material in the anterior chamber without perforation, demonstrating that the toxine produced by the cocci draw the leucocytes into the anterior chamber. So it may happen in mastoid disease. Where there is a focus of infection in the mastoid, we may have a migration of leucocytes into the neighboring cavities and even perhaps into the brain, and often we have it in the lateral sinus. I have seen a number of cases where the lateral sinus was surrounded by pus and where opening of the mastoid and cleansing of the wall terminated the process favorably. The clinical aspect of cases certainly bears out the theoretical views of chemotaxis. In ulcer of the cornea, bacteria are found in the cornea and although there is apparently a focus in the anterior chamber, no bacteria are found there: so it is possible, that although we have bacteria in the middle ear and in the mastoid, we may not have them on the brain side, but may

have a simple collection of leucocytes, which may disappear.

Dr. Buck:—I wish to emphasize a point which I perhaps did not bring out fully in the paper, that is, that in the third case the appearance of the mastoid was perfectly normal. It is, I fully believe, the first healthy living mastoid process that I have seen. I did not even find a congested condition. I have often wondered if what we considered a congested condition of this bone were not, in reality, the normal appearance. When we find proliferating tissue in the mastoid cells, there can certainly be no doubt; but in this particular mastoid the parts were absolutely normal at every point that was reached. The bleeding was so scanty that I could see everything distinctly. While I feel convinced that in this third case the starting point of the disease was in or about the ear, nevertheless, at the time of the operation, I am confident that there was no ear disease of any kind. I can not speak positively in regard to the existence of a centre of disease located further inward, for example, to the inside of the digastric fossa, yet I can scarcely conceive of there being such a centre of disease as Dr. Randall refers to, without there being, at the same time, at least congestion of the parts that were actually reached. Such congestion was conspicuously absent; but, as I have said, I believe that in its first inception this case was one of inflammation of the ear.

TWO CASES OF EAR DISEASE WITH BRAIN SYMPTOMS; MASTOID OPERATIONS IN BOTH: RECOVERY IN ONE, DEATH IN THE OTHER.

By H. Knapp, M. D., *New York, N. Y.*

Case I.—Extensive caries and necrosis of the temporal bone of a child; mastoid operation; death from exhaustion and hemorrhage forty-two days later.

April 28th, 1893, an exceedingly feeble and anæmic child was brought to me in the aural department of the New York Ophthalmic and Aural Institute. She was in an exceedingly lamentable condition. For a few months there had been copious and very offensive otorrhœa on the left side. When she came, the discharge was thin and had a most penetrating odor. The whole mastoid region was swollen, bluish, and soft, yet there was no fluctuation. I told the mother if anything would save the child's life, it was a prompt operation. She consented, and I operated on the child, May 1st, 1893, at the "Institute." A curved incision of five centimeters laid bare the whole mastoid and a portion of the bone above the ear. There was no subperiosteal collection of pus. The outer cortex of the bone was brittle and easily broken into by chiselling. Complete removal of the outer table laid bare a large cavity filled with soft and necrosed bone and granulations, bathed in thin, offensive pus. All this tissue was scooped out and thus a large cavity formed, comprising the interior of the mastoid process, the tympanic cavity, and the adjacent portion of the petrous bone. Water (bichlo-

ride $\frac{1}{10000}$), injected into the wound, flowed freely out through the ear, and *vice versa*. The cavity of the wound was filled with corrosive sublimate gauze and irrigated once or several times daily. The child rallied somewhat, but there was no tendency to repair in the wound. Careful examination and scraping with a sharp spoon, which was repeatedly done, brought out a few particles of brittle bone and a moderate flow of dark blood. It showed distinctly that the petrous portion was extensively diseased. I could not undertake to remove a part of it on account of the risk of an immediate fatal result. It seemed to me that a gradual exfoliation of the inner ear was preparing. A week before the child's death, palpation with a probe discovered that the posterior wall of the bony portion of the external ear canal had begun to loosen itself, yet it was still too firm to be extracted by force.

July 3d, I examined the ear again. The loosened piece of the ear canal had become slightly movable, yet in the feeble condition of the child I did not venture to extract it before it had become detached. Careful probing of the petrous bone revealed an extensive carious and irregular surface, but no loose bone. As always, the exploration was accompanied by a moderate amount of dark blood, resulting from the granulating bony surfaces. The hemorrhage was not alarming in any way. I dressed the ear as before: corrosive sublimate gauze, absorbent cotton, and a flannel roller. The child, who was treated as an out-patient, was taken home. The next day I was informed that there had been some bleeding from the wound the whole night, and that the child had died at seven o'clock in the morning. I went to see her the same morning and tried my best to obtain an autopsy, but all my efforts—the parents being Hebrews—were of no effect.

The hemorrhage did not seem so extensive as to have

caused the death, but in the exceedingly precarious condition of the child's health it may have contributed to hasten it. The probing done at the Dispensary could not have opened the internal carotid artery or the lateral sinus, for in the former case the bleeding would have been arterial, and in the latter, which I have witnessed several times, it would have been suddenly copious, whereas it was no more than the ordinary amount on previous occasions. It was again one of those cases in which suppurative ear disease had been allowed to run its destructive course so long that the changes were so extensive and the vitality of patient so reduced that the operation came too late.

Case II.—A case of chronic middle ear suppuration, with grave brain and lung complications; opening of the mastoid; wounding of the lateral sinus; complete recovery.

Dec. 22d, 1892, Mrs. Jos. Hy. Hamilton, a healthy-looking woman, 38 years old, of New York, came to my office complaining of pain, discharge, and deafness in her left ear. The impairment of hearing and occasional inflammatory attacks had lasted a year. Now they were worse. I found the upper and posterior part of the drum-membrane red and bulging, and a large perforation in the lower part of the membrana tensa. I ordered syringing with warm boric acid water and instillation of a solution of sulpho-carbolate of zinc 0.15 in 60.00 of 25 per cent. alcohol. There was catarrhal rhinitis, for which I gave her a weak solution of carbolic and boric acids to be snuffed up. For three months the course of the disease varied considerably at short intervals. Three times I found the attic and posterior part of the canal so much swollen,

together with pain in head and ear, and stoppage of the discharge, that I advised her to be operated on in the New York Ophthalmic and Aural Institute, where I intended to make a broad opening into the membrana tympani flaccida, explore the attic with a probe and act according to the condition. The next day, when she came for the operation, I found each time the ear so much improved that I did not consider operative interference justifiable. The bulging in the upper part had greatly diminished and a small perforation was noticed in the lower part of the drumhead.

On March 27th, the disease took a more serious turn. She had pain in the head, some swelling and tenderness of the mastoid, pain on percussion about 2″ behind the ear. Temperature, 98.5°. I advised her to have the mastoid opened. She consented, but the next day she wanted the operation delayed on account of the advent of her menstruation.

March 29th, there was a small perforation in the lower part of the membrana tympani, the upper part no longer bulging, but the mastoid still red and tender. Constant headache. Temperature, 98.1°.

April 3d, had severe pains, relieved by removal of the discharge. Membrana tympani red, bulging in posterior part. Temperature, 98.6°.

April 13th. Last night severe pain in the head, delirium, stupor, chill, vomiting. Felt uncomfortable in her chest. No definite symptoms on percussion and auscultation. Pulse, 120. Respiration, 30. Temperature, 104° F. No discharge from ear. Mastoid red and tender. Optic disc distinctly hyperæmic and swollen. I advised her to call in her family physician, Dr. W. C. Campbell. Both he and his father came and found the same absence of positive physical symptoms to explain the acceleration of respiration and pulse and the high temperature.

The ear disease being the only palpable lesion, and, the possibility of the lung complication being a consequence of it, determined us to operate on the mastoid without delay.

In the afternoon of the same day, the patient being etherized, I opened the mastoid in the usual way. No pus; no diseased bone was found after the splitting of the periosteum. The bone was chiselled into to a length of three centimeters and a depth of two centimeters. The external cortex was hard. The middle portion of the mastoid was compact, with here and there a small pneumatic cavity. The deeper layers were softer and grew more and more vascular the farther I penetrated. Neither pus nor granulation tissue anywhere. On chiselling deeper, a sudden gush of dark blood flooded the field of operation. Stopping the wound with the finger made the bleeding cease in less than a minute. The operation was carried no farther, the wound filled with corrosive sublimate gauze and dressed with absorbent cotton.

For a whole week the patient was in a critical condition. Respiration, 40; temperature, 104°; pulse, 130; intense headache, oppression of chest, drowsiness, and at night mild delirium continued almost uniformly for a whole week. The wound showed no reaction whatever. The ear began to discharge again five days after the operation. The lung disease was declared pleuro-pneumonia, but the physical symptoms were never marked.

From the ninth day after the operation the patient began to rally, and improved steadily from day to day. The wound filled with granulations, which were scraped off several times, but no dead bone was felt. Mucopurulent discharge from the ear, the drumhead bulging and pink in upper part.

May 25th, a small perforation was still seen in the lower part of the membrana tympani; there was scant

discharge from the ear, none from the mastoid. Then the perforation of the membrana tympani and the wound in the mastoid closed, the drumhead resumed its normal color, and relief. The hearing became almost normal, and the general health perfectly restored. The congestion of the optic disc had disappeared in the first three weeks.

On consideration of the symptoms and the prolonged course of the case, I feel satisfied that purulent attic disease was the origin of the difficulty. In its usually protracted course, it developed cerebral irritation, which showed repeated exacerbations until it developed into real intra-cranial inflammation. The opening of the whole depth of the mastoid showing no pus, we must assume that the suppuration passed into the skull through the roof of the drum cavity. That there was an extension of the inflammation through the bone into the cranium, may be inferred from the great vascularity of the inner table of the mastoid, as compared with its middle and outer portions. The lung complication may be regarded as pyæmic pleuro-pneumonia, on the strength of the absence of the physical signs of the ordinary (lobar) pneumonia, and the presence of distinct congestion and swelling of the optic discs, a picture such as I have seen in the beginning of typical choked disc, produced by otitic meningitis and thrombo-phlebitis, verified by post-mortem examination.

Pyæmia, after severe otitic brain disease, may, as is well known, be completely recovered from with or without operation on the mastoid and the brain.

Our patient made a good recovery, but, I must confess, she had a narrow escape. From the whole disease, as it now lies before me, I abstract the lesson, that in similar cases of attic suppuration, the cupola space of the drum cavity should be widely laid bare and the discharge removed with an intra-tympanic syringe. Should this

treatment fail, I would establish a free communication between the drum cavity and the mastoid antrum, according to the operative methods of Schwartze or Stacke.

DISCUSSION.

Dr. J. Orne Green:—I am interested in the hemorrhage which is referred to a wound of the lateral sinus. It has occurred to me twice in this operation to have serious venous hemorrhage and in both cases I satisfied myself that the hemorrhage was not from the lateral sinus. I would ask Dr. Knapp if he had distinct evidence that in his case the blood came from the lateral sinus. In the first of my two cases the removal of a small splinter of bone was followed by a sudden tremendous gush of dark venous blood. I put my finger in the wound and in a minute the bleeding entirely ceased. I then took a probe and found that I had opened the deep mastoid pneumatic cells and that the cavity was bounded by bone in all directions. I had evidently struck a large diploic vein. There was no further hemorrhage. In the second case the hemorrhage was severe and more obstinate, but in that case also the probe showed bone in every direction. I believe that once in a while you meet with these large diploic veins, and especially in cases where you do not find pus and where there is rather intense congestion and more or less sclerosis. In looking over Schwartze's articles, I see that he mentions this. I am satisfied that many operators condemn themselves for having opened the lateral sinus when they have struck these large diploic veins. I have not opened the lateral sinus that I know of and these are the only two cases in which I have had serious hemorrhage.

Dr. Knapp:—In my case, I am not sure that I opened

the lateral sinus, but I believe that I did. In a case of sclerosis where the conditions were exactly the same, I went into a cavity and there was excessive bleeding. I put my finger in and the bleeding stopped at once. I then probed the cavity and found that there was no bony resistance. There was soft resistance, and when I touched a certain spot blood came out profusely. When I removed the probe the bleeding stopped. My explanation in this case was that I had perforated the lateral sinus obliquely, the current of blood had closed the perforation, and the pressure with the probe opened it again. I made this experiment twice. In this case, I felt that the bleeding was from the lateral sinus.

Dr. Blake:—I opened the lateral sinus last year. The case was one in which it was necessary to make a large external opening and to take out a portion of the inner mastoid wall, and in doing this there was a sudden and copious dark hemorrhage; the use of the sharp spoon was continued as rapidly as possible, and the bleeding ceased in a moment. The opening in the mastoid being sufficiently large to allow a fair view of the inner mastoid wall, after careful cleansing, it was found that with a probe an opening on the inner wall, with soft tissue filling it, could be easily determined. Pressing this tissue back, the hemorrhage recurred, and on removing the probe the hemorrhage ceased. I felt sure in this case that the lateral sinus was opened and that, the bony wall having been taken away, the pressure of the brain by driving the soft parts into the opening had prevented the continuance of the bleeding.

Dr. Reeve:—I have met with a similar occurrence in a case operated on some years ago and this case led me to make the observation that after a preliminary smart hemorrhage, if the parts were left alone, the bleeding did not recur. In one case where there was free hemorrhage

stopped by pressure, the probe revealed soft yielding tissue over an area larger than would be compatible with the supposition of a diploic vein. The hemorrhage was very copious. I have no doubt that in that case the lateral sinus was opened.

In another case operated on a year ago, there was most profuse hemorrhage, which stopped on pressure with the finger and recurred for a few minutes after the finger was withdrawn. I feel morally certain that in that case the sinus was opened. After the finger was removed the second time, the hemorrhage did not recur and the cavity was packed with iodoform gauze.

Dr. Gruening:—I have had some experience with opening of the lateral sinus. In one case I exposed the sinus and demonstrated it. There was prolapse of the sinus, which I have never seen described. The anterior wall of the cortex was removed, exposing a large cavity with prolapse of a mass into the cavity. This was the anterior wall of the lateral sinus. There was some granulation tissue on the inner side of the bone, and with the rongeur forceps I tried to remove the bone, and in doing so caught a part of the wall of the sinus in the grasp of the forceps. The gush of blood which followed was enormous. There could be no doubt that it came from the sinus. The wound was plugged and I did not have the courage to remove the plug and terminate the operation. The patient recovered. I have opened the sinus in four cases, and all the patients recovered, although the operation was left unfinished.

I do not fear the opening of the sinus; it is our duty to open it where we diagnosticate thrombosis. In a case recently operated on by Dr. Abbe, diagnosis of thrombosis of the sinus was made. The sinus was exposed and the thrombus scraped out and the operation was continued until a free current of blood from the sinus was estab-

lished. The patient, however, died because she had meningitis. The case has been reported by Dr. Allen quite recently.

Dr. Randall:—In the only case of this kind that I have had there is a possibility of error in regard to the lateral sinus having been opened. The hemorrhage was persistent and copious enough to require the tampon and to preclude the possibility of continuing the operation, which had been pushed in this direction only at the last. Recovery after these severe venous bleedings seems to be the general experience, and this fact points to the comparative immunity with which the sinus can be opened to this extent. The suggestion of Dr. Gruening that we should usually lay bare and possibly explore the lateral sinus, has been rarely acted upon by the aural surgeon; for the reason that we have brought our pyæmic cases, with the clinical evidence of septic thrombosis, safely through without resort to this interesting and important operation, which unfortunately does not always end brilliantly, but often furnishes interesting autopsies. The aurist is not likely to follow the general surgeon in this direction. I believe that our reserve is not the timidity of the untrained surgeon, but the conservatism of men who know the anatomy and know what can be done without resort to such precarious measures.

Dr. Reeve:—In regard to the opening of the diploic veins,—in one case in which a brother practitioner asked me to operate, cocaine was used, and after the opening was made there was pretty free hemorrhage. My friend directed the patient to practice inflation by the Valsalva method. This caused a stream of blood fully a foot long to be projected from the ear. I believe that in that case a vein was opened. When the inflation stopped the bleeding ceased.

Dr. Knapp:—Dr. Green's remarks in regard to hemor-

rhage are of importance. When the patient dies, as in the first case reported, the friends are apt to attribute the result to the manipulation. Hemorrhage may occur at any period and may be fatal, even if capillary in character. In the child that died, the whole region was so vascular that the dilated veins could be seen lying there like snakes. In a child much emaciated, it requires but a moderate loss of blood to cause a fatal termination.

AUTOPSIES IN TWO CASES OF COMPLICATED MIDDLE EAR DISEASE.

By T. Y. Sutphen, M. D., *Newark, N. J.*

Case I.—A man, æt. 30, was brought to St. Michael's Hospital, Newark, January 21st, and in my absence was seen by Dr. W. F. Seidler, who opened an immense abscess involving the left mastoid region and the neck beneath. The patient gave a history of long continued middle ear suppuration. Two days later, when I first saw him, the mastoid was found extensively carious, the probe penetrating the cavity without trouble and the tissues of the neck widely undermined.

The patient was perfectly rational, but had moderate fever, a leaden hue to the skin, and an anxious look upon his countenance, which betokened more serious complications. During the following three or four days the symptoms grew worse, a hacking cough developing, with difficult respiration. The temperature became higher, and dullness well marked over the right side of the chest. Septicæmic symtoms increased and in a week he died, after several hours of coma.

The autopsy was made by Dr. Seidler, who gave me the following facts: An abscess canal had developed outside the dura mater, extending from the carious mastoid downwards, where it had then penetrated the dura and ended in an abscess in the cerebellum, one and a half inches in diameter, having adjacent to it two other spots of softening. There were also three small abscesses, the size of a pea, upon the inferior surface of the cerebellum. No general

meningitis. The right pleural cavity — the one on the opposite side from the ear trouble — was half filled with sero-purulent fluid, while the entire pleural surface was bathed with pus. The upper lobe of this lung showed gray, the middle red, hepatization; and the lower lobe, a large broken down abscess cavity, nearly three inches in diameter. The larger bronchi were filled with very offensive sero-sanguinolent fluid and pus. The left lung was œdematous. Heart, small and flabby. Spleen, twice its normal size, congested, soft, and pulpy. The liver was large and soft.

Case II.—A Polish Jew, æt. 26, was referred to me in March by Dr. Dieffenbach, of Newark. He gave a history of middle ear inflammation, right side, lasting several weeks, the discharge ceasing one week before his visit to my office. For ten days he had had severe headache upon that side, which had become more and more intense. Inspection showed the drumhead intact, red and thickened, but not distended, and the watch was heard at four inches. The middle ear was easily inflated by Politzer's method. There was no swelling, pain, nor tenderness on pressure over the mastoid; no paralysis; ophthalmoscopic examination negative. Three days later I was called to see him at his home, and found him comatose, with a temperature of 104°. There were slight symptoms of opisthotonos, while any effort to turn his head gave him pain, as was evidenced by a whining cry. He was sent immediately to St. Michael's Hospital. The following day the temperature was considerably lower, and the patient could be aroused. The mastoid was then opened by the drill and the cavity thoroughly explored, but no pus was found. The following morning the patient died.

The autopsy, which was made with the assistance of Dr. J. Harry Clark, showed the mastoid congested, but containing no pus; and no communication between this and the cranial cavity. The meningeal space was occupied by a large amount of sero-purulent fluid. The right lateral sinus contained a large and softened clot, communicating with the meningeal cavity. A small patch of thick pus was adhering to the anterior surface of the inferior occipital fossa. Upon lifting out the cerebellum, the entire meningeal surface was found bathed with pus, which extended forward as far as the optic commissure, and enveloped the medulla and upper portion of the spinal cord. No abscess was discovered in the brain substance.

These cases are reported for their statistical value, the first exemplifying the excursions pus may make within the cranial cavity and the extensive metastatic complications which may arise, while the second is added evidence to the fact that fatal brain trouble may be developing even after the suppuration has ceased, both in the middle ear cavity and the mastoid.

DISCUSSION.

Dr. Gruening:—The first case is of interest from the fact that the abscesses were multiple. If a neurologist were called to such a case he probably would have struck one of the abscesses. This is not infrequent. Dr. Knapp has published a case where there were multiple abscesses. These cases show the importance of operating early when the disease is confined to the mastoid and to open the sinus, which is less dangerous than to rely on the localization of an abscess in the brain by the neurologist.

Dr. Knapp:—According to statistics, multiple abscesses are found in about four per cent. of the cases. I should

like to know whether or not in the last case reported by Dr. Sutphen there was a black patch in the roof of the tympanum or in the petrous portion. It has been shown that in many cases the path of the inflammation goes through the mastoid itself; in another large number, through the roof of the tympanum, especially in attic disease, and also along the posterior surface of the petrous bone, and sometimes, though rarely, through the petrous bone and internal meatus. The statistics of Dr. Allen's one hundred and sixty-nine cases agree with the well known fact that suppuration may terminate in its original place and go on in the brain. The brain abscess may be referred to an injury or disease occurring years before and there is no possibility of following out its track.

Dr. Mathewson :—As illustrating a point referred to, I may mention a case which I had where there was mastoid complication of middle ear trouble. With the removal of the dead bone the parts healed and the opening in the membrana tympani closed, with perfect restoration of hearing and disappearance of all local symptoms. The case was discharged in October of one year, and the following spring there were some symptoms of brain trouble, which finally terminated fatally, and the post-mortem showed a large cerebellar abscess. The most careful examination failed to show any trace of what was undoubtedly the origin of the trouble in the middle ear and mastoid.

Dr. Theobald :—As bearing upon the question of direct extension of inflammation from the middle ear to the brain, through the roof of the tympanum, I recall the statement made by a good authority, that probably every case of severe middle ear inflammation is accompanied by a certain amount of localized meningitis, more especially just over the roof of the tympanic cavity, the vascular

connection between the meninges and the drum cavity being here so close and the parts separated by such a slight amount of tissue.

Dr. Sutphen :—In reply to the question of Dr. Knapp, I would say that the only evidence of disease in the middle ear or mastoid was that of inflammation. There was no black spot nor any sign of caries.

A CASE OF SEPTIC THROMBOSIS OF THE LATERAL SINUS. WITH AUTOPSY.

By E. Gruening, M. D., *New York, N. Y.*

This case of septic thrombosis of the lateral sinus is reported here because the diagnosis was not made during life, but at the post-mortem table. The sinus, which had been exposed to view in the operation, was inspected every day and as it looked healthy, the symptoms of pyæmia were ascribed to absorption of septic material from other parts of the affected temporal bone.

Sarah Elgard, a married woman, 38 years of age, was admitted to the Mt. Sinai Hospital on May 17th, 1893, with the following history: For the past six years she has suffered with a profuse discharge from the left ear, and at times with severe headache. Three weeks before her admission the ear began to ache and behind it appeared a considerable swelling. At the time of the examination fetid pus flowed from the left ear, and the discharge became more copious when pressure was made on the mastoid process. The walls of the canal were red and swollen. The swelling was more pronounced in the posterior wall, in the region of the mastoid antrum. There were two perforations in the drum, a large one, comprising almost the whole lower half of the membrane proper, and a small one in Shrapnell's membrane.

Temperature, 98.6° F. Pulse, 100. Respiration, 24.

On May 18th, I performed an operation on the mastoid process, making the incisions in the ordinary way. I found that the cortex was extensively carious and covered

with flabby granulations. With the sharp spoon and the rongeur, the granulations and the remainder of the cortex were removed. A large cavity filled with pus and lined with granulations was exposed. The posterior boundary of the mastoid cavity was formed by the membranous wall of the lateral sinus, the bony wall having been destroyed. Through the large opening the sinus could be well seen; it appeared healthy but did not pulsate. The mastoid antrum was readily exposed, cleansed, and scraped. Water injected through the antrum did not flow off from the ear. The cavity of the mastoid was packed with iodoform gauze and an aseptic dressing applied.

On the following two days the patient felt quite well and her temperature did not rise beyond 99° F.

Contrary to my advice, she dressed on the third day and walked about the ward. When I visited the hospital I found her out of bed and induced her to lie down. In the evening of that day she vomited and her temperature rose to 105.4°. The dressing was removed and the wound examined. There was a slight discharge of inodorous pus both from the ear and the mastoid wound. The lateral sinus had a glistening dark-blue appearance, was soft and compressible, and did not pulsate. It looked to me perfectly healthy. The wound was cleansed and the internal administration of whiskey and caffeine ordered. The ophthalmoscopic examination was negative.

May 22. Temperature, 105°. Pulse, 120. Respiration, 36.

May 23. Temperature, 104.8°. Pulse, 132. Respiration, 38.

The urine contained albumen, casts, red and white blood cells.

May 24. Temperature, 99.6°. The patient had a chill, followed by temperature 105°. The wound was dressed. The assistant reported that the sinus pulsated. At a later visit I could not find any pulsation.

May 25. 4 A. M., temperature, 100°, rising later to 105°. Caffeine and digitalis were given.

May 26. 6 A. M., temperature, 105.8° after a chill. 8 A. M., temperature, 105.2°. Respiration, 40. 12 M., temperature, 105.6°. Respiration, 44.

Redness and swelling over the metacarpo-phalangeal articulation of the little finger of the left hand and the ring finger of the right hand. Dullness over right lower lobe (posterior) with crepitant and subcrepitant râles and friction sounds. Sensorium clear.

May 27. Patient was delirious during the night. Cyanosis and dyspnœa. Sibilant breathing and bronchophony. At 2 P. M., temperature, 105.4°. At 4 P. M., temperature, 104°; pulse, 114; respiration, 60. Died at 6.30 P. M.

Post-mortem examination by the house physician, Dr. H. A. Cohn. Nothing abnormal found in the brain and its meninges. The left lateral sinus contains a cheesy fetid clot which adheres to the roughened inner wall of the sinus. The clot does not touch the outer wall and consequently does not fill the lumen of the sinus. The other sinuses and the jugular veins contain dark tarry blood and post-mortem clots. Some œdema of both lungs. Consolidation of both upper and lower lobes of left side in red hepatization. Right lung, consolidation and hepatization at base.

The right heart contains a post-mortem clot.

The kidneys are enlarged and congested, the capsules not adherent.

The spleen is enlarged, pale, of firm consistence.

The liver is enlarged and pale. No metastatic abscesses.

The left temporal bone was removed. I exhibit it here to demonstrate the carious destruction of the bony wall of the lateral sinus. The opening through the sigmoid sul-

cus is almost circular in outline, has a diameter of two centimeters, and communicates with the large mastoid opening.

In my introductory remarks I mentioned that the diagnosis of septic thrombosis of the lateral sinus was not made intra vitam. On the third day after the operation, the patient developed pyæmic symptoms with high fever and characteristic remissions, and died on the ninth day, of septic pneumonia. At the time of the operation, and at all times later, the exposed part of the lateral sinus looked normal. The autopsy showed that the septic thrombus was a partial one and adhered to the inner wall of the sinus. This explains why the outer wall appeared healthy. In the course of the jugular vein no signs of disease were discoverable. The ophthalmoscope showed no venous engorgement. Under these circumstances, the diagnosis of pyæmia from absorption of septic material from other parts of the diseased temporal bone was justifiable.

DISCUSSION.

Dr. Knapp:—Concerning the lateral sinus, I have seen it exposed in a remarkable case under the care of Dr. Toreck. It was that of a boy who had had chronic otorrhœa for a long time, and afterwards such severe cranial symptoms that I, being consulted, advised operation. There was no pyæmia; no sudden rise and fall of temperature, but a constant elevation of temperature, headache, nausea, apathy, delirium. The boy collapsed. An opening was first made over the left ear and the temporo-sphenoidal lobe was exposed and an aspirator needle introduced in four directions, but no pus was found. I then advised that the cerebellum and lateral sinus be opened. The lateral sinus was exposed for an inch of its

length. There was no pulsation. It felt soft and there was no evidence of thrombosis. The needle was then introduced into the cerebellum above and below the sinus, but no pus was found. This ended this operation. The patient did perfectly well and recovered from the symptoms for four or five weeks, when they returned. Then the same operation was done on the right side, with the same result. There was no reaction from the operation. The last operation was done a short time ago. Both openings have healed very nicely and the boy is improving but not cured. There are still some of the old symptoms and now the boy squints a little.

This is one of those cases where we see distinctly that the most difficult and important point is not the operation but the diagnosis. The operation can be done with impunity. It often happens that no pus is found, but that later, when the case terminates fatally, the abscess is discovered.

Dr. J. Orne Green:—I am glad to hear Dr. Knapp's remark that the diagnosis is the thing in these cases. This has not been emphasized by the general surgeon as much as it should be. This operation of opening the brain in otitic cases is largely exploratory. In a large number of cases where you think that you have made the diagnosis, you do not find what you expect, and there are other cases perfectly amenable to treatment where you can not make a diagnosis. The sooner that the operation is thus regarded, the better it will be. I have had several cases of abscess of the brain where it was impossible to make a diagnosis until the fatal symptoms had set in. I have had other cases where we conceived that we had made the diagnosis but failed to find what we expected. In these otitic cases the opening of the cranium is exploratory, but it is, however, perfectly justifiable.

Dr. Gruening:—In the case reported by Dr. Knapp,

the motor symptoms may be due to the operative interference.

In a recent edition of Politzer's work, it is stated that the lateral sinus pulsates, and one of the indications for opening the sinus is the absence of pulsation. My own experience is that the healthy sinus does not pulsate and that the absence of pulsation can not be an indication for operation. I should have operated on this case had I believed that absence of pulsation is an indication for operation and probably I should have saved the woman. It was a pure case of sinus thrombosis, without any complication on the part of the brain. It is much safer to open the sinus than to expose the brain. I certainly should not have been guilty of a false step if I had performed the operation in that case.

Dr. Jack :—I remember very well a case in which the lateral sinus was supposed to have been opened, where the small clot that formed in the wound continued to pulsate for five or six days.

Dr. Reeve :—Might not the pulsation in Dr. Jack's case have been due to an anomaly in the distribution of the meningeal artery? I have seen the lateral sinus opened in several cases, but have seen no pulsation.

Dr. Mathewson :—In a case where a large opening was made by a disease of the mastoid, which subsequently proved to be epitheliomatous, there was marked pulsation in the position where the lateral sinus should be. Whether or not it was caused by some artery, I could not say. In this case the post-mortem showed the sinus to be healthy.

Dr. Gruening :—The condition seems to be that the lateral sinus pulsates at times and does not pulsate at times, and we must consider both conditions normal.

Dr. Knapp :—Is not that similar to what we find in the eyeball, where sometimes the veins pulsate and at other times they do not? The circulation of the eye and that of the brain are very much alike.

NOTES OF TWO FATAL CASES OF SUPPURATIVE MIDDLE EAR DISEASE WITH BRAIN COMPLICATIONS, AND OPERATION.

By Clarence J. Blake, M. D., *Boston, Mass.*

M. C., woman, 25 years of age. The early history of the case was indefinite, but three weeks before admission to the Aural Department of the Massachusetts Charitable Eye and Ear Infirmary she had much pain in the left ear and corresponding side of the head and was delirious for one night. On examination there was found a large, firm polyp completely filling the canal. This was removed under ether, was found to spring from the posterior tympanic wall, with a mass of secretion behind it and bare bone in the tympanic attic. Two days later, the patient was nervous, apprehensive, somewhat apathetic at intervals and complained of severe pain in the head and back of the neck, the pain becoming later definitely located in the left frontal and parietal region, and having periods of remission and exacerbation. The pupils were equal but small, and reacted to light and accommodation, and the movements of the eyeball were unimpaired. Examination of the fundus showed beginning optic neuritis in left eye, the tongue was put out in the median line, and there were no signs of paralysis elsewhere; the pulse was intermittent and varied in strength, and during the night of the same day there were two intervals of severe and persistent vomiting.

On the following day all the symptoms were intensified, and once there was a sudden collapse, in which the

extremities and face became cold and the pulse fell to 50, and could scarcely be felt. During the two following days the patient grew worse, had chills and a temperature of 106°, violent delirium and occasional periods of collapse. The pain in the head continued and the skull became tender at a point just over and in front of the left auricle. The operation, which under these circumstances was urgent, consisted, subject to the advice of consultants, in a trephine opening two centimeters in diameter and the same distance above the superior curved line of the occipital bone; the opening was enlarged by means of the rongeur, until it was five centimeters long on the horizontal line, and two and one-half centimeters in width; the dura, which was normal, bulged without pulsation. An opening in the dura showed the pia to be also normal, and was followed by immediate hernia of the brain. The subdural space and the brain tissue were thoroughly explored by means of a probe and director, but no pus was found. Subsequent exploration by means of aspirator needles, carried inward, forward, and downward, and once into the lateral ventricle, also failed to liberate the pus, which was found at the autopsy five days later, to form a circumscribed flattened subdural abscess covering the first and second left frontal convolutions and in such position therefore that a trephine opening made further forward would have directly liberated it, and would also have given access to a carious spot upon the tegmen tympani. As the result of the operation and the corresponding relief from pressure, accompanying the brain hernia, the patient was restored to consciousness for thirty-six hours, with but slight intervals of delirium, amounting in all to but one hour. There was also temporary relief from the pain, nausea, and vomiting.

R. B., man, 21 years of age. Strong, well built, of good general health, had a discharge from the right ear of one week's duration, accompanied by severe pain referred to the depth of the ear.

On examination, there was found to be slight tenderness of the pre-auricular region and decided tenderness of the mastoid tip and antrum. The canal was filled with purulent discharge exuding through a well marked nipple in the posterior inferior portion of the membrana tympani, and the temperature was 101°. On the following day, the patient having in the meantime been admitted to the Infirmary, there was slight pain only, and no tenderness of the mastoid. During the morning of the same day there was a light chill, accompanied by a rise of temperature to 104°, and two hours later to 106°. This elevation of temperature was unaccompanied by pain or nausea, and the condition of the ear was to all appearances the same as when first examined. A thorough general examination revealed nothing abnormal in either the thoracic or abdominal cavities. An operation upon the mastoid was decided upon in consequence of the sudden rise in temperature. The operation consisted in the usual proceedures, the bone of the cortex and outer portion of the cells being found to be normal, and softened bone being found only on approaching the antrum, which was thoroughly curetted, communication being freely established with the middle ear.

The effectiveness of the operation for the proposed purpose was shown by a fall of the temperature of three degrees within two hours after the removal of the patient from the operating room, by a corresponding relief of the other symptoms for a period of five days, at the end of which time the condition changed, the patient became suddenly comatose, with a diffusive and irregular pulse, and corresponding respiration. There was twitching of

the right side of the face, especially of the right upper lip, and also of the thumb and first two fingers of the right hand, this hand also being occasionally suddenly flexed; there was marked reflex of both hands and forearms, an apparent paralysis of the tongue, and inability to swallow; the pupils were dilated but equal and reacted to light; there was neither nausea nor vomiting, and no apparent evidence of pain.

A curvilinear incision was made from the root of the zygoma to a point over the mastoid, and a trephine opening, two centimeters in diameter, was made directly over the external auditory meatus. The dura bulged slightly but was apparently normal, and without pulsation. Careful examination of the petrous surface, by means of the blunt probe, revealed no carious bone, but an incision through the dura was immediately followed by a jet of clear serum, which spirted to a distance of between two and three feet, and continued to exude whenever the subdural space was explored. No pus was found and the brain was not entered. As the result of the operation, the patient was restored to consciousness, and conversed rationally for five or six hours, after which time he relapsed into his former condition, and died thirty-six hours after the operation. The autopsy showed acute diffuse purulent leptomeningitis of the right hemisphere.

STATISTICS OF THE AURAL DEPARTMENT OF THE MASSACHUSETTS CHARITABLE EYE AND EAR INFIRMARY FROM APRIL 1 TO JULY 1, 1893, WITH REMARKS.

By Clarence J. Blake, M. D., *Boston, Mass.*

Following are statistics of the Aural Department of the Massachusetts Charitable Eye and Ear Infirmary from April 1 to July 1, 1893.

Diseases of Out Patients, Ear Department.

APRIL 1 TO JULY 1, 1893.

I. MORBI AURIS EXTERNÆ.

I. AURICULÆ.

a. Inflammationes.

	A. D.	A. U.	A. S.
Eczema acutum vel chronicum	1	3	1
Abscessus auriculæ	1	0	2
" conchæ	0	0	1
" lobuli	1	0	2
" tragi	2	0	0
Hæmatoma idiopathicum	1	0	1

b. Deformitates.

Microtia	1	0	0

c. Neoplasmata.

	A. D.	A. U.	A. S.
Fibroma lobulæ	0	1	0

2. MEATUS A ANOMALIÆ SECRETIONUM.

a. Anomaliæ Secretionum.

Accumulatio ceruminis	82	111	82

b. Inflammationes.

Eczema acutum vel chronicum	2	11	4
Otitis externa diffusa acuta	6	6	9
" " " chronica	0	1	0
" " follicularis	11	1	5
Abscessus meatus	3	0	3
Corpus adventitium animale	0	0	1
" " inanimale	9	0	3

3. MEATUS—OSSIS.

Exostosis circumscripta	1	0	0

II. MORBI AURIS MEDIÆ.

1. MEMBRANÆ TYMPANI.

Myringitis acuta	0	0	1
Trauma indirectum	5	0	3

2. TYMPANI, TUBÆ EUSTACHII, ET PORTIONIS MASTOIDEÆ.

Otitis catarrhalis secernens mucosa acuta	1	4	1
Otitis catarrhalis secernens mucosa cum hyperplasia tonsillæ pharyngeæ	0	7	0
Otitis catarrhalis secernens mucosa ex tuba	2	5	1
Otitis catarrhalis serosa acuta	7	15	6
Otitis catarrhalis mucosa chronica	49	204	53
Otitis catarrhalis mucosa chronica cum hyperplasia tonsillæ pharyngeæ	1	28	0
Otitis catarrhalis adhæsiva ex secernente	2	16	5
Otitis catarrhalis adhæsiva insidiosa	5	15	3
Otitis media acuta simplex	53	22	66
Otitis media acuta cum bulla	2	0	0
Otitis media acuta cum ostitide mastoidea	3	0	4

	A. D.	A. U.	A. S.
Otitis media suppurativa acuta	22	2	25
Otitis media suppurativa chronica	139	90	108
Otitis media suppurativa chronica cum abscessus post auriculam	2	0	0
Otitis media suppurativa chronica cum carie vel ostitide mastoidea	6	1	11
Otitis media suppurativa chronica cum carie mastoidea et meningitide	0	0	1
Otitis media suppurativa chronica cum carie ossiculæ	5	1	4
Otitis media suppurativa chronica cum atresia meatus	1	0	0
Otitis media suppurativa chronica cum polypo tympani	12	0	7
Otitis media suppurativa chronica cum granulatione tympani	6	1	6
Otitis media suppurativa chronica cum hyperplasia tonsillæ pharyngeæ	1	3	4
Effectus otitis mediæ suppurativæ	24	33	27

3. NEUROSES AURIS MEDIÆ.

Otalgia dentalis	7	0	3
" neuralgica	3	3	2

III. MORBI LABYRINTHI ET ACUSTICI.

Hæmorrhagia	0	0	1
Panotitis	0	0	1
Propriæ notæ Ménière	0	0	2
Surditas totalis	0	4	0

IV. MORBI NASI ET NASO-PHARYNGIS.

Atresia nasi	0	0	1
Hyperplasia tonsillæ pharyngeæ	0	1	0
Rhinitis hypertrophica	0	7	0
" atrophica	0	12	0

MISCELLANEOUS.

Unfit patients	0	67	0
No ear disease	0	6	0
No diagnosis	0	3	0
Eloped	0	3	0

MORBI ET OPERATIONES.

	A. D.	A. U.	A. S.
Auricula, abscessus, incisio	1	0	1
" hæmatoma idiopathicum, incisio	1	0	1
" fibroma, remotio	0	1	0
" perichondritis, incisio	1	0	0
" synechia, incisio	1	0	0
Calvarium, trepanatio	1	0	0
Cervix, abscessus, incisio	1	0	0
Concha, " "	0	0	1
Lobula, " "	1	0	2
Meatus, " "	1	0	5
" atresia, incisio	1	0	0
" corpus adventitium animale	0	0	1
" " " inanimale	9	0	3
" otitis externa diffusa acuta, incisio	0	0	2
" " " follicularis	2	0	3
" polypus, remotio	0	0	1
Membranæ tympani, bulla, incisio	1	0	0
" " paracentesis	23	1	23
Mastoidea, apertio	7	1	11
" necrosis, remotio	0	0	6
Nasus,—polypus, remotio	0	1	0
Hypertrophia tonsillæ pharyngeæ, remotio	0	25	0
Ossiculæ, necrosis, remotio	9	0	5
" ankylosis, mobilizatio,	7	0	9
Post auriculam, abscessus, incisio	2	0	5
Tonsillæ hypertrophia, remotio	0	1	0
Tragus, abscessus, incisio	2	0	2
Tympanum, granulatio, remotio	2	0	3
" polypus, remotio,	10	0	10
Total number of operations		208	

Diseases of Aural House Patients.

APRIL 1 TO JULY 1, 1893.

I. MORBI AURIS EXTERNÆ.

a. AURICULÆ.

	A. D.	A. U.	A. S.
Synechia	1	0	0
Fibroma lobulæ	0	1	0

b. MEATUS.

Otitis externa diffusa acuta	0	0	2

II. MORBI AURIS MEDIÆ.

TYMPANI, TUBÆ EUSTACHII, ET PORTIONIS MASTOIDEÆ.

Otitis catarrhalis mucosa chronica	2	4	2
Otitis catarrhalis adhæsiva ex secernente cum morbo labyrinthi	1	0	0
Otitis media acuta simplex	3	0	2
" " " cum carie mastoidea	1	0	2
" " " " ostitide mastoidea	5	1	4
" " " " meningitide	0	1	0
" " suppurativa acuta	0	0	1
Otitis media suppurativa acuta cum abscessu post auriculam	0	0	2
Otitis media suppurativa acuta cum carie mastoidea	1	0	1
" " " " " ostitide mastoidea	1	0	4
" " " chronica	3	1	3
" " " " cum atresia meatus	1	0	0
Otitis media suppurativa chronica cum abscessu post auriculam	1	0	1
Otitis media suppurativa chronica cum carie mastoidea	3	1	13
Otitis media suppurativa chronica cum carie meatus et abscessu cervicis	0	0	1
Otitis media suppurativa chronica cum carie mastoidea et abscessu cervicis	1	0	2
Otitis media suppurativa chronica cum carie mastoidea et thrombosi venæ jugulæ	0	0	1
Otitis media suppurativa chronica cum carie ossiculæ	12	1	4
" " " " " eczema meatus	0	0	1
Otitis media suppurativa chronica cum granulatione tympani	0	1	0
Otitis media suppurativa chronica cum ostitide mastoidea	4	0	13
Effectus otitis mediæ suppurativæ	4	8	4

NUMBER OF HOUSE PATIENTS.

Male	72
Female	41
Total	113

NUMBER OF OUT PATIENTS.

APRIL.		
New patients	434	
Visits from new and old patients		2,419
MAY.		
New patients	540	
Visits from new and old patients		2,728
JUNE.		
New patients	440	
Visits from new and old patients		2,538
Total new patients	1,414	
Total visits		7,685

REMARKS.

The out-patient clinic has presented fewer acute cases than in the years 1890, 1891, and 1892, when the prevailing epidemic of influenza largely increased the number; but in the nearly fifteen hundred new cases were seen one hundred and fifty cases of otitis media acuta, with involvement of the mastoid process in seven. Three hundred and sixty cases of otitis media suppurativa chronica were seen during the three months, with implication of the mastoid process in twenty-one, and necrosis of the ossicula in fourteen.

The use of cold applications to the mastoid has yielded very good results, the Leiter coil or the rubber ice cap devised by Dr. Sprague having been the most frequent modes of using this treatment.

Two cases of meningitis seen during the three months deserve more extended notice.

The first was that of a child eleven years of age, with no history of former trouble of the ear. Two days before being seen, he had very violent earache in both ears, with discharge from the left ear one day later. Paracentesis was performed on the right ear on the second day of the disease, at which time there were already present undoubted symptoms of meningitis, namely, a temperature of 104°, vomiting, very severe headache, and active delirium. There was slight improvement after paracentesis for a few hours, then, on the third day, the child again became actively delirious, the pupils were equal and reacted well, both ears were discharging freely, there was no tenderness of the mastoid or skull, and no signs of paralysis, but the child had a typical cephalic cry. The case was admitted to the house; the treatment consisted in the use of ice cap, bromide in large doses, and stimulants. On the fourth day, there was a slight paresis of the left side of the face, pupils widely dilated (left more than the right), general muscular twitching, tenderness of the right side of the skull, pulse irregular and at times intermittent, and constant nausea and vomiting, so that the child had to be fed by nutrient enemata. In view of these symptoms, and of the fact that the child was failing rapidly, operative measures seemed advisable. The child etherized easily. The head was shaved and scrubbed with 1 to 2000 solution of corrosive sublimate. The temporal and mastoid regions on the right side were exposed by a large curved incision from the zygomatic process in front of the auricle, back to the occipital region. The periosteum was retracted, and the mastoid process and the skull, in the temporal region, were opened at the same time by two surgeons. No pus was found in the interior of the mastoid, and the bone was fairly normal. The skull opening was enlarged by the gouge and rongeur to a diameter of about two inches. The brain bulged and did not pulsate, the dura

mater seemed normal, and upon opening it serum escaped freely and purulent infiltration along the veins of the pia mater was plainly seen. The roof of the tympanum and of the mastoid were explored with a probe, and bare bone was found in one spot over the tympanum; the brain was then explored with a trocar to the depth of about two inches, but no pus was found. The flap was stitched back and pressure applied. The child bore the operation well, but during the next twelve hours failed rapidly, did not respond to stimulants, and died twenty-four hours after the operation. A partial autopsy showed purulent leptomeningitis, involving the right base, temporal sphenoidal lobe, and convexity. The point of infection was through a small spot of soft gray bone, about four millimeters in diameter, in the roof of the right tympanum.

The second case of meningitis was in a boy 14 years of age, who walked into the out-patient clinic at the close of a busy morning. There was a history of chills, night-sweats, and severe headache for the three weeks previous. There was an abscess over the left mastoid of some weeks' duration, which had been opened by the family physician by a simple incision, without ether. At this spot, there was a suppurating wound about one-half inch long, through which bone could not be felt. The boy's general appearance was that of a severe shock, on account of which no thorough examination was made. He sat in the chair, perfectly rigid, not moving his head or back in the least. There was a marked tenderness along the posterior border of the left sterno-cleido-mastoid muscle, and along the cervical and dorsal spine. The boy was put to bed, stimulated, and further examination temporarily deferred.

About two hours later the boy suddenly went into a state of collapse, from which he did not rally, in spite of stimulative treatment, and died fifteen minutes later. An

autopsy made that night showed a moderate sized polypus in the tympanum, not sufficient to block the purulent discharge, and caries of the tympanic walls. On stripping back the fascia from the mastoid process at the point of the former incision, there was found a sinus in the external cortex of the bone large enough to admit a No. 9 Bowman probe, and the probe could then be passed into the tympanum, the mastoid process being a mere shell. There was also perforation of the inner side of the mastoid process into the sigmoid groove, purulent thrombus in the lateral sinus extending into the internal jugular vein, with organized thrombus of the superior and inferior petrosal sinuses, and of the transverse sinus on the left side; also a purulent meningitis extending over the medulla and pons, and probably down the spinal column. Examination of the thorax and abdomen was perfectly negative.

Of the twenty-five operations on the mastoid process reported, two of especial interest were in that form of mastoid caries first precisely described by Bezold, and with the complication of cervical abscess. In the first, an ounce of fetid pus was removed from the neck by an incision over the posterior border of the sterno-cleido-mastoid muscle at about its middle. The perforation of the mastoid was discovered in the digastric groove and no pus was found in the interior of the bone. The mastoid process healed in five days, and the neck in twelve days.

The second case had evident caries of the mastoid process with cellulitis in the neck. The bone was opened in the usual manner, with the gouge and curette, and a drachm or more of pus was found. A prolongation of the mastoid incision downward into the neck to a point one and one-half inches below the tip of the mastoid failed to reveal pus. On searching the mastoid more carefully a perforation was found on the inner side of the mastoid process one-quarter of an inch above the tip,

large enough to admit a large surgical probe, which probe broke into an abscess cavity in the neck, evacuating a small amount of fetid pus. The probe could then be passed three or four inches into the neck under the sterno-cleido muscle, but no further pus was found. This case also had slight consolidation at the apex of the left lung, with cough, and has not yet (one month later) thoroughly healed, although the cellulitis in the neck has disap peared.

A CONTRIBUTION TO THE BRAIN SURGERY OF EAR DISEASE.[1]

By Thomas R. Pooley, M. D., *New York, N. Y.*

The glorious uncertainty which may accompany the attempt to reach by surgical interference pus foci which result from ear disease, and are hidden away somewhere in the brain, are so well illustrated by the experience afforded in the following case that it is quite as well (perhaps more so) worth reporting than if the operation had been successful. It is for this reason rather than for anything new in the method of operating or otherwise unusual in the case that it is reported.

The patient, a young gentleman of 29 years, came to me by the advice of his family physician on March 28, 1893. He was suffering from an acute otitis media purulenta of the left ear which he attributed to an attack of grip which occurred three weeks ago. About a year or so before, he had contracted syphilis, for which he was under treatment, of which he showed secondary symptoms. There was profuse purulent discharge, swelling of the posterior wall of the auditory canal, and a good sized perforation of the anterior inferior segment of the membrana tympani. He complained of pain in and around the ear, and there was pain on deep pressure over the apex of the mastoid process, although it was not swollen. There was, too, a rather severe pharyngitis, with swelling of the mucous membrane and a number of mucous patches.

The treatment adopted was the thorough cleansing of the ear by means of a fountain syringe with a bichloride solution 1-3000, the application of a leech to the tragus,

[1] Read by title.

spraying of the nose and throat with Seiler's tablets, and rest in bed in a warm room. He had been going about attending to his business. Besides, he was advised of the danger of mastoid extension and the possibility of an operation becoming necessary. Under this treatment he immediately improved, the discharge gradually lessened, the swelling of the canal went down, and the tenderness over the mastoid disappeared. So that after remaining under treatment as an in-door patient for about ten days or two weeks, at his earnest solicitation he was allowed to go again to his business and came to the office for treatment. There was now a return of the unfavorable symptoms and an operation was proposed, but he was so averse to having it done that he again remained at home, and once more there was temporary improvement.

On April 26th, he sent for me in the evening on account of severe pain and swelling behind the ear. I now found diffused swelling over the mastoid, with great pain on pressure, especially over the apex, extending backwards and involving the entire left side of the head. His pulse was rapid, temperature 100° or more, and the expression gave evidence of great suffering. An immediate operation was now insisted on and consented to.

The day following, with the assistance of Drs. L. Walton and S. J. Gittelson, the mastoid was opened by Schwartze's method. Upon cutting down through the infiltrated tissues to the bone there was an escape of pus. The bone was soft and the outer cortex easily penetrated, when immediately upon entering the antrum a large quantity of stinking pus escaped; the cavity was freely enlarged by the chisel in the direction of the apex, and the whole cancellous portion of the bone was found to be full of pus. With a sharp spoon all the carious bone was removed, and free communication established with the middle ear. The wound was then carefully and thor-

oughly irrigated with a bichloride solution, a tent of iodoform gauze inserted, a pledget of the same placed over the wound, and then a large wad of absorbent cotton, the whole being retained by a roller bandage firmly applied. There was nothing unusual nor difficult in the performance of the operation, which occupied about half an hour after the patient was etherized. There was, however, a good deal of difficulty in putting him under the influence of ether. He took a large quantity and struggled against it, so that the process was long and tedious. The real trouble, however, began after the operation,—respiration was slow, his surface became cold and covered with a clammy perspiration, and his pulse, which was slow and intermittent, was soon almost imperceptible at the wrist. Several times his respirations seemed to have ceased altogether, and he was apparently dead. It required the most strenuous efforts to resuscitate him by the use of hypodermics of brandy and digitaline and artificial respiration. At least an hour was required to fully accomplish his resuscitation, for time and again he sank into a state of collapse.

On the following morning, his pain was entirely gone, he had slept fairly well, and his temperature was only slightly above the normal. It is a matter of regret that the temperature charts, which were carefully kept by a trained nurse, were lost, so that an accurate detail of his pulse and temperature cannot be given. The dressing was not disturbed at the morning visit, but in the afternoon, about twenty-four hours after the operation, the wound was dressed. It looked very well, and, when the tent was removed, discharged quite freely. The discharge from the auditory canal had very much diminished. The wound was irrigated with a bichloride solution 1-3000, as was also the auditory canal. There was a free drainage from the canal through the wound, and vice

versa. Temperature about 101° F.; pulse 100. Appetite poor. Whiskey, milk, and beef tea ordered.

From this time forward until the eighth day after the operation the progress of the case was most favorable. The wound was thoroughly irrigated twice daily, the discharge daily decreasing. From the meatus it had altogether stopped. The pulse and temperature were normal, or but a fraction above it in the course of the day. Appetite had improved, and everything looked favorable to a rapid recovery. The wound was already rapidly healing, and a silver drainage tube was inserted through which there was perfect drainage. During the day, May 6th, he sat up for a few hours in the afternoon, and felt very well. Upon going to bed again, however, he felt very much fatigued; during the night had a slight chill, followed by fever, and when I saw him early the next morning there was a decided change for the worse. His temperature was about 101½° and pulse a little over 100. He complained of headache and pain in the back of the eyes. During the night he had vomited, and still suffered from nausea and dizziness. The latter symptom was especially annoying, and he absolutely refused to take any nourishment or stimulants.

A careful inspection of the wound was made to ascertain whether the unfavorable turn in affairs was due to the retention of pus, but there was found to be most perfect drainage, and no pent up pus was liberated. The discharge had, however, become rather less. One grain doses of oxalate of cerium were administered every hour to relieve the nausea and phenacatine and quinine to bring down his temperature, and champagne substituted for the brandy. In the afternoon at 3 P. M. he was decidedly better, the temperature and pulse were nearly normal, and both the nausea and vertigo were better. The day following, his condition remained very much the same, with the notable

and significant change in temperature which was now sub-normal, about 98½°.

From this time until a day or two before his death, it ranged from normal to sub-normal, being most of the time below the normal. His pulse, on the contrary, was frequent, about 100 or more. The nausea and vertigo were somewhat less, but he now had severe pain in the head which he referred to the frontal and occipital regions. I could, however, find no point which was sensitive to palpation.

The symptoms seemed to point at this time to cerebral irritation, with the possibility of pus having formed somewhere within the cranial cavity, but there seemed to be no symptoms pointing to a definite locality. The sub-normal temperature, in spite of the œdema of the temporal region which occurred later, did not seem to warrant the diagnosis of thrombosis of the lateral sinus.

It would be too tedious to enter into the daily detail of the symptoms which, too, would lose much of their value because of the loss of the temperature charts. Besides the symptoms already enumerated, the patient had sunken into a state of semi-stupor, from which he could be aroused and was able to answer questions fairly well. There was a steady progress for the worse, until it seemed to be necessary to call a consultation for the purpose of deciding whether an exploratory operation was justifiable to see whether the pus focus in the brain could be found, as this seemed to be the only means of relief now at hand. I had already urged this upon the family, but it had been delayed until his mother, who was in a distant city, could reach his bedside.

A few days before the consultation, which was on May 22d, there was a marked œdematous swelling over the temporal region, which was very marked and painful to the touch, but this disappeared temporarily under the use

of hot applications. On May 22d, Dr. B. Sachs and Dr. Robert Abbe saw him with me in consultation to decide whether an operation should be done. Dr. Sachs has kindly furnished me with the following notes of his examination. "At the time of my first examination, May 22d, I found that the œdema which had been present had disappeared; that there was slight pain on pressure over the external auditory meatus on the left side (a symptom not observed by me). The patient was in a condition of semi-stupor, from which he could be roused and was able to answer most questions fairly well. There was nothing abnormal about the knee-jerks, both sides being lively, but not unusually exaggerated; the two knee-jerks were moreover equal. The temperature had been sub-normal but was approaching the normal. The pulse was very rapid but fair in volume. There was no marked retraction of the neck, but evidently some hesitation in moving the head from one side to the other. At this period there was no marked ocular palsy. The only just inference from these symptoms in view of the preceding history was that meningeal irritation existed in connection with the ear trouble. There seemed to be a possibility of pus having formed somewhere within the cranial cavity, but there were no symptoms pointing to any definite locality."

These notes of Dr. Sachs so well describe the condition of affairs at this time that it is only necessary to add that there was no choked disc. Repeated ophthalmoscopic examinations had been made, and at this time there was no diplopia nor squint. Repeated examinations failed to find any paresis of the ocular muscles. In the consultation, it was agreed to between all three of us that as the patient had been slightly improving for the last few days, it seemed more prudent to defer operative interference and to await further developments, and, further, in the light of the specific history, as well as on account of

the difficulty of locating the cerebral process, to administer large doses of iodide of sodium for a few days, fifteen drops every hour,—Dr. Abbe, whose experience in operations of this sort had been quite large, fully concurring in this course.

The course of treatment agreed on in the consultation was put into effect, but the iodide seemed to have no effect whatever upon the unfavorable progress of the patient. On the contrary, he gradually sank into a more marked state of coma. It was with difficulty that he could be aroused. He seemed to be aware of what was going on, answer questions laconically, and then relapse again into semi-coma.

On May 27th, for the first time convergent squint was noticed and paresis of the externus of the left side found. It was observed, too, that there seemed to be some difficulty in moving the left arm. Inasmuch as the patient was rapidly failing and an operation seemed to be the only resource, another consultation was called on May 28th, at which all three of the former consultants were present. There was now profound coma, with stertorous and irregular respiration. Retraction of the head was very marked; there was distinct circumscribed œdema over the left temporal region. On account of the coma, it was impossible to say whether any part of the head was painful or not. There was in addition to the paresis of the left externus, insensibility of the cornea, which could be demonstrated in spite of the coma, for when the cornea of the left side was touched no objection was made, whereas he immediately closed the lids when the right was touched. There was an appearance of slight paresis of the left side, but this was not distinct enough to be considered of much value in the diagnosis, as the patient was able to move both lower and upper extremities while lying on his back; sensation was not disturbed at any

time. The deep reflexes were increased on both sides, while the superficial reflexes of the lower extremities were lost.

The conclusion from this second consultation was that the condition had grown very much more grave; that there was every likelihood of pus formation in the parts adjacent to the ear disease, but it was impossible to say whether the pus was on the outer surface of the temporo-sphenoidal bone or whether some of it had not been formed at the base, to which region the involvement of the cranial nerves pointed. The question of sinus thrombosis was thoroughly discussed, but the symptoms, in spite of the œdema, did not seem to us to warrant that diagnosis.

Although it was thought by all that an operation was the only means of relief, still it was mutually agreed upon to wait still one day longer, and on account of the difficulty of locating the lesion from the symptoms, and because of the existence of syphilis, to try mercurial inunction, and if this should be of no use to operate the following day. This was accordingly most rigorously done, but it had no effect whatever and the operation was performed the following day, May 29th, at 3 P. M. In accordance with the request of the family, Dr. Abbe made the operation, assisted by Drs. Sachs, Fisk, Gittelson, and myself. Ether was given, the patient being in profound coma while in his bed, before he was put upon the operating table. He bore the anæsthetic well, his pulse, which was very rapid, becoming slower and steadier while it was being administered. Most thorough antiseptic precautions were observed, both in the preparations for and throughout the progress of the operation.

Before the operation the entire left side of the head was closely shaven. Beginning at the upper margin of the wound which had been made in opening the mastoid the

incision was extended over the region of the temporal and parietal bones so as to gain access to the temporo-sphenoidal lobe of the brain, a flap was then dissected up, the periosteum reflected, and a button of bone removed by a trephine, after which the opening thus made was made larger by the use of a rongeur, and the dura exposed. A probe was now carefully carried between the dura and the skull in search of any pus accumulation in the extra dural space, but none was found and the probe showed no evidence of having come in contact with any dead bone and was perfectly free from any odor. A large hypodermic syringe was now passed into the brain substance for a considerable distance, in several directions, at first without withdrawing any fluid, but when directed towards the ventricle drew out the entire syringe full of a clear, watery, colorless looking fluid which both Drs. Abbe and Sachs at first thought might be the fluid from an encephalic cyst, but was no doubt only the fluid from the ventricle. As this part of the operation was negative, the operation was extended so as to lay bare the lateral sinus, which was accomplished by first opening the site of the mastoid operation, which was found to be nearly filled with healthy granulations, without any accumulation of pus, and perfectly free from any evidence of necrotic bone. Access to the sinus was obtained by cutting away the bone in the direction of the same with a rongeur. The bone was found to be hard and perfectly healthy. When the sinus was exposed the needle of the hypodermic syringe was passed into it, and perfectly odorless, healthy fluid blood withdrawn, thus showing conclusively the absence of thrombosis of this sinus. The fluid withdrawn by Dr. Abbe was reserved for examination but I have not heard the result of the examination. No doubt, however, exists in my mind that it was nothing more than the fluid from the ventricle, which I

am told by several operators they have drawn off in the same way in their explorations for cerebral abscesses.

Upon the conclusion of the operation, which was necessarily a protracted one, the patient's pulse was very rapid and feeble, and the coma persisted. The wound was carefully adapted by sutures, and dressed with antiseptic gauze and bandages firmly applied. After the patient was put to bed, several hypodermics of brandy were given. The case was left in the care of Dr. Abbe and his assistant, Dr. Fisk. He never came out of the comatose state, and died early the following morning. An autopsy was refused by the family, and therefore the exact location of the lesion which caused death remains a mystery.

There can be no shadow of doubt, however, that though we found nothing at the operation, the focus of pus was hidden away somewhere in the brain, probably at the base, where it was beyond the reach of the surgeon. The occurrence of the paresis on the same side as the affected ear was especially puzzling, while none of the symptoms were of such a character as to enable us to locate the disease, except that the affection of the cranial nerves was in favor of an abscess at the base. Choked disc was never observed, although frequent ophthalmoscopic examinations were made up to a day before his death. As already pointed out, sinus thrombosis was excluded, on account of the absence of accelerated pulse, high and rapidly rising and falling temperature, frequent chills, etc. The only symptom favorable to this view was the temporary œdema, which was not, however, characteristic either.

It must be borne in mind, too, in speculating as to the lesion in our case, that Bergman and others have reported cases of brain abscess from disease of the middle ear, the abscess being on the opposite side. (See remarks by Dr.

Fryer in the discussion on Mastoid Diseases, Transactions American Otological Society, 1892, page 267).[1]

Such experience as is afforded by this case goes to teach that the difficulties which environ the locating of cerebral abscess and other lesions hidden away in the brain as they occur in ear disease can hardly be exaggerated, but attempts to reach the pus in the cranial cavity alone offer any chance of saving the patient, and although the successful cases may be few, the further cultivation of all the means at our command to localize such diseases and improvement of the operative measures to get at them is worthy of more extended cultivation.

---

[1] In stating thus positively my own view of the cause of death, I wish to add that Dr. Abbe inclines to another one. He is of the opinion, in view of the absence of any evidence of extension of disease from the ear being disclosed by the operation, together with the large amount of fluid withdrawn from the ventricle, that it was due to syphilis of the choroid plexus with ventricular distension.

NOTES ON THE COMPARATIVE ANATOMY OF THE OSSICLES.

By Lucien Howe, M. D., *Buffalo, N. Y.*

As comparative anatomy frequently gives important hints concerning the functions of different portions of our bodies, and as many questions still remain unanswered concerning the physiological and pathological action of the ossicles, it occurred to me it would be of interest to look over the various works on comparative anatomy to obtain what facts were possible in regard to the ossicles in various animals, their size, form, position, etc. On attempting to do this, I was surprised to find how little had been written on the subject, and I thereupon made some effort to obtain the ossicles from animals of widely different species and have succeeded thus far in securing a more or less complete set of the following. They are:

MAMMALS.

Orang (Pithecus satyrus). Malleus and incus.

Dog (Canis familiaris L.). Malleus, incus, stapes, and cochlea.

Cat (Felis domesticus). " " "

Grizzly bear (Ursus horribilis). Incus and stapes.

Pig (Sus scrofa). Malleus, incus, stapes, and cochlea.

Bowhead whale (Balæna mysticetus L.). Malleus, incus, stapes, and cochlea.

Otter (Lutra Canadensis). Malleus and incus joined.

Harbor seal (Phoca vitulina). Malleus, incus, stapes, and cochlea.

Jamaica seal (Monachus tropicalis). Malleus, incus, stapes, and cochlea.

Walrus (Trichechus rosmarus). Malleus, incus, stapes, and cochlea.

Brown rat (Mus decumanus, Pallas). Malleus, incus, stapes, and cochlea.

Ox (Bos taurus L.). Malleus, incus, stapes, and cochlea.

Deer (Cervus Virginianus). Malleus, incus, stapes, and cochlea.
Sheep (Ovis aries). " " " "
Rabbit (Lepus cuniculus L.). " " " "
Moose (Alces malchis Ogilby). Incus and malleus.
Mule deer (Cervus Macrotsay). Malleus, incus, stapes, and cochlea.
Elk (Cervus Canadensis Erxt). Malleus, incus, stapes, and cochlea.
Porpoise (Phocæna phocaina L.). " " " "
Woodchuck (Arctomys Monax). Malleus and incus.
Beaver (Castor fiber L.). Malleus, incus, stapes, and cochlea.
Armadillo (Dasypus (sp?)). " " " "
Lemur (Lemur (sp?)). Malleus, incus, and cochlea.
Aard vark (Orycteropus capensis). Malleus, incus, stapes, and cochlea.
Elephant (Elephas giganticus). Malleus and incus.

I present the bones because of the possible interest in themselves, and also to call attention to one or two peculiarities which may be worthy of mention.

First. As to the processus longus of the malleus, concerning which there is some difference of opinion. Gruber has described this long process of the malleus as bony in early life, considering that later it degenerates into connective tissue and is then to be regarded as a ligament. A study of comparative anatomy appears to indicate that this is the true view to be taken, for here we find in one or two specimens this long process persisting as a true bone. As in other instances, comparative anatomy on the one side and the adult human anatomy on the other side, have a connecting link in the embryo or in the human anatomy of early life. This is noticeably the case with the seal and particularly so with the cat.

Second. Concerning the malleo-incudal joint. In Helmholtz's beautiful monograph on the mechanism of the ossicles of the ear he devotes considerable space to a discussion of the attachment of the malleo-incudal joint and explains with much detail the manner in which this joint is so constructed in the human being that rotation in one direction is practically unlimited, while in the other

direction it is suddenly arrested. The details of this discussion are too elaborate to cite here, but he considers this as an essential portion of the mechanism, and shows that the principle involved can be demonstrated on the dry bones, to a certain extent, as well as on those where the ligaments are still fresh. An examination of the specimens here presented shows that with the orang and with some of the higher air-breathing animals this observation can be verified, but not with the bear, armadillo, porpoise, and some others.

Third. It is worthy of note that while the general form of the hammer and the anvil differ very greatly, not only in different genera but also in individuals of nearly allied families, on the other hand, the stapes is remarkable in having almost always a certain approach to the stirrup form. With the white whale, it is true, there is no perforation of the bone showing the two arms of the stirrup, but this perforation is visible in the porpoise, and the opening between the arms of the stirrup is well marked in the seals. Some of the very minute bones, however, show this stirrup form, in a remarkable degree; for example, in the mule, deer, and the rabbit.

That the mechanism of the bones of the ear is not as well understood as might be desired, is shown by Helmholtz in the monograph already referred to. This he commences by referring to the papers of Reimand, in which the latter opposed some of Helmholtz's views, expressed in the "Lehre der Tonempfindungen," and the latter, with his characteristic candor, admits that his facts there stated were "simply preliminary, and gathered from various sources," and in the monograph mentioned an attempt is made to supply the lacking data by the more complete study of ossicles.

I venture, therefore, to present this very imperfect collection, because of their possible intrinsic interest, and also

with the hope that, as data are accumulated by other slight additions, some further light may be thrown on the obscure questions continually presented to us regarding the physiology and therefore the pathology of the bones of the middle ear.

DEMONSTRATION OF PATHOLOGICAL SPECIMENS.

By J. Orne Green, M. D., *Boston, Mass.*

No. 3. Bony anchylosis of malleus and incus, the result of an otitis media suppurativa chronica in a child aged five years. Removed by operation. Both processes and four-fifths of the body of the incus destroyed.

No. 5. Sequestrum removed by mastoid operation from a baby aged nine months, the result of an otitis media suppurativa chronica; healing perfectly. The vestibule and two of the semi-circular canals are distinctly seen.

No. 6. Sequestrum, the result of an otitis media suppurativa chronica; removed by displacing the auricle and chiseling away the upper and posterior meatus. Healing perfectly.

No. 7. Sequestra from an otitis media suppurativa chronica, removed by the mastoid operation. One sequestrum shows a part of the labyrinth.

No. 10. Sequestrum, including the cochlea and nearly the whole cancellated structure of the temporal bone, from a case of otitis media suppurativa chronica.

No. 13. Caries of the mastoid antrum, which caused meningitis by extension through the roof of the antrum. The mastoid antrum was opened by an operation, and the next day the skull was trephined, exposing the communication with the brain, and the trephine opening was united with the mastoid opening. There was a separate abscess in the tip of the mastoid, with caries of its floor,

and a large round opening was to be seen at this spot. This case was interesting, inasmuch as all swelling pointed to the upper part of the mastoid, where the carious opening existed. The large purulent cavity in the tip had produced no external swelling and escaped observation. Meningitis.

No. 14. Caries of the roof of the mastoid antrum. An early specimen of an attic inflammation, in my possession since 1872. Extra dural abscess and a fatal meningitis. When received, the membrana tympani was entire and there was communication with the meatus only through a small perforation of Shrapnell's membrane.

No. 16. Caries of the mastoid antrum and its roof, and extension through the latter to the meninges with fatal meningitis resulting. Operation for external sub-periosteal pus and removal of the carious bone. The purulent inflammation of the tympanum was of five years' duration. The specimen shows a high degree of osteo-sclerosis of the mastoid.

No. 17. The results of an old purulent inflammation of the tympanum years ago, with a permanent perforation of the drum-membrane and extensive calcification, also well marked osteo-sclerosis of the mastoid. Death resulted from an abscess of the temporal lobe of the cerebrum, which could not, however, be directly connected with the ear.

No. 19. Caries of the tympanic and mastoid roof and mastoid from a purulent inflammation of the left tympanum of six months' duration. The anterior wall of the osseous meatus has been removed to dissect out the membrana tympana, which showed a large central perforation,—a most important specimen, as offering a positive anatomical proof of a recovery from a meningitis of the convexity produced by caries of the tympanic roof, *although the caries remained.* Six months before death, the patient

having a tympanic suppuration of the left side, had severe headache on the left side, soon followed by delirium and other symptons of undoubted meningitis. The ear was treated by thorough evacuation and antiseptic cleansing, and after lying unconscious for about three weeks the patient recovered and resumed work, but suffered from occasional severe headaches on that side. At the autopsy, the adhesions of this meningitis were found at several points over the convexity of the left cerebrum and were confirmed by microscopical examination at the Harvard Medical school, where the specimen excited considerable interest. The patient considered the ear well, although somewhat deaf. Apparently there was no notable discharge from it, and at the autopsy, although the bone was full of pus, there was only a slight moisture in the meatus; the drum-membrane was largely destroyed.

No. 19½. The right ear of the same patient, which had been perfect till a few days before I saw him, when he had an acute suppuration of the right tympanum, for which paracentesis was done, and very soon after the mastoid was opened on account of head symptoms. He became rapidly worse with symptoms referable to the head, and after consultation I trephined the skull and found about one drop of pus outside the dura mater over the tympanum. He died the next day and the autopsy showed a purulent meningitis over the right convexity of the cerebrum. The tympanic inflammation of this ear was very intense from the beginning and for several days after the paracentesis the serum coagulated in a large mass, simulating a polypus, just external to the paracentesis opening. There was beginning caries of the tympanic roof with an inflammation of the mastoid.

No. 20. Suicide by a revolver bullet into the meatus; compound fracture of the meatus; the bullet imbedded in the tympanum and removed by displacement of the auricle

forwards. One small piece went through the tympanic roof and for about one inch into the temporo-sphenoidal lobe, producing a fatal meningitis about one week after the injury.

The presence of the bullet was demonstrated by a Nelaton porcelain probe. After extracting the lead, it was found, on comparison with a similar ball, that eight grains of lead were missing, and the autopsy showed that this had passed into the brain through the tympanic roof and set up the fatal meningitis.

I have since seen three other cases of the same injury. In the second case the bullet had flattened itself into a large mass on the promontory. Its presence was demonstrated by the Nelaton probe and it was removed in the same way as in the first case. The patient died in a few days from meningitis, and the autopsy showed that there was a fracture of the tympanic roof from the concussion. The removal of the bullets in both cases was decided upon after consultation, as they were evidently so exposed to infection from both meatus and Eustachian tube that suppuration was sure to result.

In the third case, the bullet passed through the cartilaginous meatus into the bones of the face and was never found. It apparently passed into some of the mucous cavities, for the sinus continued to discharge mucus for nearly a year and then healed. The concussion destroyed the drum-membrane, displaced the ossicles, which were never seen, and destroyed the hearing completely. Some two weeks after the injury, complete facial paralysis of that side developed, but disappeared largely in about three months. Suppuration of the tympanum lasted for several months, but then ceased. The patient is now well.

In the fourth case, the bullet passed through the lower wall of the cartilaginous meatus towards the median line, and was never found, but a Nelaton probe showing lead

in the tympanum, the auricle was displaced and a mass of lead removed equal to about one-quarter of the whole bullet. The ball had evidently struck the edge of the osseous meatus and split, one small part entering the tympanum and the rest probably burying itself in the facial bones. The hearing was totally destroyed. Notwithstanding another bullet which the patient had put into his neck at the same time, and which was removed from his shoulder, he had scarcely a symptom except a moderate suppuration of the tympanum. The external wound of the ear healed by first intention. The bullet track in the meatus healed, and when last seen he was in a fair way to make a complete recovery, except from the deafness.

No. 21. Caries of the whole mastoid, showing finely the demarcation between healthy and diseased bone in the antrum. When removed, the outer and inner tables were honeycombed but entire. They were so delicate that they were lost in maceration.

No. 22. Extreme osteo-sclerosis of the mastoid. The history is unknown.

No. 23. Caries of tympanic roof and posterior surface of petrous bone. Phlebitis of the lateral sinus; extensive sloughing of cerebrum and cerebellum. Death from meningitis. Mastoid diploëtic.

No. 24. Osteo-sclerosis of the mastoid.

No. 27. Osteoma of the mastoid removed by operation.

No. 28. Inflammation of the mastoid. Caries of the sigmoid groove. Very rare extension of the caries along the edge of the petrous bone. Two mastoid operations. Meningitis. Interesting, as showing how the usual mastoid operation may not reach the important focus of the suppuration, which was in this case in the extreme upper and posterior portion of the bone, more than an inch backwards from the osseous meatus.

No. 29. Cholesteatoma of the temporal bone.

No. 30. Carious ossicles removed by operation.

No. 31. Caries of the groove of the lateral sinus and superior petrosal sinus. Perforation therefrom to the outside, with a sub-periosteal abscess. Mastoid operation useless. Meningitis.

Here there was an immense sub-periosteal abscess. The minute external opening which communicated with the sulcus of the lateral sinus an inch and a half behind the meatus, was not discovered at the operation. Although the tympanum, which had been inflamed some weeks before, showed no signs of inflammation, I opened the mastoid, but found no pus. The case is interesting as showing how serious and fatal caries may remain after the inflammation of the tympanum and mastoid has completetely subsided.

No. 32. Caries of the malleus.

No. 33. Caries of the incus and malleus.

No. 34. Caries of the incus and malleus.

No. 35. Caries of the incus and malleus.

No. 36. Caries of the incus and malleus.

Of 26 hammers:

	Carious.	Normal.
Head,	19	7
Articulation,	12	14
Neck,	12	14
Short process,	9	17
Manubrium,	12	14

Normal throughout, 0.

Head most frequently affected.

Short process least frequently affected.

Of 19 anvils:

	Carious.	Normal.
Body,	19	0
Articulation,	7	12
Long process,	19	0
Short process,	12	7

Normal throughout, 0.
Body and long process most frequently affected.
Articulation least frequently affected.

26 hammers, each with five parts = 130

Normal,	66
Carious,	64

19 anvils, each with 4 parts = 76

Normal,	19
Carious,	57

Long process of anvil destroyed at its end, disarticulating the stapes in 17 cases.

Of 20 operations:

Anvil not found in 5.
Hammer found in 20.
Caries of both bones in all.

No. 37. Bony anchylosis of the incus and malleus with caries of the incus.

No. 38. Osteoma of the mastoid.

NOTE.—I regret extremely that it is impossible to comply with the very complimentary request of the Society and furnish illustrations of the specimens shown. They are of such a character that no method of illustration known to me could reproduce them in time for this publication. J. O. G.

DISCUSSION.

Dr. Knapp:—I should like to make some remarks on two of the specimens, No. 19 and No. 23. These seem to have particular value in regard to operations. No. 19 shows caries of the petrous bone, and along the roof of the tympanum. I have had to operate on several cases where the chisel went through the diseased bone inward and forward about two inches. I ask myself: Where did I go? This specimen shows it. All this space was filled with rotten tissue and pus, which I scooped out. You go above the ear sometimes two-thirds of an inch. These cases have marked cerebral symptoms, but they get well without opening the skull.

Specimen No. 23 is a similar one, which shows another practical point. The outer table of the mastoid is sclerosed; yet there has been a long process of suppuration and the same track is carious. If you open the mastoid you find the pus above the attachment of the auricle. When these sources of pus are removed the meningitis will get well.

Dr. Green said it was a matter difficult to demonstrate that acute or chronic meningitis had been recovered from. In the ear it is, but the eye may help us. There are a number of cases where there are symptoms of meningitis and distinct neuro-retinitis, acute cases and chronic cases. When I was a student, it was taught that meningitis never gets well, and that the cases that recover were instances of mistaken diagnosis. That is surely not true. There are cases exactly parallel to those that die, yet they recover. The double optic neuritis is just as pronounced, yet the patient gets well; the optic nerve atrophy, and occasionally strabismus, come afterward. Sometimes a child will have no other symptoms except a certain degree of fretfulness. When before operating you look into the

eye, you are surprised to find optic neuritis. We have sure proof that optic neuritis, strabismus, and with them meningitis, are not very rarely recovered from.

Dr. J. Orne Green:—I did not deny that recovery from meningitis could occur, and I brought this forward as an anatomical demonstration of recovery from meningitis which it is rare to be able to demonstrate in our pathological laboratory. I have no doubt from the clinical history that recovery occurred, and here we have the anatomical demonstration of it.

Dr. Gruening:—At a recent meeting of the "Berliner Medicinische Gesellschaft" (May 17, 1893), Hartmann showed several anatomical specimens of osseous growths of the external auditory canal and demonstrated that the tumors grew most frequently from the innermost parts of the canal, in the line of junction of the tympanic and squamous portions of the temporal bone. At the same meeting, Virchow presented a number of Peruvian skulls, containing large osteomata of the external auditory canal. In these skulls the growths had developed from the outer parts of the osseous canal, blocking the entrance, but leaving the canal free. In thirteen per cent. of the Peruvian skulls of the Berlin collection, Virchow found such osteomata. In our country Dr. Blake has observed similar conditions in the skulls of the aborigines. Perhaps Dr. Blake will be kind enough to say something on this subject.

Dr. Blake:—The bony growths that I have seen have grown from the antero-superior or postero-inferior walls of the osseous meatus. They were quite distinct from the growths which Dr. Green has mentioned, and I do not recall having seen any cases like those shown by Dr. Green.

Dr. J. Orne Green:—In these cases of osteoma there was no bone cut in their removal. The ear was turned

forward and the loose growth exposed, covered by soft tissues. It was not attached to the bone at all. The point that I want to make is that we have here a true osteoma, and, as I said in the paper, it seems to me that it is possibly the development of a fœtal remnant.

Dr. Randall:—There is a possibility that in these cases the osteomas rise by minute shanks which had spontaneously separated or were broken even by the probing. Each showed a point of probable attachment.

Dr. J. Orne Green:—I speak of that, but if that were the case, I fail to see how it would be covered throughout by a distinct cartilaginous coating.

STAPEDECTOMY AND OTHER MIDDLE EAR OPERATIONS.

By Clarence J. Blake, M. D., *Boston, Mass.*

In the investigations made since the last meeting of this Society, in accordance with previous plans, especial attention has been given to the question of the feasibility and advisibility of the extraction of the stapes in those cases of *chronic non-suppurative* disease of the middle ear in which the slow progress and final extreme degree of deafness lead the patient to seek almost any means of relief; previous experience, extending over several years, in cases of fixation of the stapes, as the result of *chronic suppurative* disease of the middle ear, having shown that synæchtomy, tenotomy of the stapedius, and circumcision of the stapes followed by auto-mobilization, gave promise of a practical improvement in hearing, equal, possibly, to any gain accruing from a removal of the stapes itself; and so effecting this gain moreover without subjecting the patient to the introduction of a labyrinthine factor of unknown quantity; these observations, taken as a whole, apparently justify the following conclusions:

1st. That in those cases of *non-suppurative* disease of the middle ear with a high degree of deafness, for which such relief as might be afforded by an operation of this kind is most desirable, the operation of stapedectomy is most likely to be futile because of a degree of fixation of the base of the stapes leading to fracture of the crura rather than the removal of the bone entire, if the effort at extraction is persisted in.

2d. That in the class of cases in which the operation of stapedectomy has apparently given the best results, namely, fixation of the stapes as a sequence of *chronic suppurative* disease, it is by no means certain that equally good results could not have been obtained by surgical mobilization and subsequent care.

3d. That while the removal of the stapes from its fenestral attachment is by no means so hazardous a procedure as it has heretofore appeared to be on theoretical grounds, it still opens up the possibility of interference to an unknown degree, with the most important part of the organ of hearing, and an almost equally important peripheral organ of equilibration.

Under these circumstances, it became necessary to provide, for the *non-suppurative* cases, some form of operation availing of the intelligent co-operation of the patient and permitting, in the progress of the operation, a series of hearing tests which should make it possible to determine the location in the sound-transmitting apparatus of the principal obstacle to sound transmission and the extent to which surgical interference was advisable. For this purpose, the plan of an "exploratory tympanotomy" was devised and has so far proved adequate.

By carrying the cut in the drumhead close to the periphery not only is a larger area of the tympanum exposed at a point where surgical access to it is most desirable, but an incision made in this way preserves intact that portion of the membrane reinforced by the dentritic fibrous tissue, thus affording a stiff flap, the cut edge of which may be brought in contact with the corresponding edge at the periphery and held in place by a paper dressing until the healing, which is usually complete in three days, has been effected; but it avoids the formation in the posterior superior segment of a cicatrix opposite the niche, which, on becoming subsequently stretched, is likely to

sink inward and interfere with the vibration of the fenestral membrane left by or formed subsequently to the extraction of the stapes.

Of the twenty-one cases of stapes operation in chronic *non-suppurative* disease of the middle ear, herewith reported, eighteen were operated upon in this manner and without general anæsthesia. Of the twenty-one cases but three, or less than fifteen per cent., have any appreciable improvement in hearing, and in but two of them was this gain sufficient to be of material advantage. In the first case, that of a young man thirty-six years of age, there had been gradual and progressive impairment of hearing of several years' duration. The hearing was especially affected during the persistence of head colds, in which condition, while the drumheads remained transparent, and without injection of the manubrial plexus, there was marked congestion of the tympanic mucous membrane. Shortly before operation upon the right ear, the membrana tympani, though transparent, did not show the descending process of the incus plainly, the Eustachian tube was free, the hearing for the Politzer acoumeter was two inches, for the tuning-fork aerially, $\frac{5}{65}$, and by bone conduction, through the mastoid, $\frac{30}{65}$. The hearing for the König's rods was 25,000, and the voice was heard and understood in a moderate tone at three feet distant. In this case the operation was done under ether, and the peripheral incision revealed extensive reduplications of mucous membrane much thickened, and so investing the ossicula as to render it necessary in order to get free access to the stapes to make an extended incision. Division of the tensor tympani tendon leaving the malleus still indrawn and fixed, this bone was removed by means of a snare, after the usual preliminary division of its attachments; the mucous folds about the incus and stapes were then divided by means of the paracentesis and angular knives, and by means of a hook passed

behind the incudo-stapedial articulation, the stapes was extracted from the niche but escaped from the hook and, together with the incus, was drawn upward and backward out of sight. There was pallor and slowing of the pulse with the extraction of the stapes, but outflow of fluid from the niche could not be determined definitely because of the serous oozing from the cut edges of the mucous reduplications; there were no untoward symptoms after the operation and the hearing slowly improved. Seven months later, the drumhead had been replaced by cicatrix. Five months after the operation, the hearing for the Politzer acoumeter was twelve inches, for the tuning-fork aerially, $\frac{20}{65}$, by bone conduction through the mastoid, $\frac{20}{65}$; for König's rods, 30,000; and for the voice in a moderate tone, between seven and eight feet. A marked symptom in this case was also an improvement in hearing to the extent of about ten per cent. of its previous value in the ear not operated upon, but which was also imperfect, the relief afforded to the right ear apparently leaving the sensorium more free to appreciate sound sensations generally. This case also served to illustrate the fact observed in other cases of stapes extraction, that while the hearing for the voice, as a whole, was at first materially improved, there was no corresponding gain in the differentiating power between consonant sounds, this faculty apparently becoming subsequently acquired as if the change in the condition of sound reception, the peripheral accommodating apparatus having been removed, required a process of mental compensation.

In the second successful case, there had also been a slowly progressive impairment of hearing, and the right drumhead was thickened and much retracted. The watch was heard at a distance of $\frac{8}{100}$, the voice at $\frac{1}{35}$, the tuning-fork aerially at $\frac{8}{35}$, by bone conduction, $\frac{17}{35}$. The operation in this case was done under cocaine, the

preliminary incision being that made in exploratory tympanotomy, the hearing for the tuning-fork immediately increasing by aerial and decreasing by bone conduction, on the opening of the tympanum. The stapedius tendon and the incudo-stapedial articulation were divided and the stapes, which was found to be tied down to the walls of the niche not only inferiorly but also laterally, was circumcised; on traction with a blunt hook, however, notwithstanding the sensation of slight suction resistance accompanying the traction, both crura broke and the head of the bone disappeared upward and backward. Coincidently with the traction upon the stapes there was vertigo, which increased and was accompanied by nausea and vomiting; these ceased, however, soon after the patient was put to bed. The hearing did not immediately improve, but twelve days after the operation was found to be, for the watch, $\frac{6}{100}$; for the voice, $\frac{21}{35}$; for the tuning-fork aerially, $\frac{23}{35}$, and by bone conduction, $\frac{30}{35}$.

In the third of the successful cases, there had been a chronic progressive disease of both middle ears for thirty years. The left drumhead was slightly opaque and indrawn. The hearing for the Politzer acoumeter was two inches; for the tuning-fork aerially, from $\frac{5}{65}$ to $\frac{10}{65}$, and the bone conduction could not be definitely determined on account of reference of the sensation to the opposite ear. The König's rods were not heard above 20,000 v. s. This operation was done under ether with the peripheral incision, division of the stapedius tendon and of the articulation, and traction upon the stapes with a blunt hook, resulting in a fracture of the anterior crus close to the footplate and of the posterior crus close to the head. The niche being plainly in view, circumcision and removal of the base plate was then attempted, the former by means of a small paracentesis knife, the latter by means of a short knife bent at an angle of forty-five degrees.

There was no slowing of the pulse until the attempt at extraction of the base plate was made, when it occurred coincidently with a slight oozing of watery fluid from the niche. There was no vertigo following the recovery from the ether, and two weeks after the operation the hearing in the left ear for the acoumeter was five inches, for the tuning-fork aerially, $\frac{15}{65}$, by bone conduction, $\frac{25}{65}$, and for the König's rods, 25,000 v. s. The patient especially noted an improvement in hearing for sharp sounds. In this case, also, there was a moderate improvement in hearing in the opposite ear and the expression, on the part of the patient, of a sense of relief in the head.

The remaining cases are briefly summarized as follows:

Number of cases of attempted removal of the stapes in chronic non-suppurative disease of the middle ear	21
The stapes removed entire in	9
Fracture of both arms in	10
Stapes immovable in	2
Change in the pulse incident to traction on the stapes in	12
Vertigo in	6
Vertigo persisting over one month in	3
Improvement in hearing in	3

A very marked difference in the condition of the stapedial articulation pertaining, on the one hand, in cases of long continued progressive *chronic non-suppurative* disease and, on the other, in cases of existing or past *suppurative* disease, will serve to account for the difference in the results of the operation of stapedectomy in these two distinct classes of cases. In the former, the tissue changes include not only an atrophy of the investing membranes but also of the bones themselves, and especially of such more delicate structures as those which must be made the subject of mechanical force in the operation of extraction of the stapes; these atrophic changes are also commonly accompanied by tissue infiltration and calcareous degeneration of that class of structures going

to make up the articulations and including, therefore, the relationship of the base plate of the stapes to its fenestral attachment. Further than this, the long and progressively increasing fixation of the sound-transmitting apparatus of the middle ear results in deeper-seated changes within the labyrinth, the extent of which we have no means of knowing, since all tests of hearing by bone conduction under these conditions must be made of record subject to the possible influence of the fixation of the sound-transmitting apparatus upon the functional activity of the labyrinth. So far as prognosis is concerned under these conditions, therefore, the result of an operation which shall eliminate the ossicular chain functionally by removing the stapes becomes entirely problematical, as indeed it must in all cases where such removal entails an indefinite degree of interference with a perceptive organ indefinitely altered from its normal condition.

In the cases of *suppurative* middle ear disease the changes are, except those of very long standing, virtually more superficial. The immobility of the stapes is the result of the thickening of the tissues, reduplication of the mucous membrane normally extending between its crura and the niche wall or of adhesions formed in the progress of an ulcerative process, rather than of changes about the base plate; conditions in which very material improvement in hearing may sometimes be obtained by division of the adhesions and by such subsequent provision for the mechanical movement,—auto-massage, as it were,—of the stapes, as shall insure its continued freedom of vibration. The following cases may be taken as illustrating this.

The first, a young man twenty-eight years of age, had *suppurative* otitis media as the result of scarlet fever in childhood; in the right ear there was destruction of the membrana tympani, slight muco-purulent discharge, firm adhesion of the malleus to the promontory and attach-

ments extending from the descending process of the incus, and from the stapes to the contiguous parts of the tympanic wall. The voice was heard only with difficulty in that ear, the tuning-fork aerially was not heard, and by bone conduction, $\frac{30}{65}$. The section of the malleus from the promontory, tenotomy of the tensor tympani, and mobilization of the malleus gave no improvement in the hearing. Division of the folds about the incus and tenotomy of the stapedius gave no improvement, and it was not until synæchtomy inferiorly to the stapes and circumcision of the crura had been effected that there was any improvement in hearing. Under these conditions, the voice was heard distinctly at a distance of three feet, and with the introduction of a cotton vaseline artificial drum it increased to fifteen feet, an improvement which has continued under the same conditions for over three years.

In a second case, that of a man fifty years of age, there had been the same history of a long continued *suppurative* process. The malleus was carious, consisting merely of a small nodule of bone, including a portion of the head and neck. The incus was wanting, the stapes was in position and intact. Dr. Loewenberg, in whose care the case had previously been, had removed large masses of epidermis from the upper portion of the tympanum and had advised some form of operation upon the carious bone later. After careful division of its attachments the malleus remnant was removed by means of the Politzer forceps and the granulations in its neighborhood curetted; the stapes was found to be firmly bound to the inferior niche wall and these adhesions were divided without improvement in hearing, and it was not until there had been both tenotomy of the stapedius and circumcision of the crura that any gain in hearing for the voice was noted. Previous to this last cutting the voice had been heard and understood in the right ear at a distance of two feet only.

After the last incision the hearing more than doubled, and with the introduction of a cotton vaseline drum it increased to twenty feet, and has so pertained during a period of two months.

Experiments in similar cases, made by obliging the patient from time to time to omit the use of the artificial drum, have shown a progressive improvement in hearing between the intervals of omission, the increase in excursion of the stapes incident to the greater volume of sound transmitted to it from the large surface presented by the artificial drum serving not only to prevent the reforming of adhesions but also to still further relax the attachments remaining. As an example of what may be effected by this form of auto-mobilization in cases where the fixation is one of the results of *chronic suppurative* disease of the middle ear and the persistence of the improvement, may be cited the case of a man forty-two years old who had, in consequence of a past *suppurative* disease of the middle ear, a large perforation in the posterior segment of the right membrana tympani with cicatrices extending inward about the oval window but leaving the head of the stapes free. The hearing in this ear was, for Politzer acoumeter, four inches, and for the voice, three feet. A piece of sized paper of the kind ordinarily used for paper dressings and about four millimeters in diameter was pasted upon the head of the stapes, one edge resting upon the upper rim of the perforation. With this paper in position, the hearing for the voice was doubled and the improvement continued so long as the paper remained in place. It was replaced at the end of the three weeks by a larger and longer piece supported as before but extending from five to six millimeters beyond the head of the stapes, thus affording a larger surface for the reception of the sound waves, and a larger leverage; the paper was subsequently renewed at intervals of three or four weeks, as

many times, and until the hearing was found to be, without the paper application, as good as it had been when the first piece of paper was applied. Under these conditions, its use was dispensed with, but the patient has, in the twelve years that have since elapsed, occasionally come to be provided again with this means of automobilization.

In conclusion, so far as the removal of the stapes is concerned, I may say, as the expression of a personal opinion, that, when possible, in cases of *non-suppurative* disease of the middle ear, it is advisable to begin with an exploratory tympanotomy, an operation without general anæsthesia, leaving it to be determined by the examination and tests made during the operation as to whether the stapes can or shall be removed or not, and that in the *suppurative* cases it is preferable first to try simple mobilization, then to do synæchtomy, tenotomy, and crural circumcision, with, if necessary, the additional application of an artificial drum, and to allow a proper time limit for the determination of the effectiveness of these procedures before submitting the patient to the final operation of stapedectomy.

FURTHER OBSERVATIONS ON REMOVAL OF THE STAPES.

By Frederick L. Jack, M. D., *Boston, Mass.*

Since bringing the subject of removal of the stapes for improvement of hearing to the consideration of the Society, last year, the operation has been tried in thirty-two additional cases. These, together with the original series of sixteen, make forty-eight cases in all for observation and study. The results have been carefully noted, and care taken to have the tests in hearing as accurate as possible.

In reviewing the cases, there is much to encourage the adoption of the procedure, but its clinical application will require modification. The new is always interesting, and the tendency is to urge one on, yet it has seemed best in so important a matter to advance slowly.

Of the original sixteen cases, three were in active process of suppuration at the time of the operation; nine were the effects of chronic purulent inflammation. These ears, with one exception, have remained healed. There were three otitis media insidiosa, and one of Ménière's disease.

In bringing the subject before you this year, it is hoped that a report of the present condition of the first series may prove interesting, and that brief histories of a few subsequent cases, illustrating further some of the conditions met with, and suggesting problems still awaiting solution, will be profitable.

Most of these cases have been seen once or twice during the year by members of the staff at the Infirmary, and

nearly all have been again tested within two or three weeks by Dr. Crockett or myself. It is about one year since they were operated upon—time enough to form some idea as to the permanency of the results in hearing, and to note anatomical changes, if any, in cases where the oval niche was visible.

In a case of chronic suppurative inflammation of both middle ears, in which the right stapes was removed a year ago, the oval niche one month afterwards was found granular, a condition probably due to the neglect of the patient to continue treatment. The ear healed in a short time after removing a portion of the growths with forceps and making application of a saturated solution of copper. On July 8th, 1893, examination of the right ear revealed a thin membrane over the oval niche. Ear perfectly dry. This condition was the same as when last seen some four months before. Hearing in the right better than in the left ear, which still continues to discharge. Before the operation the hearing was more acute in the left than right ear. Tests in hearing on July 8th, 1893, as follows:

$W = \text{R } \frac{3}{60}, \text{ L } \frac{2}{60}.$

$V = \text{R } \frac{8}{25}, \frac{20}{35}; \text{ L } \frac{1}{25}, \frac{2}{35}.$

$F\,C = \frac{\text{a. c.}}{\text{b. c.}}, \text{ R } \frac{10/35''}{20/35''}.$

Remarks.—Hearing was practically the same as when tested immediately after the operation a year ago. This seemed rather surprising, considering the subsequent inflammation in the oval window, with every condition favorable for the occlusion of the opening by adhesion.

The wound in the drum in most cases was found cicatrized. In a number of cases where the drum, previous to operating, was wanting, as in the case just spoken of, a thin cicatricial membrane over the oval window could be distinctly seen.

A matter of considerable interest is the effect of removal on the labyrinth. The patients were closely questioned for any symptoms of vertigo, but it was found in one case only, that of a woman forty-seven years of age. Dizziness was, however, an old complaint with her, and was very likely due to dyspepsia. She volunteered the information that the trouble was less frequent of late than for a short time after the operation. In a few cases vertigo which was complained of before the operation had entirely disappeared.

The influence of the operation upon subjective noises, judged by these cases, is uncertain. Many in whom tinnitus existed previous to the operation have been entirely free from this annoying symptom for a year. The reverse, though, is true in a few cases, a slight noise being noticed now at times.

The improvement noted in hearing the tuning-fork (Politzer), both by air and bone, was found essentially the same as when tested a year ago.

The test by König's rods showed in one case a slight gain of five thousand (5000) vibrations per second; in another the loss of the same; in one case the considerable gain of fifteen thousand (15,000) vibrations after the operation was still held.

The test for hearing the watch indicated in some cases a slight gain, in others a slight loss. In cases of slight loss for the watch and rods—this, of course, indicating a diminished perception for high tones—the hearing power for the voice was apparently increased. This peculiarity in the relation between hearing the voice and high tones is frequently found among deaf people.

We now come to the point of greatest importance, to the patient at least, namely, a report of the hearing power for the voice. In applying this test, the same words were used in all cases, for, as shown by Wolf, the pitch of the tones

of speech range from sixteen vibrations per second to four thousand thirty-two (4,032) vibrations, nearly eight octaves, and vowels are heard at a greater distance than consonants. The opposite ear was tightly plugged with cotton, and the finger of an assistant pressed firmly into the meatus. In those cases where the foot-plate remained there was practically no change from preceding tests. On the other hand, where the oval window had been completely cleared, the hearing was practically the same as found immediately after the operation.

In the only case at that time of removal from both ears, the hearing remained perfectly good for five months, and was then somewhat impaired after a severe head cold, which closed the Eustachian tubes and caused marked retraction of the drum-membrane in the neighborhood of the oval niche. The drum returned to its normal position after inflation of both middle ears through the catheter, and hearing was restored. This would seem to prove, as there was no stapes in either ear, that the obstruction to hearing was due to the drawing of the cicatricial membrane into the window. About four months ago, a triangular piece of membrane was removed under cocaine, from one side in the upper posterior quadrant, with the object of contracting the cicatricial drum. By this it was hoped to counteract the tendency of the membrane to sink into the opening. This was partially, but not wholly successful. This case was numbered XII. and briefly reported last year as one of progressive deafness from chronic non-suppurative inflammation (hypertrophic) of several years' duration. No history of otorrhœa, but a cicatrix was found over the head of the stapes on the left side. The hearing in the left ear before operation was as follows:

Whispered voice not heard; loud voice, four feet; watch, $\frac{2}{60}$; tuning-fork C, through the air, 15″, by bone conduction in the left ear; König's rods, 30,000. Operation under ether, June 26th, 1892. Stapes removed.

On July 8th, 1893, about one year after the operation, the hearing was better than immediately after. Whispered voice, three feet; loud voice, twenty-one feet; watch, $\frac{1}{100}$; tuning-fork A, 13″, by bone conduction in the right; König's rods, 35,000.

On September 27th, 1892, at the patient's request, the right ear was operated upon, although the hearing was fair. Whispered voice, six inches; moderate voice, ten feet; watch, c/60. Nine months afterwards (July 8th, 1893), whispered voice, ten feet; moderately loud, thirty-five feet; watch, $\frac{1}{100}$. More concisely given in table. July 8th, 1893:

$W = \mathrm{R}\ \frac{1}{100},\ \mathrm{L}\ \frac{1}{100}.$

$V = \mathrm{R}\ \frac{3}{25},\ \frac{21}{35};\ \mathrm{L}\ \frac{10}{25},\ \frac{35}{35}.$

$FA = \frac{\text{a. c.}}{\text{b. c.}},\ \mathrm{R}\ \frac{13''}{17''},\ \mathrm{L}\ \frac{15''}{15''}.$

Weber equal.

König's rods, 40,000, not heard.

These tests were made after the use of the catheter, and, for the reason already spoken of, show a little better results than before inflation. The ears have remained perfectly healed. No dizziness and less tinnitus than before. The special importance of this case lies in the fact that there is no stapes in either ear. The only plausible theory for the remarkable improvement is that there is unobstructed conduction of sound waves through the oval window, and that there they fall upon a healthy perceiving apparatus beyond.

In general, the operation described last year is employed (Transactions of the American Otological Society, 1893). There are a few additional details, however, worthy of brief notice. During the operation, the patient's head must be perfectly still. To ensure this, ether should be given. As suggested in the paper of last year, an

exploratory opening (partial myringectomy) may be advisable, to reveal the presence of adhesions, and to determine the mobility of the stapes. For this the use of a solution of cocaine is often sufficient. It is important to carry the posterior and upper cut as close to the auditory ring as possible, for in not a few cases the joint is on a line with this ring or is situated a little above it. The small flap in the drum may be put back in place, and is best kept in position by the paper dressing recommended by Dr. Blake. Removal of the bone is made difficult or impossible by firm anchylosis, usually of the foot-plate, or from high position of the oval window, or, what is practically the same thing, a prominent auditory ring. The crura are sometimes very delicate—perhaps atrophied by pressure—and easily break on manipulation.

If in disarticulating the incudo-stapedial joint the incus is considerably displaced, its removal is advisable, particularly if it interferes with a view of the head of the stapes. The long process of the incus, when in place, tends to prevent the subsequently healed membrane from sinking into the oval niche, a condition which in one case previously mentioned of double extraction of the stapes a year ago, is the only obstacle which prevents the patient from almost perfect hearing for the voice.

As regards the application of the operation to some of the different classes of ear disease. In cases of otitis media suppurativa, after the otorrhœa has ceased, the incudo-stapedial joint is often firmly fixed by bands of adhesion. Briefly described, this condition of the bone offers a mechanical hindrance to the transmission of sound waves to the vestibule. Relieving this obstruction by removal of the stirrup has increased the hearing power for the voice very materially.

Another set of cases is very similar pathologically, otitis catarrhalis adhæsiva. There is proliferation of the

tissues with anchylosis of the ossicular chain. Here again, good results by removal of the bone have been demonstrated.

There is a third class—otitis media insidiosa (sclerosis)—in which it is generally believed that the anchylosis is not fibrous but osseous (Tröltsch, Toynbee). This condition is usually characterized by a high degree of deafness and tinnitus. Appearances of the tympanum are either normal or nearly so.

Judging from a few experiences with this troublesome condition, the region of the foot-plate would appear to be the principal seat of the bony anchylosis. I can only say in evidence of this, that in most of these cases the foot-plate, in part or whole, remained behind after the removal of the head and crura. This accident is at present unavoidable and insurmountable. As might be expected, the improvement in hearing is not as great as in the other cases. Larger experience with this class of cases may however give better results.

The importance of a differential diagnosis before operating is of course great. To the tests already employed in diagnosis, the vibromata may form a useful addition in determining the existence or non-existence of fixation of the stapes. It seems hardly necessary to say that diseases of the internal ear are not affected.

The following cases recently operated on best illustrate several important points.

Case I.—Partial removal of the foot-plate with stapes hook. Rupture of the basal membrane, and outflow of the perilymph.

B. S., 48 years old. History of progressive deafness for fifteen years, the result of an insidious middle ear inflammation (otitis media insidiosa). The tuning-fork test revealed increased bone conduction on the left side.

Hearing for the voice less than one-half for usual tones. The left ear was operated upon February 27th, 1893. Dr. W. S. Bryant was present. The operation was performed in the usual way up to the point of extraction, when the crura broke close to their insertion to the base plate. At the point of fracture the bone was found unusually slender. The plate could now be clearly seen, and attempts to pick it out, both by Dr. Bryant and myself, were unsuccessful at first. The point selected was the posterior upper edge, where the thin plate, to a large extent, overlaps the margin of the oval niche. The point of the hook was carefully kept downwards, away from the facial nerve. So firmly fixed was the bone that the hook failed to engage, and it was only by fracturing the plate in the centre, where it seemed somewhat thin, that portions were removed. Immediately on breaking through there was an outflow of fluid from the labyrinth. A few small pieces of the foot-plate were removed and the fluid absorbed by cotton. Patient remained in bed five days, and was made very dizzy and nauseated on raising her head from the pillow. Hearing, a little better than before the operation. In two weeks patient returned home. Hearing good, a little dizzy on turning suddenly, no nausea. I have recently heard that the vertigo disappeared shortly after her return home, that the hearing was as good as before the operation, and the ear had given no trouble. The oval window in this case was unusually large and shallow, and the foot-plate could be easily seen. The region of the Fallopian canal was carefully avoided.

The escape of perilymph, then, does not necessarily destroy the hearing. This point had been demonstrated on pigeons by Kessel. It was possible to demonstrate the presence of labyrinth fluid in but a very few cases. The slight evidence gained from these cases seems to show that the hearing was much better where the

basal membrane was not ruptured by the operation. The margins of the fenestra ovalis and articulating surface of the foot-plate are encircled by a hyaline cartilage, as shown by the investigations of Toynbee, Tröltsch, Rüdinger, and others. These conditions, when not too far destroyed by pathological changes, would admit of removal of the foot-plate without rupture of the membrane beneath.

Besides firm fixation of the foot-plate, we have anchylosis of the crura of the stapes with the niche of the fenestra ovalis described by Politzer. In this class of cases, the operation has met with the best results. Mobilization of the stapes has probably also met with its best results here. This proliferation of tissue is naturally more abundant in ears having passed through a suppurative process, although in the non-suppurative cases the stapes is often found firmly fixed.

Case II.—Fixation of the stapes result of chronic suppurative inflammation. Removal of the bone followed by marked improvement in hearing.

B. D., 52 years old. Hearing nearly destroyed, the result of long continued suppurative otitis media. Examination on April 3d, 1893, revealed extensive destruction in the right membrana tympani. The left membrane had been entirely destroyed, with the exception of a very narrow edge at the insertion in the annulus tympanicus. The only ossicle that could be made out was the stapes, the head of which was firmly bound by adhesions. There was a slight muco-purulent discharge from the ear.

There was no hearing in the right ear, it being totally deaf for all sounds through the air. The tuning-fork C was not heard at all by bone conduction.

Upon the left side a loud voice could be heard through a conversation tube. Bone conduction good.

Considering the fact that the stapes was firmly anchylosed, and that bone conduction was normal, the conditions seemed favorable for operative interference. The adhesions around the head were divided and the knife carried a little way into the niche before the bone was sufficiently movable to attempt its extraction. Traction on the bone produced some dizziness, which was quite marked on its removal. Immediately after the operation, the ordinary voice could be distinguished at four feet. This marked improvement continued for two days to the patient's delight, when inflammatory reaction set in, and the hearing steadily decreased. While this lasted the hearing was very bad. The ear is now healed and the hearing is improving. At present it is: — watch, not heard on contact.

$$V = \tfrac{1}{55};\ T\,F\,C\ \frac{\text{a. c.}}{\text{b. c.}},\ \frac{\text{o.}}{14''}.$$

Weber, not heard.

The results in this case were excellent up to the time of reaction, which entirely closed the oval niche with swollen mucous membrane. Reaction has been the exception, and was in this case very likely due to the presence of a purulent discharge in the ear.

The next case, one of those forlorn hopes for which as little might be expected from removal of the stapes as by any other known means of treatment, is briefly reported.

Case III.—Deaf mute. Double extraction of the stapes.

Miss G., of Pittsburg, 19 years old, recently a scholar at Clarke Institution for Deaf Mutes. Hearing began rapidly to fail about ten years ago. Family history good and has always enjoyed good health. In December, 1892, when I saw the patient, both drum-

membranes were nearly normal in color and position. The long process of the incus was visible in both ears. No hearing for any sounds by air or by means of the conversation tube. Tuning-fork said to have been heard through the cranial bones. On December 29th, the operation was performed on the right ear in the usual way under ether. Little resistance was encountered in the removal. There was no dizziness, and the patient was up and about on the next morning. No reaction. The hearing was improved; isolated words and the tuning-fork heard through the conversation tube. Encouraged by this slight gain, and at the patient's request, the left ear was operated upon two weeks later. Some difficulty was met with in dividing the incudo-stapedial joint, caused by a rather long bony projection on the tip of the long process of the incus. As before, there was no reaction or discomfort other than usually attends the administration of ether. The hearing was not improved. A loud noise through the otophone caused a slight pain for a day or two. A lesion of the auditory nerve or sound-perceiving apparatus was strongly suggested by the tests made before the operation, and it was confirmed afterwards by the results.

In reviewing the year's work, the following conclusions are drawn:

1. The operation is followed by the best results in the class of cases where, from the increase of tissue, the effects of suppuration or hypertrophic inflammation, the stapes offers an obstruction to sound waves: by its removal the hearing is improved. The results in cases of otitis media chronica insidiosa, on account of failure to extract the foot-plate, are not encouraging.

2. Inflammatory reaction is unusual and followed by no bad results.

3. The hearing is not necessarily impaired by the subsequent growth of a thin cicatricial membrane over the fenestral niche.

4. Some cases of tinnitus and aural vertigo are relieved, and there is little chance of causing permanent vertigo in cases where it had not previously existed.

5. It rarely happens that a patient improves for all tones. Improvement in hearing the human voice is out of proportion to the improvement for other sounds, and the reverse sometimes occurs.

6. Failure of success in some cases may be due to hemorrhage into the labyrinth at the time of the operation. It is believed to be a rare complication, but was thought to have occurred in one or two cases.

7. In removing carious ossicles, the stapes, if found diseased, should also be removed.

DISCUSSION.

Dr. Blake:—I have listened to Dr. Jack's paper with much interest. When the question of these investigations first came up I proposed to Dr. Jack that we work together or independently, and we decided on the latter course. The result is very gratifying. We have here two series of entirely independent investigations.

In regard to the question of vertigo, in one case on which I operated five months ago, the vertigo still persists. In another case of chronic middle ear disease operated on two months ago the vertigo persists, although greatly diminished. In this particular case, when the tympanic cavity was first opened the hearing distance and duration doubled. I then proceeded to do stapedectomy, and with the extraction of the stapes the hearing at once fell to zero and dizziness supervened. In another case, that of a young man who had destruc-

tion of the membrana tympani, the stapes was entirely free from attachments, and all that had to be done was to withdraw it with the blunt hook; the cartilaginous base plate was left in the ring and the membrane was ruptured. This was followed by a slight reddening of the mucous membrane, which increased and there was outflow of serous fluid. With the extraction of the stapes, the hearing improved, and the patient could hear the voice at twenty feet. Previously, he had heard the voice only at two feet. Within fifteen minutes he began to be dizzy, and this so far increased that he had to be put to bed for two days. The hearing varied very much during the continuance of the outflow of fluid, a period of ten days. Gradually this outflow ceased, and the dizziness disappeared. With the cessation of the dizziness and the outflow of fluid, the hearing decreased to what it was before the operation.

Dr. Howe:—I have been much interested in this subject, for we all know how we grasp at any straws which give any hope. After hearing the paper which Dr. Jack presented last year, I took occasion to go to the Charles Street Institution, and Dr. Jack showed me some of the patients, and the results were very satisfactory to me.

It strikes me that there are two questions that must be taken into consideration. One of these is the personal factor on the part of the patient, for we know how great an effect expectancy on the part of the patient will have. In one of the cases, that factor seemed to be eliminated as much as could be expected.

We must also take into account in these observations the imperfections of our tests and the imperfections of our methods for ascertaining what the hearing is before and after operation. Small differences are next to worthless, for we know how difficult it is to thoroughly close the ear. Even if you close both ears while I am speaking, you will

be able to follow me almost as well as you do now. The difficulty in eliminating this source of error, when there is any appreciable degree of hearing, is very great.

Dr. Jack:—At the last meeting, it was questioned whether, during the test, the patient might not be hearing with the ear not operated on. I was very glad, therefore, to have the opportunity of operating on the second ear in one of the cases. The first operation was done a year ago last June and the second last September. In one ear, after inflation the hearing is perfectly normal, and in the other, nearly so. I do not think that the results of the operation in sclerosis are at all encouraging, but I am not willing to give it up even where the stapes is firmly fixed. I would try other things first, but as far as my reading and experience go, mobilization of the stapes gives results for a few weeks and then the adhesions reform and the trouble returns.

Dr. Randall:—I was pleased with the report of this matter last year, and thought it agreed distinctly with my own impression as to the pathology of these cases, worked out from the results of excision of the other ossicles in sclerotic cases; for the obstacle to hearing seemed to lie external to the nerve and internal to the incus, since removal of the incus gave no effect. It therefore seemed rational to suppose that the stapes was the seat of the trouble. The cases reported showed that the stapes could be safely removed. I looked forward to brilliant results in this direction and began a series of experiments to determine the proper method of executing the operation; but I met with so much difficulty in the matter and found so many cases of high position of the oval window, that I have been deterred from attempting the operation. I hope to present, at a subsequent meeting, some studies that I am making in anatomy in this direction.

THE SURGICAL TREATMENT OF CHRONIC TYMPANIC VERTIGO, OFTEN MISCALLED MÉNIÈRE'S DISEASE.[1]

By Charles H. Burnett, M. D., *Philadelphia, Pa.*

Chronic tympanic vertigo, the most frequent form of aural vertigo, is one of the results of chronic catarrhal otitis media. When it occurs it is found in connection with tinnitus aurium and deafness, still commoner results of chronic aural catarrh. Unfortunately, chronic tympanic vertigo usually receives the very unjust and inaccurate designation of Ménière's disease.

The latter term, if it means anything,—and it has but a very slender title to the wide acceptance it has met with in medical nomenclature,—means a form of aural vertigo due to disease of the semi-circular canals. Disease of these canals, however, is very rare, and difficult to diagnosticate.

The name "Ménière's disease" is *inaccurate*, because it is indiscriminately applied to all forms of aural vertigo, regardless of the seat of the otic lesion, whereas Ménière attempted to prove the existence of a disease of the semi-circular canals as the only cause of aural vertigo, — an entirely untenable hypothesis. The name is *unjust*, because Flourens in 1822, and Deleau in 1836, described aural vertigo more accurately than Ménière in 1861,[2] and Deleau came much nearer than any previous

[1] Read by title.

[2] Gazette Médicale de Paris, Sept. 21, 1861.

observer to the solution of the cause of most cases of aural vertigo in placing the origin *in lesions of the middle ear*.

Tympanic vertigo due to lesions in the middle ear is of frequent occurrence. It is often not recognized, especially by the general practitioner, as aural vertigo. It is not unusual for tympanic vertigo to be attributed to intestinal disturbance, or to "neurasthenia," instead of to an aural lesion. Hence, the diagnosis being erroneous at the outset, the treatment is wrong, and the patients do not recover.

True tympanic vertigo, due to a lesion in the middle ear, chiefly from chronic catarrh of the tympanic cavity, is paroxysmal in character, and attended with tinnitus and deafness in the affected ear. It is caused by the inward pressure exerted upon the labyrinthine fluid by the retracted and ankylosed ossicles. The foot-plate of the stapes is thus unduly pressed into the oval window, and there held by the force named, paroxysmally and for longer or shorter periods.

I have long maintained the tympanic or mechanical origin of most cases of aural vertigo, in opposition to the asserted neuropathic or labyrinthine cause.[1]

In chronic catarrh of the middle ear there must always be, sooner or later, a disturbed tension in the conductors of sound, whereby at times the membrana tympani and the three auditory bonelets are carried unduly inward, and exert a morbid pressure by means of the impacted stapes upon the fluid in the labyrinth. This irritation in the labyrinth being communicated to the motor filaments of the auditory nerve is reflected by them to the cerebellum, and disturbed equilibration is the result.

This morbid retraction of the auditory chain, and

[1] "Aural vertigo." Philadelphia Medical Times, June 3, 1882.

resultant cerebellar irritation, are not constant, but vary with the state of the general health and the condition of the catarrhal middle ear. Hence all true aural vertigo of tympano-mechanical origin is paroxysmal in form.

If the theory is correct that the vertigo in chronic catarrh of the middle ear is due to the retraction of the conductors of sound and mechanical pressure upon the labyrinth fluid, then the surgical removal of such retraction and pressure ought to relieve tympanic vertigo.

No opportunity to test the truth of this theory offered itself to me until May, 1888. Then, being consulted by a former patient with chronic catarrh of the middle ear, for the relief of constant tinnitus, and oft-recurring attacks of *severe tympanic vertigo*, which had been superadded to her deafness in the left ear within the last two years, and finding that the malleus had become adherent to the promontory, I resolved to do what, so far as I know, had never been done for the relief of aural vertigo of a mechanical or tympanic origin, viz.: to cut out the membrana tympani and the malleus, in order to liberate the impacted stapes.

This case and the entire success attending the operation has been fully detailed in other places.[1] I would like to state here that the entire relief from tinnitus and vertigo, which followed immediately upon the operation five years ago, has continued to the present time. All the operations referred to in this paper were performed upon the etherized patient, the ear being illuminated by a six-volt electric lamp, held on the operator's forehead.

The operation of excision of the membrana tympani with the malleus was applied in four succeeding cases of

[1] The Polyclinic, August, 1888; The American Journal of the Medical Sciences, February, 1889; and the Transactions of the American Otological Society, 1890.

chronic tympanic vertigo with entire relief in all of them.[1] However, as more or less inflammatory reaction followed this operation in all of them, I concluded that removal of the incus alone, or of the incus and stapes, the membrana tympani and the malleus being permitted to remain in position, would liberate the stapes and the compressed labyrinth fluid, as well as, or perhaps better than, total excision of the membrana and malleus, and probably would not be followed by inflammatory reaction. The notes of the following cases will show that I was correct in my assumption.

The first case which I shall describe in detail in this article, was not one in which tympanic vertigo was at all prominent, or one in which the operation was performed chiefly for relief of that symptom. The prominent symptoms were dullness of hearing and annoying tinnitus, and to relieve these the operation of removal of the incus and stapes was undertaken. But as there had been some slight vertiginous attacks, and as the operation was successful in relieving the deafness and tinnitus, and preventing the recurrence of further attacks of even slight tympanic vertigo, it may be regarded in this instance as at least a prophylactic of pronounced tympanic vertigo.

With the five cases already referred to, this case becomes in this series—

Case VI.—Removal of the incus and parts of the stapes.—Mr. J. H. P., 23 years old, has had chronic hypertrophic aural catarrh — ambilateral — for several years. The left ear was formerly better than the right ear. The latter improved under treatment of the nasopharynx, but the left ear did not improve. The hearing-distance in the left ear for the voice was one foot, and there was annoying tinnitus. There had been some slight

[1] International Clinics, January, 1892.

vertiginous attacks ascribed to causes other than aural, but upon close examination they were found to have been otic in origin. The membrana tympani was opaque. The incus-stapes articulation was not visible through the membrana. On December 15th, the patient was etherized and the posterior superior quadrant of the membrana was excised. The incus, stapes, stapedius pyramid, and the tendon inserted into the stapes were plainly visible. The tendon of the stapedius was first severed; then the incus was separated from the stapes and removed from the tympanic cavity. A blunt stapes-hook was passed beneath the head of the stapes and traction was made. The bonelet was found to be most firmly imbedded in the oval window. Traction upon the bonelet by the stapes-hook brought away the head and crura. The operation was bloodless.

On December 16th no reaction had taken place and there was much less tinnitus. The hearing distance was not noted, as I failed to see the patient. On December 17th no reaction had occurred and there was marked diminution of the tinnitus; the hearing distance for words in low tones was from four to six feet. On March 28th, 1893, the perforation in the membrana had been maintained. A little tinnitus is perceived in this ear, if the patient takes cold in his head; otherwise he does not observe it. He volunteered the statement that *the operation was worth the relief from the tinnitus, regardless of the improved hearing.* The hearing distance at the present time is from eight to ten feet for isolated words.

Case VII.—Removal of the incus and stapes.—Beatrice B., 12 years old, had been known to have dullness of hearing in the left ear for two years. The right ear was entirely normal. Hearing in the left ear, 0; tinnitus, and vertigo at times, are annoying; the

tuning-fork is heard *per ossa*. On December 16th, 1892, the patient was etherized and excision of the upper posterior quadrant of the left membrana was performed; no bleeding followed. The incus, stapes, and stapedius pyramid, with tendon, were distinctly seen. The stapedius-tendon was severed first; then the incus was detached from the stapes; the stapes was then removed entire, with the greatest ease, from the oval window. There was no escape of labyrinth fluid. Finally, the incus, which seemed unusually adherent in the attic, was removed.

The operation was bloodless. On the next day there was no reaction, no vertigo, and the patient felt well and lively; she heard isolated words in the left ear at a distance of from eight to ten inches; there was no tinnitus. On December 22d there was no reaction and no regeneration of the membrana; it was found that the voice was heard in whisper at a distance of from six to eight inches; louder tones from two to three feet. There was no regeneration a month later. On April 1st, 1893, regeneration of the membrana had taken place. The hearing was not improved, but there had been *entire relief from tinnitus and vertigo*, which symptoms had been ascribed to other causes before the ear was examined by me and finally operated upon.

This is the only case in the series in which the stapes was removed entire. The result was so good—in fact, so much better than in some cases in which the stapes was only liberated or only its crura were removed—that I am inclined to think that in any case of tympanic vertigo in which liberation or partial removal of the stapes does not give as much relief as is desired, *puncture of the foot-plate* of the stapes, in order to relieve the labyrinth tension, would be justifiable.

Case VIII.—Removal of the left incus for aggravated chronic tympanic vertigo.

Mrs. Dr. R. G., aged 55, the wife of a physician, has had chronic catarrhal otitis media in left ear since childhood. The tinnitus has increased of late years, and she has been treated for years by a prominent physician, for neurasthenia. Within a year or two attacks of marked tympanic vertigo have occurred, and increased to *weekly* spells, quite laying her up in bed when the paroxysms take place. These attacks usually have come on in the house, sometimes in bed, but once lately the patient was attacked while out driving. The attacks of vertigo were attended with increased tinnitus, nausea, and vomiting, without loss of consciousness, the face and forehead being bathed in cold sweat. There has never been any rational aural treatment in this case. The patient has been treated with purgatives and alteratives for "neurasthenia," and has grown steadily worse.

Examination of the left ear revealed a retracted membrana tympani, with signs of sclerosis of the drum cavity. The incus and stapes were visible through the membrana. No catarrh of the nares or naso-pharynx. Tuning-fork heard *per ossa* in the affected ear. Loud words could be heard near the ear. The right ear is good, but said to be failing lately.

As the attacks of tympanic vertigo had now become so well marked, and so distressing, her husband had determined to seek relief for her by means of the removal of the force impacting the stapes in the oval window. Therefore, on June 7th, 1893, the patient was etherized, and after excision of the posterior-superior quadrant of the membrana, the incus, though held tightly in place by synechiæ, was quickly removed. The stapes was found firmly and immovably fixed in the oval window, and could not be extracted, its head being broken off in the endeavor.

There was no reaction in this case, and the patient went home, a hundred and fifty miles away, on the third day.

On June 25th, three weeks after the operation, her husband wrote that "she has been getting on so well that we have somehow failed to report to you of her general improvement. The first week after the operation she had several very *slight attacks* of vertigo, but they passed off very soon, and of late she has had no trouble whatever." She has been able to go about her house attending to her duties, without the fear even of the hindrance previously experienced from the attacks of tympanic vertigo. The tinnitus became much less, and the hearing improved a little. But the great end had been attained, viz.: *the relief from the sickening and incapacitating tympanic vertigo.*

On August 8th, 1893, her husband wrote that there had been some attacks of slight vertigo since his last letter, but nothing severe. Before the operation the patient had been bed-ridden by the severity and duration of the vertigo.

September 10. The patient remains free from vertigo.

Case IX.—Removal of the incus only.—Sister ——, a nun, 25 years old, has suffered for some years from tinnitus, deafness, and tympanic vertigo, due to sclerotic otitis media of the right ear, following a chronic purulent otitis media, which latter ceased years ago. There was a perforation of the posterior-inferior quadrant, with calcareous patches in the upper posterior and upper anterior quadrants of the membrana. The tuning-fork was heard well *per ossa* in the right ear, and isolated words could be heard *close* to the ear.

June 28th, 1893, the patient was etherized, and the perforation enlarged and extended into the upper posterior quadrant, exposing the incus lying high up in the attic. The incus was then removed.

The next day the hearing for isolated words in an ordinary tone was two feet, and for whispered words, from eight to ten inches, in the right ear. The patient was not seen again until July 20th, 1893, when she reported that there was no more tinnitus or "swimming in the head." There had been no return of these symptoms by September 1st, 1893. The result in this ear has been so good that a similar operation is contemplated for relief of dullness of hearing and tinnitus in the other, the better ear.

Case X.—Resection of the long process of both incudes for the relief of deafness, tinnitus, and severe chronic tympanic vertigo.

Mr. Charles C. T., aged 31, of Baltimore, Md., has been affected with chronic catarrhal otitis media in the right ear for eight years, and in the left ear for four years. Within a year the tinnitus has become severe in both ears, and the hearing has failed in both, the left ear being a little better for hearing, however, than the right ear. In addition to these symptoms there had been superadded the tendency to attacks of tympanic vertigo, with temporary increase of tinnitus aurium in both ears at the time of the vertiginous paroxysms. So severe have the latter been as to require the patient to hold on to the nearest objects in the street to prevent him from falling. He has never vomited, however, in any of these attacks, but their severity and frequency have dispirited him, and prevented him from attending to his duties. For many months past the patient has been treated for an *asserted* catarrh of the nares, naso-pharynx, and throat, but the deafness, tinnitus, and vertigo have grown worse rather than better. Examination, June 18th, 1893, revealed membranæ tympanorum slightly retracted, and that the incudes and stapes were visible through the membranes. The nares, naso-pharynx, and fauces were not affected.

July 21st, 1893, the patient was etherized, and I endeavored to remove first the right and then the left incus, after their exposure by exsection of the posterior-superior quadrants of the membranæ.

The right incus seemed firmly held in the attic, and when traction was made on the long process it quickly broke off. No further attempt to remove the body of the incus was made, as the object sought, viz.: severance of the retractive power of the incus from the stapes, had been attained. I met with the same experience on the left side.

The next day there was a slight reaction in both ears. The tinnitus was no better, and the hearing was perhaps a little duller in the *left*, the better ear. There was no vertigo.

The patient returned to his home now, and reported to me in the course of four days that he had had no vertigo, but that he felt worse in the ears, and that he had had some fugitive pains in his ears, with a little bleeding from one of them.

August 11. The patient reported "a slight improvement in hearing in the left ear, but none in the right. The tinnitus still continued, but there had been "an entire absence of vertigo." The left ear had pained him "quite a good deal, and felt uncomfortable for the past day or two."

August 13. The patient's sister, a physician, reported to me that there had been an "evident improvement in his hearing in the last ten days." Also a great improvement in his spirits.

September 3, 1893. The patient wrote that "the hearing in my left ear is much improved. I can hear conversation in ordinary tones about four feet, and if loud about ten feet. If the windows are open I can hear calls on the street. There is scarcely any roaring in the left ear, but

in the right (the deafer ear), though diminished, there is quite a good deal. The hearing in the right ear seems to be about the same as before the operation." There has been no return of the attacks of tympanic vertigo. The perforations in the membranæ tympanorum persist.

It is noteworthy that in this case relief followed the severance of the retractive force by resection of only the long processes of the incudes. Also, that most improvement in hearing and relief from the annoying tinnitus ensued in the *better* ear. This is due to the fact that greater mobility of the stapes had persisted in this ear than in the worse ear, and hence liberation of the freer stapes and the passive motion exercised upon it by sound-waves, have greatly improved the function of hearing in this ear. The result in this respect should encourage the surgeon to operate on both ears, or upon the better rather than upon the worse ear alone, where both are so profoundly affected as in this case. Most important is it to observe the *progressive improvement*, in this case as in some of the others. This must be due to the passive motion exerted upon the ankylosed stapes by sound-waves, which fall upon it more freely than before the operation.

From all the ten cases we may conclude:

1. That the removal of the retractive force of the sound-conductors upon the stapes is the efficient means of relieving the tinnitus, deafness, and vertigo, due to the lesions of chronic catarrh of the middle ear.

2. That the removal of the retractive force upon the stapes can be accomplished efficiently and simply by removal of the incus alone, and even by resection of its long process.

3. That the improvement in these cases is due to the liberation of the stapes from the retractive power of the tensor tympani muscle, and the consequent unimpeded action of the stapedius muscle, which, relieved of the

antagonism of the tensor tympani, tends all the more to draw the stapes from the oval window, thus aiding in the isolation and improved mobility of the bonelet, as well as in removing its undue pressure inward upon the labyrinth-water.

4. It would seem wiser, therefore, in most cases of chronic catarrhal deafness, tinnitus, and vertigo, not to sever the stapedius tendon and remove the stapes, but to be content with removal of the incus only.

5. The progressive improvement in hearing noted in many instances, especially in Case X., must be due to the passive motion exerted upon the ankylosed stapes by sound-waves, which are enabled to reach this bonelet more freely after the removal of the incus.

ON THE DIFFICULTY OF OPERATION IN THE DEPTH OF THE EAR CANAL; WITH DESCRIPTION AND DRAWING OF NEW INSTRUMENTS FOR SURMOUNTING IT.[1]

By Robert Barclay, A. M., M. D., *St. Louis.*

A wider application of surgical procedure in the depth of the ear canal has recently been discovered to us through the genius of some of the members of this Society. After extended original research, these indefatigable investigators have crowned their work by formulating its indications and elaborating its technique.

To add to the beauty and the usefulness of the work, nought remains for us but the humble task of "removing the basting-threads" — of analyzing and surmounting as far as possible the difficulty attending the performance of these delicate and complex surgical procedures deep within the ear.

Experience teaches that this difficulty is, in large part, due to the peculiar conformation of our existent instruments, — our specula, and shafts of blades; and from this fact an attempt has been made to devise new ones so proportioned as to combine the desirable features of those already in use, without their respective defects and faults.

What are these defects and faults in our instruments to which mainly the difficulty may be ascribed? What is the configuration of the instruments that exclude these?

First, as regards the ordinary aural specula: It may be objected that they are too long; some of them too narrow at the inner extremity, thus preventing a maximum of

[1] Read by title.

vision and of illumination; do not allow approximation of the operating hand to neck or jaw sufficiently near to secure a satisfactory finger-rest or hand-rest; necessitate long operative shafts on instruments; abbreviate the field of lateral and of circular movement of instruments; and cannot with facility be immovably and satisfactorily held in place by an assistant.

In obviation of these, an operating speculum has been devised by the writer, a description and drawing of which he begs to quote from the catalogue of the A. S. Aloe Company, St. Louis, who constructed it for him:

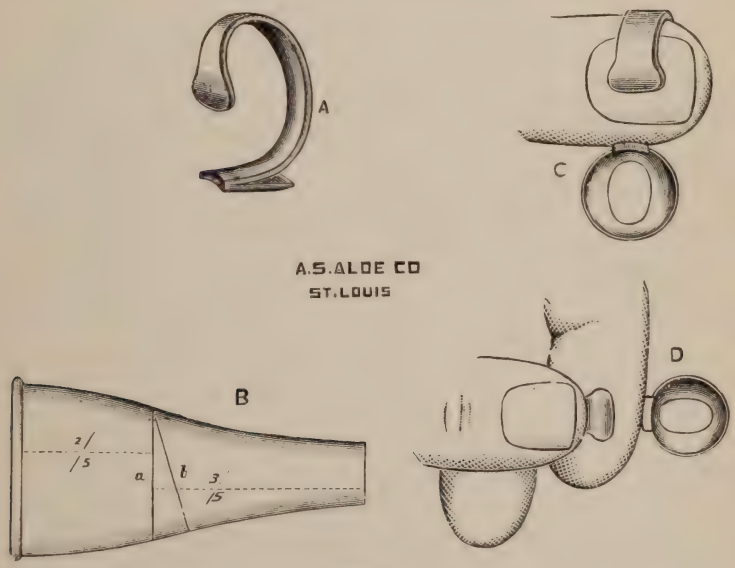

5238.

"By dispensing with that portion of an aural speculum that projects beyond the intertragal notch of the ear, this instrument allows the operating hand a rest for steadiness, and a maximum of shortening and of movement of instruments in operation within the ear. It consists of two

parts, — a tube and a handle. The tube resembles the inner portion of an ordinary aural speculum divided obliquely at two-fifths its distance from the outer rim (see Fig. 5238 B) and fits the slot of the handle, its longer or shorter side being below as required to bring its rim flush with that of the intertragal notch. For general use, tubes of different sizes are required, and, for rare cases, one cut transversely (see Fig. 5238 B).

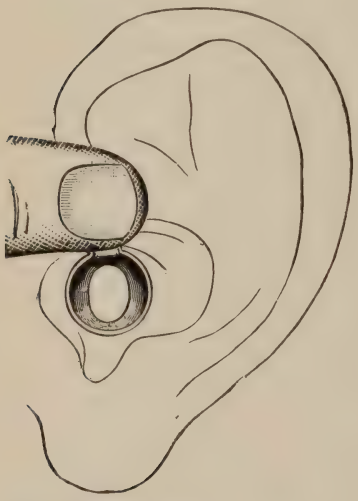

5237,
Showing Application.

5237.

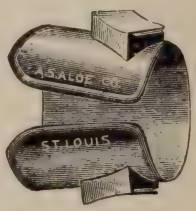

5239.

"The handle is made of one of three patterns: Like a spoon-handle, fixed to the tube, dipper-shaped (5237);* like an imperfect ring (5238 A); or like a split tailors-thimble (5239). When the patient is erect it is retained by a thumb (see Fig. 5238 C); when supine, by a finger (see Fig. 5238 D), to either of which it can readily be adjusted, the rest of the hand being free to steady the

*See Medical News, Philadelphia, April 22, 1893.

patient's head, or to hold cotton, instruments, etc. In order that it may be used by either hand, or upon either side the ear, the thimble-speculum has two slots for the tube. Whenever it is desirable to have both hands entirely free for other service, the speculum may be held in place by an assistant."

The footnote of this quotation refers to a report of cases of closure of the ear by growth of bone, successfully operated upon, two of them through the dipper-shaped speculum (Fig. 5237). In one of these two, an artificial auditory canal was bored through a complete bony septum five-eighths of an inch thick.

The ring-speculum (Fig. 5238) has been used in operating—successfully, and without injury to the drumhead—upon a case of aural exostosis (history as yet unpublished), briefly described thus: The tumor, growing from the upper two-thirds of the bony meatus, and almost occluding the canal of the ear, was three-quarters of an inch from the rim of the intertragal notch, one-eighth inch from the anterior-inferior quadrant of the drumhead, and measured, in the axis of the canal, one-half inch in thickness.

Inasmuch as the operations performed upon these cases were uncommonly delicate, dangerous, and difficult, they have been mentioned here to attest the practical utility and usefulness of this operating speculum with which they were performed.

As regards the shafts of blades: Aural surgical instruments already in use, whatever their operative extremity, have a shaft-and-handle after one of three dissimilar patterns; and are either straight or angular,—the latter either once bent (as at an angle of 110°), or twice bent (with the extremities parallel). Of these three existent patterns, certain features may be recognized as rendering deep aural operation difficult.

The straight shaft, typical instrument as such and cleverly manipulated by a very few, is, notwithstanding its advantages, objectionable from the fact that the thumb and fingers which must support it, inevitably obstruct, to a considerable degree, illumination and vision of the operative field deep within the ear.

The shaft, once bent (as at an angle of 110°), fails, in that it is inconvenient of manipulation; with it a hand-rest is difficult and awkward; antero-posterior displacement of the axis of the handle produces pricking or jabbing with the operative extremity; change of direction of the edge of the operative extremity is to be effected only by displacement, many times greater, of the axis of the handle; rotation of the operative extremity without displacement is to be effected only by swinging the handle transversely to its long axis, pivoting upon its extremity attached to the operating shaft, the axis of the latter shaft, remaining unmoved: which is practically impossible; it operates perfectly in one plane only, — that passing through the axis of the shaft and the handle; there is loss of power through increase of distance between the handle and the operative extremity; and, consequent on these, loss of assistance by *tactus eruditus*.

And the shaft twice bent, with parallel extremities, although allowing somewhat more control of the operative extremity than does the foregoing shaft, is, notwithstanding, equally objectionable, in that there can be no rotation of the operative extremity without displacement; no curved incisions made, other than very limited in curvature, and perfect control of the operative extremity is practically impossible.

A new and, it is believed, a superior pattern of shaft-and-handle for our instruments has been designed, which, with the kind assistance of the A. S. Aloe Company, St.

Louis, has been approximately perfected and placed upon the market.. Its description was first published in the Archives of Otology, New York, 1893, Vol. XXI., No. 2, pp. 179-180, as follows:

" * * * The instrument described below * * * affords a maximum of vision, of illumination, of mechanical effectiveness, of manipulative convenience and manual control, of economy of expense and space, and of adaptability to surgical instruments for narrow cavities.

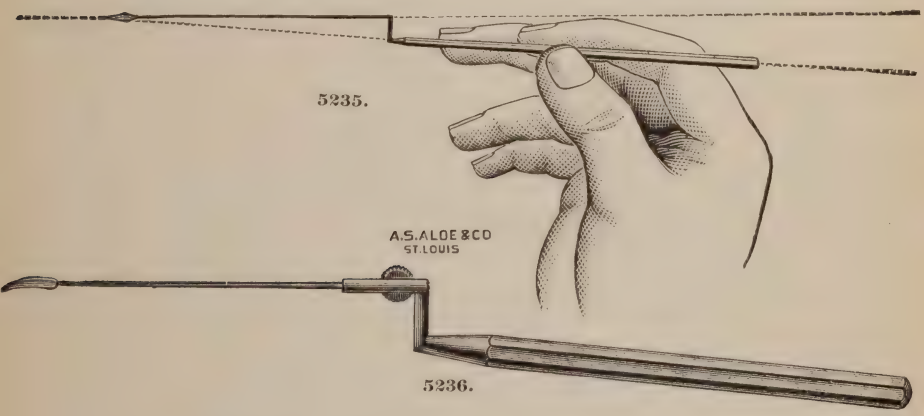

"The essential features of the new instrument are these: The aluminum handle is of dimensions and weight most favorable to delicate and accurate manipulation. Its long axis passes directly through the operative extremity of the operating shaft, which is, therefore, as in a straight instrument, wholly under control, and can be made to operate at will, in any direction, rectilinearly, or curvilinearly, or to rotate without displacement.

"The handle is joined to the operating shaft by a lateral shaft of length only sufficient to permit, in operation, the greatest illumination and vision along and beyond the

operating shaft. For an operator whose finger-tips are uncommonly slender, or who handles the instrument with his finger tips, this lateral shaft may with advantage be constructed somewhat shorter than usual.

"The operating shaft is of the smallest dimensions permissable under the operative requirements, and is at right angles to the lateral shaft, thereby enabling the operator to hold the handle as near as possible to his work and to operate with a finger-rest. If the reflection of light from the lateral shaft be annoying to an operator, he can avoid this by having the lateral shaft made at an obtuse angle to

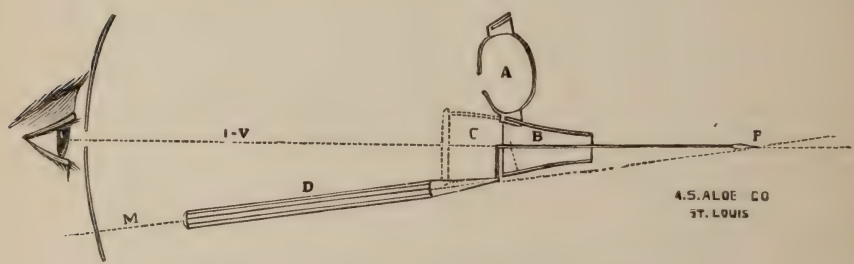

Showing Application of Numbers 5235 and 5239.

the operating shaft, which will deflect the rays of light. This will, however, place the handle somewhat further from the operative extremity.

"If desired, the shaft and handle may be constructed separately, and adjustable, with socket and set-screw, so that with one handle may be used, as required, shafts having dissimilar operative extremities. The instrument may be constructed of any size, material, or operative character as desired for aural, nasal, or other orificial surgery."

In conclusion, it is hoped that the production of these instruments may prove suggestive to others more inventive, stimulate interest and research in this department of

aural surgery, and render more generally available the valuable resources which in these operations have been discovered to us by our esteemed fellow-members.

[FOOTNOTE. In a letter sent to the Secretary, but received *after* the Annual Meeting of the Society had adjourned, Dr. B. gives credit to Dr. E. D. Spear of Boston, for his "Aural Speculum," a description of which only reached him after this paper had been sent. J. J. B. V.]

A CASE OF AURAL REFLEX OF UNUSUAL CHARACTER DUE TO IMPACTED CERUMEN.

By Samuel Theobald, M. D., *Baltimore, Md.*

Mrs. M., æt. about forty-two, the mother of a large family of children, enjoyed good general health and was far from being of a nervous temperament. For six months previous to consulting me she had been annoyed at times by a troublesome cough, which she found was brought on or aggravated by touching or attempting to clean one of her ears (the right). She also said that during this period she had had from time to time spells of difficulty in swallowing, in fact, at times absolute inability to swallow food, and this symptom, too, like the cough, she found was increased, or attacks of it precipitated, by any sort of mechanical irritation of the ear. For two weeks there had been an aggravation of these symptoms, accompanied by slight pain in the ear and occasionally by a feeling of oppression, as though there were a failure of the heart's action.

Becoming alarmed at this change for the worse, she consulted a throat specialist, who found the throat in normal condition, and, suspecting the ear might be the source of trouble, sent her to me. A glance into the right ear showed the presence of a plug of cerumen of moderate size, which occupied a deeper part of the canal than usual and appeared to be in contact with the tympanal membrane. It seemed probable that the plug had been driven into the inner extremity of the canal by the unsuccessful attempts which had been made to remove it. The appearance of the left ear was normal.

The cerumenous mass was removed without difficulty by syringing, and the ear found to be free from inflammation, the drumhead showing only the slight hyperæmia which commonly follows the use of the syringe. The hearing of this ear for the voice was found to be only slightly below normal, while the watch was heard at 8″. The hearing distance for the watch for the other ear was 11″ and the voice was heard normally.

The removal of the plug of cerumen was immediately followed by the disappearance of the cough and of the other unpleasant symptoms which I have described, and four weeks have now elapsed without any signs of their return. In response to a recent letter of inquiry as to her present condition, the patient writes: "I have had no return of the cough or the difficulty in swallowing since you operated on my ear. I can eat without fear now, and feel much better in every way, for I was really afraid to eat before, the sensation of inability to swallow was so unpleasant, not to say alarming. I can hardly believe it was caused by such a small thing, but, as I am perfectly relieved, I suppose it must have been."

I have not had the opportunity to make an extended search of otological literature for cases similar in character to the one reported, but in Burnett's work upon the ear (p. 355) I found this statement: "Both Senac and Tissot observed difficulty in swallowing in cases of earache which the former attributed to sympathy (consensus) between the pharynx and the ear, but which the latter observes 'is connected with a slight inflammation of certain of the muscles of deglutition'." The former explanation is doubtless the one which applied in the case of Mrs. M.

DISCUSSION.

Dr. Randall:—There is on record a similar case in which for six months or more the patient was supposed to have phthisis on account of the difficulty in swallowing, the cough, and the emaciation. Changes of climate and various other measures were tried before the true nature of the case was discovered.

THE STATISTICS OF EAR DISEASE.

WITH TABULATION OF 4785 RECENT PATIENTS (5412 DISEASES).

By B. ALEXANDER RANDALL, M. D., *Philadelphia, Pa.*

The matter of the statistical reports of dispensary and private practice contains many important questions beside the one of nomenclature, which comes over to us from last year. It is surely of great weight that uniformity should so far prevail as to make different reports comparable; yet it takes little inquiry to bring to light that in many an institution there is no consensus of view and statement among the surgeons, and that its report is at variance with itself.

Passing over the generally accepted point that only the new cases shall be given, to the exclusion of all old cases from previous years, in the annual report, the extremely important question meets us, shall we record patients or diseases, or both? To report only individuals leaves out of count many noteworthy conditions and gives occasion for false estimates as to their relative frequency. On the other hand, multiple diagnosis may immensely pad out the statistics according to the arbitrary choice of the recorder, with little or no clue to the facts as to individuals. So a double set of figures more than justifies its cumbersomeness. The matter of sex, like that of childhood or maturity, in its bearing upon various diseases, is frequently most worthy of note, as witness many interesting, although inconclusive, studies. In like manner, the question of which side is affected by predeliction in certain diseases or of the bilateral

occurrence of the lesion, has come into importance of late, and well deserves record and report. The statement of the results of treatment, always delicate, seems more so here than in most lines of medicine: for the surgeon who looks with complacency at semi-anchylosed joints in his own practice or the physician who would question your sanity if you found fault with the cure of a pleurisy which left adhesion, expects absolutely perfect results of the aurist.

The nomenclature to be employed and the minuteness of the subdivisions of the cases falling under the wider diagnostic heads, need also some unanimity of choice. The Latin names have almost universal use even among those who rather strive to use the vernacular; so we need only be more precise and consistent in our usage to give a full and ready answer to the first of these questions; the latter will largely solve itself with practice, since every one will feel the limitations as to the complexity of any table which he wishes to have published. Only by detailed case-histories can all the shades of differing yet similar cases be set forth; but anything of this sort will find its level in remark column, footnote, or extended narration.

The value of careful statistical reports of private and dispensary work in its influence upon the worker himself, must be apparent to any one who considers it. Nothing short of full individual records can be adequate and satisfactory; but too many find the data sadly lacking in their neglected records when anything moves them to a search, —omissions which are annoying and hampering when the return of the patient raises questions as to the previous condition and treatment. But far more mortifying are such blanks when one undertakes to set forth his results and finds the numerous and serious gaps. Yet this very mortification, or the fear of it, is one of the best spurs to greater diligence in studying out and recording cases

which might otherwise be irretrievably, though not very decently, buried in our case books. Hence patients will probably profit by being treated with better insight at first and with fuller understanding and recollection later, if the worker is conscious that he has a formal account to give of the details of his stewardship; and the surgeon, possessed of objective data as to measures and results in all his cases, will gain more than a vague and scattered impression of what he has found most efficient in his practice. Thus his work should be constantly and positively instructive; and his records will probably indicate increasing success, especially in those directions in which improvement is most important, yet most difficult. The same gain will naturally redound to the advantage of the student, who now looks longingly but vainly at the reports of many large clinics, wishing that he could accept with less scepticism the showings which they present.

The discussion of the statistics of ear disease at the Berlin Congress will probably lead to some action in the coming Congress at Rome, since it made very evident the discrepancies now existing and gave indications of the steps towards their elimination. In his recent article in Schwartze's Hand-buch, Bürkner has set forth his deliberate judgment as to the details. He holds that diseased conditions should be the basis of report, that age and sex should be noted, and that results should be recorded as "healed" only when the restoration is practically perfect, anatomically and functionally. No rigid line can be rationally drawn to cover fully all cases; but common sense will clearly indicate in the majority of instances what success can be fairly claimed. Bürkner has utilized such data from his own wide practice and to a less degree from the reports of others; yet the statements thus far made generally leave indefinite many points which might quite readily be explicitly stated. Tabulations are cum-

bersome and awkward things for publisher and reader; but they can be made very full and valuable with no great increase in their complexity. Several tables may be more convenient for the recording of various phases of the same series of cases; yet a single table can generally be made to show all of this, and much of the inter-relations otherwise left unstated.

As an illustration of this, a tabulation is here presented of my last four years of practice, giving the figures as to age, sex, and ear affected for each of the conditions diagnosticated, as well as the number of individuals, adult and juvenile, grouped according to the major diagnosis. The therapeutic results have not been given, because my records are often too imperfect to show them with adequate certainty. In future years it will be easier to use this table almost as a starting-point, subdividing its columns so as to show the results of treatment; and by a monthly recording therein of every new case and a revising of the records of the preceding month or two, to make this table and the original records upon which it is based, full, reliable, and up to date, in a way that is now almost impracticable. Even such a study as the compilation of this table has enforced, has brought into view many a record to which needed additions could still be made from memory or by reason of a recent visit of the patient; and I look for much profit from the review. Thus only can my dispensary services be made as instructive as they should be to myself and others; and I can warmly recommend the method to the notice of my colleagues as abundantly repaying the trouble entailed in such a revision.

Tabular Statement of 4785 Patients (5412 Diseased Conditions) in 1889–92.

Personæ		Nomina Morborum.	Masculini.						Feminine.						Totales
			Adulti.			Infantes.			Adultæ.			Infantes.			
Adulti	Infan		A. D	A. S.	A. U.	A. D.	A. S	A. U.	A. D.	A. S.	A. U.	A. D.	A. S	A. U.	
1	2	Auriculæ helicis, Abscessus		1			1					1			3
1		" " Ambustio		1											1
1		" " Congelatio			1										1
1		" " Cystoma								1					1
	1	" " Deformitas										1			1
8	25	" " Eczema	1	1	1	1	1	17		2	5	1	1	15	46
3		" " Epithelioma	2		1										3
2		" " Erysipelas	1							1					2
1		" " Hæmatoma		1											1
1	2	" " Herpes	1			1								1	3
	3	" " Microtia						1				2			3
1		" " Perichondritis	1												1
	4	" " Reduplicatio				2	1							1	4
1		" " Ulceratio		1											1
3	9	" lobulæ. Abscessus		3		1	1					1	1	5	12
1	1	" " Fibroma							1					1	2
1		" " Laceratio		1											1
2	2	Abscessus parauricularis	1	2			1					1			5
	1	Adenitis "					1	3						3	7
371	140	Meatus, Accumulatio ceruminis	57	58	154	16	15	39	27	23	74	14	15	45	537
1	1	" Atresia	1	1			1		1			1	1	1	7
1		" Caries	1								1				2
6	32	" Corpus alienum	3	1		4	3	6	3	3		8	11	4	46
80	11	" Eczema (Otitis ext. dif.)	4	13	26	2	9	13	12	8	28	8	1	15	139
1		" Exostosis			1		1			2		1			5
57	35	" Furunculosis (Ot. ext. cir.)	11	10	7	9	9	6	12	15	11	8	9	5	112
	4	" Granulatio				2				1			2		5
		" Hyperostosis			2		1			1		1			5
1		" Neoplasma							1						1
5	2	" Otomycosis	2	1	3			2		1	1				10
1	1	" Trauma		1										1	2
552	276	Totales, Auris externæ	86	96	196	38	45	87	57	58	120	48	41	97	969
2	1	Membrana tymp., Myringitis		1	1		2					1			5
		" " Ecchymosis								1					1
5	3	" " Ruptura	2	3								3			8
2	3	" " Vulnus	1	1			1					1	1		5
113	93	Tympani. Otitis med. acuta simp.	19	28	21	11	11	13	20	16	18	21	15	30	223
46	37	" " " mucosa	11	12	10	5	5	7	10	5	6	8	7	10	96
19	9	" " " serosa	7	8	4	3	2	3	3	1	1	2	1	3	38
1	2	" " " c. paral. F.		1									2		3
47	22	" " catar. subac.	6	4	15		1	11	3	8	19	3	2	10	82
925	440	" " " chr. muc.	46	32	404	10	17	190	25	32	392	7	13	230	1395
89	15	" " " " adhes.	9	7	32	1	1	8	2	2	39			6	107
3		" " " c. m. labyr.			1						2				3
158	245	" " suppur. acuta	48	39	15	54	38	53	25	24	13	60	44	44	457
8	6	" " " c. perf. Shrap.	3	1		1	2		3	1		1	1	1	14
7	4	" " " c. empy. mast.	2	2		1				3		2		1	11
331	434	" " " chron.	68	53	59	80	67	129	56	45	54	79	67	161	918
43	34	" " " c. perf. Shr.	8	15	2	7	7	4	11	6	1	6	10		77
8	6	" " " c. car. Tym.	3	2	1		1			3		3	2	1	16
15	34	" " " " Mast.	4	5		11	8	1	1	5		7	7		49
7	5	" " " c. cholest.	4	1		1	1			1	1	2	1		12
36	39	" " " c. granul.	6	10	4	13	11	7	10	5	1	10	9	9	95
92	23	" " " effecta	37	40	9	14	11	3	22	18	11	17	13	2	197
69	20	" " catar. "	5	6	22	2	1	10	7	5	27	5	2	6	98
2	1	" Neuralgia			1	1					1			1	4
2028	1476	Totales, Auris mediæ	289	271	598	213	186	439	198	181	586	228	197	515	3914
1		Labyrinthi. Concussio		1											1
8	2	" Inflam. acuta	4	1				2	3						10
7	7	" " chronica		1	5			3		1				7	17
	7	Surditas						4						3	7
16	16	Totales, Auris internæ	4	3	5			9	3	1				10	35
223	1	Narium et Pharyngis													297
192	5	Normal, undiagnosticated, etc.													197

DISCUSSION.

Dr. Risley: — I think this a matter of considerable importance. As Dr. Randall suggests, we should have not only a record of the cases with the salient forms of disease, but also if incidental things are present, they should be placed on record so as not to be lost. In my private case books, I follow this plan of including all forms of existing trouble in the nosology, *e. g.*, if a patient comes with hordeolum, and there is also hyperopic astigmatism or strabismus, these are also recorded. The nosology in my private case books is thus much more complete than that in the hospital records, where we have sought only to make the number of diseases and the number of patients treated strictly correspond to each other. By this plan many interesting conditions are entirely lost to view.

Dr. Gruening: — Is it necessary to have a Latin nomenclature? I think it would be far better to make it in English.

ALPHABETICAL INDEX

OF

OTOLOGICAL LITERATURE, FROM JULY 31, 1892, TO JULY 31, 1893,

COMPILED BY

GORHAM BACON, M. D., NEW YORK, N. Y.

Adams, J. L. A case of thrombosis of the lateral sinus. Arch. of Otol. Vol. XXII. No. 2.

Adams, J. L. Report of fifteen cases of mastoiditis. N. Y. Eye and Ear Infirmary Reports, Vol. I. part 1. Jan. 1893.

Albespy. Histoire d'un bouchon épidermique. Annales des mal. de l'oreille, March, 1893. Rev. de laryn., d'otol. March 15, 1893.

Albespy. Note sur le pityriasis de l'oreille. Rev. de laryn., d'otol. Aug. 1, 1892.

Albespy. Kyste du pavillon de l'oreille. Opération. Guérison sans déformation. Rev. de laryn., d'otol. Dec. 15, 1892. Echo Méd. No. 2, 1893.

Alderton, H. A. Seborrhœic affections of the external ear. N. Y. Eye and Ear Infirmary Reports, Vol. I. part 1. Jan. 1893.

Allen, S. E. The mastoid operation. (Review.) Arch. of Otol. Vol. XXII. No. 1.

American Otological Society. Twenty-fifth Annual Meeting. N. Y. Med. Record, Aug. 6, 1892.

American Otological Society. Twenty-sixth Annual Meeting. N. Y. Med. Record, July 29, 1893.

Apfelstedt. Contribution à l'étude casuistique du développement anormal de l'oreille externe. Inaug. Dissert. Jena, 1892.

Atkinson, T. K. Apparent double labyrinthine deafness. Lancet, Aug. 27, 1892.

Ayres, S. C. Hæmatoma auris. Annals of Ophth. and Otol. Jan. 1893.

Baber-Cresswell. Auditory nerve deafness treated by pilocarpin. Brit. Med. Journal, Feb. 25, 1893.

Bacon, Gorham. Alphabetical index of otological literature from July 1, 1891, to July 31, 1892. Trans. Amer. Otolog. Soc. Vol. V. No. 2.

Bacon, Gorham. A case of mastoid disease following an operation for the removal of adenoid vegetations. Trans. Amer. Otolog. Soc. Vol. V. No. 2.

Bacon, Gorham. A case of suppurative otitis media in which it was necessary to perforate both mastoid processes, and further complicated by typhoid fever. Recovery. N. Y. Eye and Ear Infirmary Reports, Vol. I. part 1. Jan. 1893.

Bacon, Gorham. Morceau de coton, simulant un séquestre osseux, enlevé du conduit auditif. Rev. de laryn., d'otol. Aug. 1, 1892.

Bacon, Gorham. Tumors of the auricle. Annals of Ophth. and Otolog. July, 1893.

Baratoux, J. Guide pratique pour le traitement des maladies des oreilles. (Review.) Ann. des mal. de l'oreille, Oct. 1892.

Baratoux. Guide pratique pour l'examen des maladies du larynx, du nez, et des oreilles. (Review.) Arch. of Otol. Vol. XXII. No. 1.

Baratoux. Guide pratique pour l'examen des maladies du larynx, du nez, et des oreilles. (Review.) Arch. f. Ohrenh. XXXIV. Bd. 1 und 2 Heft.

Baratoux. Guide pratique pour l'examen des maladies du larynx, du nez, et des oreilles. Rev. de laryn., d'otol. Aug. 1, 1892.

Barck, C. Contributions to affections of the petro-mastoid. Annals of Ophth. and Otol. Apr. 1893.

Barclay, R. Closure of the ear by growths of bone; removal of bony obstruction; cure of otorrhœa and of deafness. Three cases; description of operations, instruments, etc. Med. News, Apr. 22, 1893.

Barclay, Robert. The best bend of shaft and handle in instruments for operation in the depth of the ear canal. Arch. of Otol. Vol. XXII. No. 2.

Barnick. Examen de l'œil dans l'otite moyenne purulente. Inaug. Dissert. Halle, 1892.

Barr, Thomas. A striking case of simulated deafness. Arch. of Otol. Vol. XXI. No. 4.

Barr, Thomas. Case of aural exostosis, causing purulent retention in the deep parts of the ear, removed with the electric snare. Brit. Med. Jour. July 2, 1892.

Barr, T. Treatment of the nose and throat as a source of middle ear disease. Lancet, Dec. 17, 1892.

Barret, R. D. Acute suppurative otitis media following la grippe. N. Y. Med. Record, Mar. 25, 1893.

Barret, R. D. Furunculosis of the external auditory canal. Annals of Ophth. and Otology, July, 1893.

Barth, A., and Hartmann, A. Report on the progress of otology during the first half of the year 1892. Arch. of Otol. Vol. XXII. No. 1.

Bates, W. H. Adenoids as a cause of chronic deafness in adults. Boston Med. and Surg. Jour. June 29, 1893.

Bates, H. E. A case of otitis media developing grave symptoms of brain pressure and ending in recovery without operation. N. Y. Med. Jour. Jan. 14, 1893.

Beausoleil. Revue statistique des maladies de la gorge, du larynx, des oreilles, et du nez. Rev. de laryn., d'otol. etc. Apr. 1, 1893.

Bettman, Boerne. A case of acute suppuration of the middle ear, accompanied by cone-shaped bulging of the membrana tympani. Annals of Ophth. and Otol. April, 1893.

Bezold, Fr. Einige weitere Mittheilungen über die continuirliche Tonreihe, insbesondere über die physiologische obere und untere Tongrenze. Zeitschr. f. Ohrenh. Bd. XXIII. Heft 3 und 4.

Bezold, Fr. Some further investigations upon the continuous tone-series, especially with reference to the physiological upper and lower tone limit. Arch. of Otol. Vol. XXII. No. 2.

Bezold, Fr. Untersuchungen über das durchschnittliche Hörvermögen im Alter. Zeitschr. f. Ohrenh. Bd. XXIV. Heft 1 und 2.

Bieliakof. De l'influence des affections de l'organe de l'ouïe sur l'origine et la marche des troubles mentaux. Clinique, Sept. 1, 1892.

Binaud. Des blessures de l'oreille par armes à feu. Arch. gen. de médecine. Apr. and May, 1893.

Blake, C. J. Exploratory opening of the tympanum and subsequent operations in the middle ear without general anæsthesia. Boston Med. and Surg. Journal, Apr. 20, 1893.

Blake, C. J. Ouverture exploratrice du tympan et opérations subséquentes dans l'oreille moyenne, sans anesthésie générale. Ann. des mal. de l'oreille, June, 1893.

Blake, C. J. Mastoid cases. Trans. Amer. Otol. Soc. Vol. V. No. 2. Boston Med. and Surg. Journal, Sept. 15, 1892.

Blake, C. J. Middle ear operation. Trans. Amer. Otol. Soc. Vol. V. No. 2. Boston Med. and Surg. Journal, Sept. 20, 1892.

Blake, C. J. Operation for removal of the stapes without ether. Boston Med. and Surg. Journal, Dec. 8, 1892.

Blake, C. J. Recent progress in otology. Boston Med. and Surg. Journal, Jan. 12, 1893.

Blake, C. J. Removal of the stapes. Arch. of Otol. Vol. XXII. Nos. 1, 2, and 3.

Blake, C. J. Operation for removal of the stapes. Boston Med. and Surg. Journal, Nov. 10, 1892.

Blake, C. J. Opération de l'extraction de l'étrier. Ann. des mal. de l'oreille, Jan. 1893.

Bloch, E. Das binaurale Hören. Zeitschr. f. Ohrenh. XXIV. Bd. 1 und 2 Heft.

Bonnier. Réflexes des corps étrangers du conduit. Bull. et mém. de la Soc. de Laryngologie, Feb. 1893.

Bonnier. Sur les fonctions otolithiques. Soc. de Biologie, Feb. 18, 1893.

Bonnier. Sur les fonctions otocystiques. Soc. de Biologie, Apr. 15, 1893.

Bonnier. Sur les fonctions tubo-tympaniques. Soc. de Biologie, Nov. 26, 1892.

Braislin, W. C. Otitis media purulenta following amputation of the uvula. N. Y. Med. Journal, March 4, 1893.

Buck, A. H. The strongly counter-irritant effects of the usual mastoid operation. N. Y. Med. Record, July 29, 1893.

Bürkner. Bericht über die 2te Versammlung der deutschen otologischen Gesellschaft am 20 und 21 Mai, 1893, in Frankfurt a. M. Arch. f. Ohrenh. 35 Bd. 1 und 2 Heft.

Bürkner. Bericht über die in den beiden Etatsjahren 1890-91 und 91-92, in der Poliklinik für Ohrenkrankheiten zu Göttingen beobachteten Krankheitsfälle. Arch. f. Ohrenh. XXXIV Bd. 4 Heft.

Bürkner. Lehrbuch der Ohrenheilkunde für Studirende und Aerzte. (Review.) Zeitschr. f. Ohrenh. XXIV. Bd. 1 und 2 Heft.

Burnett, C. H. Observation of a case of acute purulent otitis media; cerebellar abscess, and death in three weeks. Arch. of Otol. Vol. XXII. No. 3.

Burnett, C. H. System of diseases of the ear, nose, and throat. (Review.) Annals of Ophth. and Otology, July, 1893.

Caldwell, G. W. Transillumination of the mastoid cells as a means of diagnosis of mastoiditis interna suppurativa. N. Y. Med. Jour. July 15, 1893.

Camelot. Septico-pyohémie dans le cours d'une otite moyenne suppurée; phlegmons multiples; guérison. Echo Méd. No. 5, 1893.

Campbell, J. T. The treatment of acute catarrhal inflammation of the middle ear. Annals of Ophth. and Otol. Jan. 1893.

Caseneuve. Action thérapeutique de l'antipyrine dans les otites et les cystites. Lyon Méd. No. 2, 1893.

Castaneda. Contribution au raclage de la caisse dans l'otorrhée chronique. Arch. intern. de rinol. etc. Jan. 25, 1893.

Castex. Des effets de la dynamite sur l'oreille. Soc. franç. d'Otol. et de Laryngol. de Paris. 12-15 May, 1893.

Chaput. De la résection large du rocher dans le traitement de la carie de cet os. Rev. intern. de rinol. etc. No. 5, 1893.

Chatellier. Traitement de l'eczéma de l'oreille. Bull. et Mém. de la Soc. de Laryngol. etc. May, 1893.

Chauvel. Du traumatisme dans les affections de l'appareil auditif. Acad. de Méd. Sem. Méd. Sept. 28, 1892.

Chauvel. Septico-pyohémie consécutive à l'otite moyenne suppurée. Bull. Méd. July 3, 1892.

Chauvel. Du traumatisme dans l'étiologie des affections de l'appareil auditif. Arch. inter. de Laryngol. etc. No. 3, 1893.

Chavannaz. Hématome du pavillon de l'oreille. Jour. de Méd. de Bordeaux, No. 3, 1893.

Cheatle, Arthur H. Hypertrophic condition of the tympanic mucous membrane in an infant. Arch. of Otol. Vol. XXII. No. 3.

Cholewa. Ueber die Sondirbarkeit der Stirnhöhlen. Monatschr. f. Ohrenh. Sept. 1892.

Clutton, H. H. A successful case of ligature of the internal jugular vein and trephining lateral sinus in an ear case, whilst the symptoms of pyæmia were well pronounced. Brit. Med. Journal, 1893.

Compte-rendu de la Société Belge d'otologie et de laryngologie. Rev. de laryn., d'otol. July 15, 1893.

Compte-rendu de la Société Royale de Budapest. Rev. de laryn., d'otol. etc. June 1, 1893.

Compte-rendu de la Société d'ophthalmologie, d'otologie, de rhinologie et de laryngologie de Bordeaux et du Sud-Ouest. Rev. de laryn., d'otol. March 15, 1893.

Compte-rendu de la Société d'otologie et de laryngologie de Paris. Rev. de laryn., d'otol. etc. Dec. 15, 1892.

Compte-rendu du 1er Congrès de la Société Italienne de laryngol., d'otol. et de rhinologie. Rev. de laryn., d'otol. etc. Dec. 15, 1892.

Compte-rendu de la Société Otologique Allemande. Rev. de laryn., d'otol. Nov. 15, 1892.

Compte-rendu de la Société Otologique Américaine. Rev. de laryn., d'otol. Oct. 1, 1892.

Compte-rendu de la Société des Médecins de Halle. Rev. de laryn., d'otol. Sept. 1, 1892.

Constade, A. Du triangle lumineux de la membrane du tympan. Ann. des mal. de l'oreille, June, 1893.

Constade. Des méthodes employées pour retirer le pus de la cavité tympanique et spécialement de l'aspiration du pus. Bull. et Mém. de la Soc. de Laryn. No. 4, 1893.

Corradi. Importance du diagnostic de la perception des sons par la voie aérienne et par la voie cranienne. Rev. intern. de rhinol., otol. etc. No. 12, 1892.

Corradi. Importance diagnostique de la perception des sons par la voie cranienne et aérienne dans les maladies de l'oreille. Arch. ital. di otologia. fasc. 1 et 2, 1893.

Cozzolino. Thrombo-phlébite de la dure-mère avec lésion locale infectieuse de l'appareil auditif, du rocher pétreux et des parties latérales. Malatt. dell'orecchio. etc. No. 4, Ap. 1893.

Cozzolino. Sur l'otite moyenne pyogène. Gazz. degli Ospitali. No. 43, 1893.

Cozzolino. Sur l'otite catarrhale. Gazz. degli Ospitali. No. 46, 1893.

Cozzolino. Progrès dans le prognostic et la thérapeutique des lésions de l'appareil auditif. Arch. Intern. di Rinologia, No. 29, May, 1893.

Cozzolino. The hygiene of the ear. Translated by James Erskine. (Review.) Lancet, Jan. 14, 1893.

Crawford, W. S. Squamous epithelioma of the external ear. Lancet, March 11, 1893.

Dalby, Sir William. Diseases and injuries of the ear. (Review.) Lancet, May 13, 1893.

Dalby, Sir William. Strange incidents in practice. Lancet, Feb. 4, 1893.

Dalby, Sir W. Cancer of the ear. Lancet, July 2, 1892.

Dalby, Sir W. Nasal douche or syringe. Lancet, Dec. 24, 1892.

Dean, Henry Percy. A case of cerebellar abscess successfully treated. Lancet. July 30, 1892.

Delstanche. De l'emploi de la vaseline dans certaines affections de l'oreille moyenne. Semaine méd. No. 60, 1892.

Delstanche. Des injections de vaseline dans la caisse par la voie de la trompe. Rev. intern. de rhinol., otol. etc. No. 12, 1892.

Dench, E. B. A case of epithelioma of the auricle. Arch. of Otol. Vol. XXII. No 2.

Dench, E. B. Operative measures for the relief of chronic suppurative and non-suppurative inflammation of the tympanum. N. Y. Eye and Ear Infirmary Reports, Vol. I. part 1. Jan. 1893.

Dennert. Zur Bedeutung des Schallquantums für die Hörprüfung. Arch. f. Ohrenh. Bd. XXXIV. Heft 3.

Doyle. Two cases of disease of mastoid and petrous portions of temporal bone in connexion with disease of the ear. Lancet, Jan. 7, 1893.

Duane, A. Common sense in the treatment of discharge from the ear. N. Y. Med. Record, Oct. 8, 1892.

Du Fongeray, Hamon. Note sur quelques points de l'anatomie chirurgicale de la caisse du tympan. Ann. des mal. de l'oreille, Jan. 1893.

Du Fongeray, Hamon. Notes sur les polypes de l'oreille. Annales des mal. de l'oreille. Aug. 1892.

Du Fongeray, Hamon. Note sur la chirurgie de l'oreille moyenne. Gaz. des Hôpit. No. 48, 1893.

Du Fongeray, Hamon. Chirurgie de l'oreille moyenne. Bull. méd. No. 28, 1893.

Eichler, O. Anatomical examination of the paths of the blood-current in the labyrinth of the human ear. (Review.) Arch. of Otol. Vol. XXII. No. 1.

Eichler. Anatomische Untersuchungen über die Wege des Blutstroms im menschlichen Ohrlabyrinth. (Review.) Arch. f. Ohrenh. XXXIV. Bd. 1 und 2 Heft.

Ellis, W. Gilmore. Ulcerative tuberculous affection of the lobe of the ear. Lancet, Feb. 25, 1893.

Emerson, J. B. A case of pyæmia, following acute suppurative otitis. Recovery. Trans. Amer. Otolog. Soc. Vol. V. No. 2.

Estrada. Chéloïde du lobule de l'oreille. Sem. Méd. July 9, 1892.

Eulenstein. Ueber pyämische Metastasen bei acuten Erkrankungen im Schläfenbein. Monats. f. Ohrenh. June, 1893.

Ewald. Physiologische Untersuchungen über das Endorgan des Nervus octavus. (Review.) Arch. f. Ohrenh. XXXIV. Bd. 1 und 2 Heft.

Felici. Du massage vibratoire appliqué à l'oto-rhino-laryngologie. Rev. intern. de rhinol. etc. No. 3, 1893.

Felici. Guérison d'un cas de syphilis labyrinthique bilatérale. Rev. intern. de rhinol., otol. etc. No. 12, 1892.

Ferreri, G. Sur l'emploi de la fluoroglucine dans la décalcification du labyrinthe. Boll. della R. Accad. Med. di Roma, ann. XVIII. fasc, 1.

Ferreri. Carie nécrotique et séquestres de l'os temporal chez l'enfant. Arch. ital. di Otologia. No. 3, 1893.

Field, G. P. The pathology and treatment of suppurative diseases of the ear. Brit. Med. Jour. Dec. 3, 10, and 17, 1892.

Field, G. P. A manual of diseases of the ear. (Review.) Lancet, March 18, 1893.

Flesch. Etiologie de l'otite moyenne suppurée chez les enfants en bas âge. Med. Neuigk. No. 49, 1892.

Freudenthal, W. Two cystoid polypi of the middle turbinated bone. Arch. of Otol. Vol. XXII. No. 3.

Friedenwald. A case of syphilis of the external auditory canal. Maryland Med. Jour. Jan. 28, 1893.

Gaston, P. Société de laryngologie, otologie, et rhinologie de Paris. Ann. des mal. de l'oreille, Jan. Feb. and Mar. 1893.

Gellé. Spasme réflexe binauriculaire causant la surdité. Bull. de la Soc. de biologie, 1892, p. 956.

Gellé. Trois faits de troubles de l'ouïe liés à une névropathie. Ann. des mal. de l'oreille, Dec. 1892.

Gellé. Une feuille d'observations d'otologie. Bull. et mém. de la soc. de laryngol. May, 1893.

Gellé. Otite suppurée. Signes cérébraux, trépanation, autopsie. Ann. des mal. de l'oreille, July, 1893.

Gellé. Service otologique. Tribune Méd. No. 48, 1892.

Gellé. L'audiphone appliqué au diagnostique otologique. Tribune Méd. Sept. 1, 1892.

Giampetro, E. Essai de classification des centres auditifs en rapport avec la fonction du language. Deduction clinique sur les diverses formes d'aphasie. Ann. des mal. de l'oreille, Mar. 1893.

Gomez de la Mata. Otite moyenne scléreuse avec sclérose de la caisse. Arch. intern. de rinologia, No. 27, March, 1893.

Gomperz, B. Ueber die Entwicklung und den gegenwärtigen Stand der Frage von der Excision des Trommelfelles und der Gehörknöchelchen. Monats. f. Ohrenh. Dec. 1892.

Gradenigo. Missbildungen der Ohrmuschel. Arch. f. Orhenh. XXXIV. Bd. 4 Heft.

Gradenigo. Sur l'état de la transmission osseuse dans l'otite moyenne. Rev. intern. de rinol. etc. No. 12, 1892.

Gradenigo. Sur les manifestations auriculaires de l'hystérie. Arch. ital. di Otologia, fasc. 2, 1893.

Gradenigo. Sur un cas de périchondrite séreuse symétrique des deux pavillons de l'oreille. Arch. italiano di otologia. Jan. 1893.

Gradenigo, G. Sur un cas de névrite auditive probable bilatérale due à l'influenza. Gaz. degli ospitali, Dec. 31, 1892.

Gradenigo, G. Sur les charactères cliniques présentés par les lésions du nerf acoustique. Gaz. degli ospitali, Oct. 13, 1892.

Gradenigo. Ueber einen Fall von partiellen Mangel des Ohrläppchens. Arch. f. Ohrenh. Bd. XXXIV. Heft 4.

Gradenigo. Contribution à la casuistique de la fistule mastoïdienne permanente. Sordomuto, No. 22, '92.

Gradenigo, G. Sur un cas de pseudo-photesthésie d'origine tactile. Ann. des mal. de l'oreille, Aug. 1892.

Gradenigo. Sur l'énergie fonctionelle du nerf acoustique. Gazz. degli ospitali, No. 144, 1892.

Gradenigo, G. Ein neues Modell eines osteo-tympanalen Hörmessers. Zeitschr. f. Ohrenh. Bd. XXIII. Heft 3 und 4.

Gradenigo, G. Ueber Diplacusis monoauralis. Zeitschr. f. Ohrenh. Bd. XXIII. Heft 3 und 4.

Gradenigo, G. Ueber die klinischen Merkmale der Affectionen des N. acusticus. Zeitschr. f. Ohrenh. Bd. XXIII. Heft 3 und 4.

Gradenigo. On the clinical signs of the affections of the auditory nerve. Arch. of Otol. Vol. XXII. No. 2.

Grazzi. Corps étrangers du conduit auditif externe. Naples, 1892.

Green, J. Orne. A series of cases of new growths of the ear. Arch. of Otol. Vol. XXII. No. 3.

Green, J. Orne. Osteoma of the mastoid. Arch. of Otol. Vol. XXII. No. 3.

Greene, H. E. Foreign body in the tympanum. N. Y. Med. Jour. March 25, 1893.

Gruber, J. Bericht über die in der Klinik für Ohrenkranke des Prof. Dr. Joseph Gruber im Jahre 1891 ambulatorisch behandelten Kranken. Monats. f. Ohrenh. Oct. 1892.

Grunert, C. Aus der Königl. Universtäts-Ohrenklinik des Herrn Geh. Med. Raths Prof. Dr. Schwartze. Das otitische Cholesteatom. Berl. klin. Wochenschr. Apr. 3, 1893.

Guermonprez. Ablation d'une portion de l'antitragus; autoplastie de cette partie du pavillon de l'oreille. Jour. des Sc. Méd. de Lille, No. 30, 1892.

Guermonprez et Cocheril. Deux opérations d'épithélioma du pavillon de l'oreille suivies d'autoplastie. Jour. des Sc. Méd. de Lille, No. 33, 1892.

Guermonprez et Cocheril. Trois operations d'épithélioma du pavillon de l'oreille, suivies d'autoplastie. Rev. de laryn., d'otol. Oct. 1, 1892.

Hardie, T. M. Notes from current otological literature. Annals of Ophth. and Otol. Oct. 1892.

Harrison, Lieut.-Col. C. E. A case of cerebellar abcess secondary to ear disease treated by trephining and drainage of abscess; death. Lancet, Oct. 1, 1892.

Hartmann. Skioptikon-Demonstration von Präparaten des Ohres, der Stirnhöhle, der Highmorshöhle und der Nasenscheidewand. (Review.) Monats. f. Ohrenh. Apr. 1893.

Hechelmann, H. W. Fremdkörper, der 20 Jahre im Gehörgang gesessen hatte. Zeitschr. f. Ohrenh. XXIII. Bd. 3 und 4 Heft.

Hedrich. Traitement autoplastique d'un cas de macrotie. Gaz. méd. de Strasbourg, No. 2, 1893.

Heiman, Th. Fünf Fälle von otitischen Hirnabscessen nebst kurzer Beschreibung der otitischen Hirnabscesse im Allgemeinen. Zeitschr. f. Ohrenh. XXIII. Bd. 3 und 4 Heft.

Heiman, H. On five cases of otitic brain abscess with a short description of otitic brain abscesses in general. Arch. of Otol. Vol. XXII. No. 1.

Heiman, Th. Tödtlicher Schlag durch einige Ohrfeigen verursacht. Zeitsch. f. Ohrenh. XXIV. Bd. 3 Heft.

Hennebert. Un cas de corps étranger de l'oreille. Clinique, No. 28, 1893.

Hermet. Leçons sur les maladies de l'oreille. Rev. de laryn., d'otol. Aug. 15, 1892.

Hersk. De l'otite grippale. Soc. franç. d'otol. et laryn. de Paris. 12-15 Mai, 1893.

Hewitt, J. Adenoid growths as a cause of ear diseases in children. N. Y. Eye and Ear Infirmary reports, Vol. I. part 1. Jan. 1893.

Hewitt, James. A middle-ear douche and an incus hook. N. Y. Med. Record, Apr. 15, 1893.

Heymann. Abscès du cerveau consécutifs à l'otite. Tribune Méd. No. 41, 1892.

Holt, E. E. Removal of the entire auricle and a part of the lobe by the bite of a horse. Trans. Amer. Otolog. Soc. Vol. V. No. 2.

Hovent. Deafness of long standing cured in a few days. Med. and Surg. Reporter, Dec. 3, 1892.

Hovent. Surdité très ancienne dépendant de l'obstruction des trompes d'Eustache. Guérison en quelques jours. Rev. de laryn., d'otol. Aug. 15, 1892.

Hubbard, T. An apparatus of precision for inflating and medicating the tympanum. Arch. of Otol. Vol. XXII. No. 1.

Huchard. Endocardite infectieuse pyohémique consécutive à une otite moyenne. Semaine méd. No. 1, 1893.

Hunton, A. W. A bullet wound in the ear. Lancet, Apr. 29, 1893.

Jack, F. L. Remarkable improvement in hearing by removal of the stapes. Trans. Amer. Otolog. Soc. Vol. V. No. 2. Boston Med. and Surg. Journal, Sept. 29, 1892.

Jack, F. L. Removal of the stapes in chronic catarrhal otitis media and in chronic suppurative otitis media. Boston Med. and Surg. Journal, Nov. 3 and 17, 1892.

Jack, F. L. Further notes on removal of stapes. Boston Med. and Surg. Journal, Jan. 5, 1893.

Jack, F. L. Remarks on two cases of excision of the stapes. Boston Med. and Surg. Journal, Apr. 13, 1893.

Jankan. Zur Differential-Diagnose der Mittelohr- und Labyrintherkrankungen. Arch. f. Ohrenh. XXXIV. Bd. 3 Heft.

Jansen. Ueber Hirnsinus-thrombose nach Mittelohreiterungen. Arch. f. Ohrenh. XXXV. Bd. 1 und 2 Heft.

Jurka. Cas de carcinome du conduit auditif externe à issue fatale. (Review.) Ann. des mal. de l'oreille, Jan. 1893.

Katz. Ueber eine Methode, makropische Präparate des Gehörorgans durchsichtig zu machen. Arch. f. Ohrenh. XXXIV. Bd. 3 Heft.

Katz. Mikrophotographischer Atlas der normalen und pathologischen Anatomie des Ohres. (Review.) Arch. f. Ohrenh. XXXIV. Bd. 1 und 2 Heft.

Katz. Ueber die Auwendung einer 3 procentigen Chromsaürelösung gegen chronische Mittelohreiterung. Therapeutische Monatshefte, July, 1893.

Kipp, C. J. A case of acute purulent inflammation of the middle ear, with double optic neuritis, but without tenderness or swelling of, or spontaneous pain in, the mastoid process, in which the opening of the mastoid cells was followed by a rapid subsidence of the optic neuritis and cure of the ear disease. Trans. Amer. Otolog. Soc. Vol. V. No. 2.

Kirchner. Ein Fall schnell tödtlich verlaufender eiteriger Meningitis nach Otitis media. Berl. klin. Wochenschr. June 5, 1893.

Knapp, H. A case of chronic purulent otitis media; old pulmonary tuberculosis; opening of the mastoid; death from acute basilar meningitis; autopsy. Trans. Amer. Otolog. Soc. Vol. V. No. 2.

Knapp, H. Mucocele and empyema of the ethmoidal cells and sphenoidal sinuses, causing displacement of the eyeball; their operation from the orbit. Arch. of Otol. Vol. XXII. No. 3.

Knapp, H. Otitic brain disease: its varieties, diagnosis, prognosis, and treatment, illustrated by cases from the writer's practice. Arch. of Otol. Vol. XXII. No. 2.

Knapp, H. Otic brain disease; its varieties, diagnosis, and treatment. N. Y. Med. Record, Oct. 22, 1892.

Knapp, H. A marked case of rudimentary and displaced auricle, with defective development of the side of the face. Arch. of Otol. Vol. XXI. No. 4.

Knapp, H. Ein Fall der sogenannten Bezold'schen Mastoiditis. Eröffnung des Warzenfortsatzes. Craniotamie. Tod. Zeitschr. f. Ohrenh. XXIV. Bd. 3 Heft.

Koerner, O. Das Fortschreiten von Krankheiten der Paukenhöhle durch den carotischen Canal in die Schädelhöhle. Zeitschr. f. Ohrenh. XXIII. Bd. 3 und 4 Heft.

Koerner, O., und von Wild, R. Die Percussion des Warzenfortsatzes, nebst Mittheilung eines neuen Falles von diabetischer Caries dieses Knochens. Zeitschr. f. Ohrenh. XXIII. Bd. 3 und 4 Heft.

Körner, Otto. The propagation of affections of the tympanum through the carotid canal into the cerebral cavity. Arch. of Otol. Vol. XXII. No. 2.

Körner, Otto. A study of some topographical relations of the temporal bone. Arch. of Otol. Vol. XXI. No. 4.

Körner, Otto. Randall's Untersuchungen über den Einfluss der Schädelform auf topographisch wichtige Verhältnisse am Schläfenbein. Zeitschr. f. Ohrenh. XXIV. Bd. 3 Heft.

Kosegarten, W. Erkrankung des Ohres bei Influenza. Zeitschr. f. Ohrenh. XXIII. Bd. 3 und 4 Heft.

Labit. Diagnostic des affections de l'oreille par l'emploi du diapason. Paris, 1893.

Lacoarret. Un cas de mastoïdite primitive. Ann. de la Policl. de Toulouse, No. 1, 1893.

Lacoarret. Accidents pseudo-méningitiques dus à un bouchon de cérumen. Annal. de la Policlin. de Toulouse, No. 6, 1893.

Lacombe. Essai sur les traumatismes de la membrane du tympan chez les marins. Thèse Montpellier, 1892.

Laguens. Contribution a l'étude des kystes dermoïdes congénitaux rétro-auriculaires. Thèse Montpellier, 1892.

Lannois. Pavillon de l'oreille chez les sujets sains. Imprimerie Storck, Lyon, 1892. (Review.) Ann. des mal. de l'oreille, Mai, 1893.

Lassalle. Tumeurs fibreuses volumineuses du lobule de l'oreille consécutives à la perforation du lobule; ablation; légère saillie chéloïdique de la cicatrice. Annal. de dermat. et de syphil. Apr. 1893.

Le Gendre et Beaussenat. Infection staphylococcique: otite, méningite, et arthrite suppurées; broncho-pneumonie. Sem. méd. No. 38, 1892.

Lemcke. Deaf-mutism in the Grand-Duchy of Mecklenburg-Schwerin. (Review.) Arch. of Otol. Vol. XXII. No. 1.

Lemcke. Die Taubstummheit im Grossherzogthum Mecklenburg-Schwerin. Arch. f. Ohrenh. XXXV. Bd. 1 und 2 Heft.

Leroy. Traitement chirurgical de l'otite moyenne sèche. Thèse de Paris, 1893.

Linsmayer, L. Ein Fall von Verknöcherung der Ohrmuscheln. Monats f. Ohren. June, 1893.

Linsmayer, L. Heftige subjective Ohrgeräusche. Ligatur der rechten Carotis interna. Tod an Hemiplegie und Pneumonie nach 5 Tagen. Wiener med. Blätter, Nos. 8 und 9, 1893.

Loewenberg. Sur la propriété de la méthode physiologique de cathétérisme de la trompe d'Eustache. Ann. des mal. de l'oreille, May, 1893.

Loewenberg. Contribution à la séméiologie et au traitement du catarrhe de la trompe d'Eustache. Ann. des mal. de l'oreille, May, 1893.

Loewenberg. Des mucosités du pavillon et de la trompe et de l'influence qu'ont sur elles les insufflations. Soc. de laryn. de Paris, March 3, 1893.

Love, James Kerr. The pathology of deaf-mutism. Arch. of Otol. Vol. XXII. No. 3.

Love, J. K. The hearing-power in deaf-mutes: being the results of the examination of 175 deaf-mute children. Arch. of Otol. Vol. XXII. No. 2.

MacBride. Maladies de la gorge, du nez, et des oreilles. (Review.) Rev. de laryn., d'otol. Aug. 1, 1892.

Maloney, J. A. The ear of man and the organ of Corti. Annals of Ophth. and Otol. Apr. 1893.

Maloney, J. A. An aural reflex. Annals of Ophth. and Otol. Oct. 1892.

Manoury. Suppuration des cellules mastoïdiennes; douleurs intolérables; trépanation de l'apophyse mastoïde; abscès en contact avec la dure-mère: disparition des douleurs, etc. Rev. intern. de rinolog. etc. No. 9, 1893.

Marchant. Les complications septico-pyohémiques dans l'otite. Semaine méd. No. 40, 1893.

Margoulisse. Contribution à l'étude de l'otite moyenne aiguë dans les maladies infectieuses chez les enfants. Thèse Paris, 1892.

Martha. Des microbes de l'oreille. Ann. des mal. de l'oreille, July, 1893.

Masini. Les maladies du labyrinthe et leur diagnostic. Boll. delle malatt. dell'orecchio, No. 11, 1892.

Maurel. Traitement de quelques complications de l'otite moyenne purulente chronique. Concours méd. No. 24, 1893.

Max. Un traitement de l'otalgie tympanique. Sem. méd. Sept. 7, 1892.

Melcior. Nécrose de l'apophyse mastoïdite. Rev. de laryng., otol. Sept. 1892.

Mendel, H. Otite externe syphilitique tertiaire. Ann. des mal. de l'oreille, May, 1893.

Ménière. Observation d'un corps étranger de l'oreille. Gaz. des Hôpitaux, No. 128, 1892.

Millet. Audition colorée. Thèse Montpellier, 1892.

Milligan. Excision of the auditory ossicles in middle ear disease. Brit. Med. Jour. Nov. 26, 1892.

Minor, J. L. Aspergillus of the ear. Maryland Med. Jour. Jan. 7, 1893.

Morat. Système ganglionnaire du nerf du marteau. Tribune méd. Sept. 1, 1892.

Morel. Etude historique, critique, et expérimentale de l'action des courants continus sur le nerf acoustique à l'état sain et l'état pathologique. Thèse de Bordeaux, 1892.

Morel. Traitement de l'otite moyenne purulente chronique. Concours méd. No. 9, 1893.

Mounier. De l'incision précose du tympan dans l'otite moyenne aïgue simple. Ann. des mal. de l'oreille, Oct. 1892.

Moos, S. Histology of two petrous bones of a girl completely deaf from scarlet fever; died of purulent meningitis. Arch. of Otol. Vol. XXII. No. 1.

Moos, S. Ueber den diagnostischen Werth der Percussion des Warzenfortsatzes. Zeitschr. f. Ohrenh. XXIV. Bd. 1 und 2 Heft.

Moos, S. Neue Stimmgabeln. Zeitschr. f. Ohrenh. XXIV. Bd. 1 und 2 Heft.

Mygind, Holger. Kurze Beschreibung der dem pathologischen Museum der Universität Kopenhagen gehörnden Schläfebeine Taubstummer. Zeitschr. f. Ohrenh. XXIV. Bd. 1 und 2 Heft.

Mygind, Holger. Short description of the temporal bones of deaf-mutes belonging to the Pathological Museum of the Copenhagen University. Arch. of Otol. Vol. XXII. No. 3.

Mygind, Holger. A case of unilateral total absence of the labyrinth caused by scarlatinous otitis interna. Arch. f. Ohrenh. Vol. XXII. No. 1.

Mygind, Holger. Ein Fall von einseitiger totaler Abwesenheit des Labyrinths verursacht durch scarlatinöse Otitis interna. Zeitschr. f. Ohrenh. XXIII. Bd. 3 und 4 Heft.

Mygind, Holger. Deaf-mutes in Denmark. Arch. of Otol. Vol. XXI. No. 4.

Natier. Otorrhée consécutive à un tamponnement des fosses nasales. Rev. méd. No. 34, 1892.

New York Eye and Ear Infirmary Reports. (Review.) Arch. of Otol. Vol. XXII. No. 2.

New York Otological Society. Regular meeting held Nov. 22, 1892. Arch. of Otol. Vol. XXII. No. 1.

Niemack. Zur Histologie der Ohrpolypen. Arch. f. Ohrenh. Bd. XXXIV. 1 und 2 Heft.

Nimier, H. Contribution à l'étude de la répartition géographique en France des affections de l'oreille. Ann. des mal. de l'oreille, Oct. 1892.

Nimier, H. Contribution à l'étude de la répartition géographique en France de la surdi-mutité. Ann. des mal. de l'oreille, May, 1893.

Oaks, J. F. Indications for and rationale of Eustachian catheterism. Annals of Ophth. and Otol. Apr. 1893.

Orgogozo, F. Les indications de l'ouverture de l'apophyse mastoïde dans les otites infectieuses. Ann. des mal. de l'oreille, Nov. 1892.

Ostmann. Die Würdigung des Fettpolsters der lateralen Tubenwand. Arch. f. Ohrenh. XXXIV. Bd. 3 Heft.

Ostmann. Druck und Drucksteigerung im Labyrinth. Arch. f. Ohrenh. Bd. XXXIV. 1 und 2 Heft.

Ostmann. Ueber das Abhängigkeitsverhältniss der Form des äusseren Gehörgangs von der Schädelform. Monatschr. f. Ohrenh. Mar. 1893.

Ots, Esquerdo. Etiologie de l'othématome. Siglo medico, Apr. 23, 1893.

Panse, Rudolf. Aus der Kgl. Universitäts-Ohrenklinik in Halle a. S. Stacke's Operations methode zur Freilegung der Mittelohrraüme während des ersten Jahres ihrer Anwendung in der Ohrenklinik zu Halle a. S. vom 14 Januar, 1891, bis 14 Januar, 1892. Arch. f. Ohrenh. XXXIV. Bd. 4 Heft.

Parker. Pyæmia of otitic origin successfully treated by the removal of a putrid thrombus from the jugular vein and lateral sinus. Brit. Med. Jour. 1893.

Parkin, Alfred. Two cases of aural pyæmia treated by operation. Lancet, March 11, 1893.

Peugniez. Deux cas de trépanation de l'apophyse mastoïdite. Rev. intern. de rinol. etc. No. 3, 1893.

Picqué, L., et Février, Ch. Contribution à l'étude des abscès intra-craniens d'origine otique. Ann. des mal. de l'oreille, Dec. 1892.

Pole, A. C. Contribution to the literature of foreign bodies in surgery. Maryland Med. Jour. Dec. 17, 1892.

Politzer, A. Lehrbuch der Ohrenheilkunde. (Review.) Annal. des mal. de l'oreille, Apr. 1893.

Politzer, A. Lehrbuch der Ohrenheilkunde. (Review.) Arch. of Otol. Vol. XXII. No. 2.

Politzer, A. Traité d'otologie. (Review.) Rev. de laryn., d'otol. June 1, 1893.

Politzer. Traité des maladies de l'oreille. Stuttgart, Enke, 1893.

Politzer, A. Ouverture de la caisse tympanique par la méthode de Kuster. Rev. de laryn. d'otol. March 1, 1893.

Politzer, A. On perforation of the mastoid process in cases of acute otitis media due to influenza. Brit. Med. Journal, Dec. 31, 1892.

Polo. Traitement non-chirurgical de la suppuration de l'oreille. Gaz. méd. de Nantes, No. 8, 1893.

Pomeroy, O. D. Cases of mastoid disease, exhibiting somewhat extensive carious processes. Trans. Amer. Otolog. Soc. Vol. V. No. 2.

Pritchard, Urban. Pyæmic thrombosis of the lateral sinus following acute otitis; sinus opened and internal jugular vein dissected out; recovery; remarks. Lancet, Mar. 4, 1893.

Pritchard, Edward J. Foreign body in the ear for twenty-one years. Lancet, June 10, 1893.

Pye-Smith. Cerebral abscess secondary to purulent otorrhœa; drainage of abscess; thrombosis of lateral sinus; pyæmia; death. Lancet, Dec. 24, 1892.

Randall, B. Alex. Excision of membrane and malleus for catarrhal deafness, followed by suppuration, mastoid empyema, and burrowing abscess of the neck. Trans. Amer. Otolog. Soc. Vol. V. No. 2.

Randall, B. Alex. Preliminary notes on craniometric studies in relation to aural anatomy. Trans. Amer. Otolog. Soc. Vol. V. No. 2.

Randall, B. Alex. An attempt to replace an auricle bitten off in childhood. Arch. of Otol. Vol. XXII. No. 2.

Randall, B. Alex. Earache and acute middle-ear inflammation. Amer. Jour. of Med. Sciences. Feb. 1893.

Raoult. Essai sur les perforations de la membrane de Shrapnell. Thèse de Paris, 1893.

Roberts, N. S. Pyoktanin in ear diseases. N. Y. Med. Record, Jan. 1893.

Robinson, B. Disorders of the ears in typhoid fever. N. Y. Med. Record, Sept. 3, 1892.

Robinson, J. R. Functional deafness and destruction of the membrana tympani, caused by an electric shock while using a telephone. Annals of Ophth. & Otol. Jan. 1893.

Rohrer. Weitere Versuche über die antimykotische Wirkung von Anilinstoffen. Arch. f. Ohrenh. 34 Bd. 3 Heft.

Roosa, D. B. St. John. A case of exostosis of the external auditory canal. Removal. Considerable improvement in the hearing power. Trans. Amer. Otolog. Soc. Vol. V. No. 2.

Roosa, D. B. St. John. Wound of the lateral sinus during an operation upon the mastoid process, in a patient with phthisis pulmonalis. Septicæmia. Recovery. Trans. Amer. Otolog. Soc. Vol. V. No. 2.

Rossi, Dr. Sur la chirurgie de l'oreille moyenne. Arch. ital. di otologia, fasc. 2, 1893.

Rougier. Compte-rendu de la clinique d'otologie et de laryngologie. Bull. méd. et adm. de Lyon, Sept. 1892.

Rupp, A. A contribution to the pathology of garroting. A case in which the external auditory canal was injured. N. Y. Med. Record, June 17, 1893.

Rutten. Le vertige auriculaire dans le bain. Union Méd. Sept. 15, 1892. Presse Méd. Belge, No. 31, 1892.

Rutten. Du vertige auriculaire dans le bain. Union Méd. Sept. 15, 1892.

Ryan, James P., and Barrett, James W. Removal of lead from the ear by the use of metallic mercury. Lancet, Oct. 15, 1892.

Sachs. Beobachtungen über das physiologische Verhalten des Gehörorgans Neugeborener. Arch. f. Ohrenh. 35 Bd. 1 u. 2 Heft.

Sandmann. Erwiderung auf die Besprechung des Herrn Dr. Panse, betr. "die Tafel des menschlichen Gehörorgans." Arch. f. Ohrenh. 34 Bd. 3 Heft.

Sandmann. Tafel des menschlichen Gehörorgans. (Review.) Arch. f. Ohrenh. 34 Bd. 1 und 2 Heft.

Scheibe, Arno. On the pathogenesis of transudation into the middle ear in cases of stoppage of the tube. Arch of Otol. Vol. XXI. No. 4.

Schlomka. Exostoses du conduit auditif externe. Reviewed by A. Joly. Ann. des mal. de l'oreille, Apr. 1893.

Schmiegelow, E. Contribution to the surgical treatment of ear diseases. Arch. of Otol. Vol. XXI. No. 4.

Schmiegelow, E. Casuistische Beiträge zur Pathologie des Processus mastoideus. Zeitschr. f. Ohrenh. XXIV. Bd. 1 und 2 Heft.

Scott, Bernard, and Lane, Arbuthnot. Treatment of a case of pyæmia resulting from disease of the middle ear. Lancet, Jan. 21, 1893.

Schwartz, E. A case of otitis media acuta purulenta with caries of the mastoid process due to caries of the second molar tooth. Arch. of Otol. Vol. XXII. No. 2.

Schwartze, H. Handbuch der Ohrenheilkunde. (Review.) Arch. of Otol. Vol. XXII. No. 1.

Schwartze. Handbuch der Ohrenheilkunde. Review. Arch f. Ohrenh. 34 Band. 3 Heft.

Schwartze, H. Handbuch der Ohrenheilkunde. Review. Monats. f. Ohrenh. Feb. 1893.

Schwidop. Ein Fall von Sarkom der Schädelbasis mit secundärer Affection des Schläfenbeins. Arch. f. Ohrenh. 35 Bd. 1 u. 2 Heft.

Secchi, C. Sur un nouveau cas d'otolithe. Arch. italiano di otologia. Jan. 1893.

Secrétan, L. L'oto-laryngologie et son importance pour le médecin practicien. (Review). Ann. des mal de l'oreille, Aug. 1893.

Sexton, S. Remarks on otoscleronectomy and otonecronectomy. N. Y. Med. Record, Feb. 18, 1893.

Sheppard, J. E. Three cases of unintentional opening of the lateral sinus. Arch. of Otology, Vol. XXII. No. 3.

Siebenmann, F. Results of the functional examination in cases of pure catarrh of the Eustachian tubes. Arch. of Otol. Vol. XXII. No. 1.

Siebenmann, F. Observations on the functional examination of the normal ear. Arch. of Otol. Vol. XXII. No. 1.

Siebenmann. Choléstéatome de l'oreille moyenne. Corresp. Bl. f. Schw. Aerzte, Oct. 1892.

Siebenmann. Die Radicaloperation des Cholesteatoms mittels Anlegung breiter permanenter Oeffnungen gleichzeitig gen den Gehörgang und gegen die retro-auriculare Region. Berlin. Klin. Wochenschr. No. 1, 1893.

Simrock, J. The tuning-fork as a remedy in ear diseases. N. Y. Med. Jour. June 10, 1893.

Smith, S. MacCuen. The radical cure of aural polypi. Annals of Ophth. and Otol. April, 1893.

Soc. de laryngol., d'otologie, et de rhinologie de Paris. Ann. des mal. de l'oreille, Nov. 1892.

Soc. de laryngologie, otologie, et rhinologie, de Paris. Ann. des mal. de l'oreille, Dec. 1892.

Soc. de laryngol., otologie, et rhinologie de Paris. Ann. des mal. de l'oreille, Jan. 1893.

Soc. de laryngol., otologie, et rhinologie de Paris. Ann. des mal. de l'oreille, Feb. 1893.

Soc. de laryngol., d'otologie, et de rhinologie de Paris. Ann. des mal. de l'oreille, Mar. 1893.

Société de laryngologie, d'otologie, et de rhinologie de Paris. Ann. des mal. de l'oreilie, Apr. 1893.

Soc. de laryngologie, d'otologie, et de rhinologie de Paris. Ann. des mal. de l'oreille, July, 1893.

Soc. française d'otologie et de laryngologie. Ann. des mal. de l'oreille, March, 1893.

Société française d'otologie, de laryngologie, et de rhinologie. Ann. des mal. de l'oreille, July, 1893.

Soc. d'otologie Américaine. Vingt-cinquième Congrès annuel. Ann. des mal. de l'oreille, Nov. 1892.

Soc. d'otologie Allemande. Ann. des mal. de l'oreille, Dec. 1892.

Spalding, J. A. Ueber den Gebrauch von Benzoinol zum Anfeuchten des Watte-Kügelchens als künstliches Trommelfell. Zeitschr. f. Ohrenh. XXIII. Bd. 3 und 4 Heft.

Spalding, J. A. Ein Fremdkörper der 24 Jahre im aüsseren Gehörgang eingekeilt war, ohne das Gehör zu beeinträchtigen. Zeitschr. f. Ohrenh. XXIII. Bd. 3 und 4 Heft.

Spalding, J. A. Einige Bemerkungen über die Anwendung von Styrone bei chronischen Mittelohreiterungen, speziell bei Perforationen der Shrapnell'schen Membran. Zeitschr. f. Ohrenh. XXIII. Bd. 3 und 4 Heft.

Spear, E. D. Nomenclatura morborum auris et nomenclatura morborum nasi et naso-pharyngis. Trans. Amer. Otolog. Soc. Vol. V. No. 2.

Sprague, Frank B. A simple substitute for the Leiter coil. Bost. Med. and Surg. Jour, July 27, 1893.

Stamoff. Recherches cliniques sur le vertige électrique dans les maladies de l'oreille. Thèse inaug. Genève, 1892.

Steinbrügge, H. Zur Frage der Depression der Reissner'schen Membran. Zeitschr. f. Ohrenh. XXIV. Bd. 1 und 2 Heft.

Stetter. Polypöse Wucherungen im aüsseren Gehörgang, bedingt durch ein Sarkom der Schädelbasis. Arch f. Ohrenh. 34 Bd. 1 und 2 Heft.

Stetter. Jahresbericht aus Dr. Stetter's Ambulatorium und Klinik für Ohren-, Nasen-, Hals-, und Rachen-Kranke. Monats. f. Ohrenh. July, 1893.

Stetter. Beitrag zur operativen Behandlung der Schwerhörigkeit in Folge von Schallleitungshindernissen. Monats. f. Ohrenh. Aug. 1892.

Stewart, W. R. H. A pebble in the ear for eight years without the patient's knowledge. Lancet, July 2, 1892.

Strazza, A. Cas de séquestre du limaçon de l'oreille gauche avec conservation apparente de la faculté auditive. Rev. de laryn., d'otol. Apr. 1, 1893.

Suchannek, H. Beiträge zur mikroskopischen Anatomie der menschlichen Nasenhöhle, speziell der Riechs-Schleimhaut. Zeitschr. f. Ohrenh. XXIV. Bd. 1 u. 2 Heft.

Sutphen, T. Y. Result of opening the mastoid in a case of chronic middle ear suppuration, with cerebral complications and septicæmic symptoms. Recovery. Trans. Amer. Otolog. Soc. Vol. V. No. 2.

Swain, H. S. Ueber das Auftreten von Blasen im aüsseren Gehörgang. Zeitschr. f. Ohrenh. XXIII. Bd. 3 und 4 Heft.

Swinburne, R. E. The relation of aural and nasal affections, based on one thousand cases of otitis media. N. Y. Med. Record, Aug. 6, 1892.

Szenes, S. Sur une complication curative de l'otite moyenne suppurée aïgue. Arch intern. de rinologia, etc. Aug. 1892.

Szenes, S. Bericht über die Verhandlungen der ersten Versammlung der deutschen otologischen Gesellschaft zu Frankfort. Monatsch. f. Ohrenh. Aug. 1892.

Szenes, S. Bericht über die zweite Versammlung der deutschen otologischen Gesellschaft zu Frankfort a. M. 19–21 Mai, 1893. Monats. f. Ohrenh. June, 1893.

Theobald, S. The value of weak solutions of bichloride of mercury in the treatment of otitis media suppurativa. Trans. Amer. Otolog. Soc. Vol. V. No. 2.

Toeplitz, M. Symmetrische congenitale Defecte in den vorderen Gaumenbogen. Zeitschr. f. Ohrenh. XXIII. Bd. 3 und 4 Heft.

Toeplitz, M. Ein Fall von primärer Labyrinthnekrose mit Facialisparalyse. Zeitschr. f. Ohrenh. XXIII. Bd. 3 and 4 Heft.

Treitel. Moule épidermique du conduit auditif externe. Soc. Berl. de Méd. Sept. 8, 1892.

Tsakyroglous, M. Zum Morbus Ménière. Monats. f. Ohrenh. Nov. 1892.

Tuttle, A. H. Some observations bearing on the treatment of nasal and middle ear affections. Bost. Med. & Surg. Jour. Apr. 13, 1893.

Uchermann, V. The anatomical condition found in a case of deafmutism following scarlatina. Arch. of Otol. Vol. XXII. No. 2.

Urbantschitsch. Ueber Wechselbeziehungen zwischen beiden Gehörorganen. Arch. f. Ohrenh. 35 Bd. 1 u. 2 Heft.

Vacher. Sur une forme rare de rupture des deux tympans. Rev. de laryn., d'otol. July 1, 1893.

Vadakin, J. H. Rheumatism as a cause of partial deafness, with tinnitus. N. Y. Med. Jour. July 15, 1893.

Vali. Untersuchungen an Verbrechern über die morphologischen Veränderungen der Ohrmuschel. Arch. f. Ohrenh. 34 Bd. 4 Heft.

Vali. Essai de création d'un conduit auditif artificiel dans un cas d'absence congénitale du conduit auditif externe avec développement vicieux des deux pavillons. Rev. de laryn., d'otol. Oct. 15, 1892.

Valledor. Catarrhe de la trompe d'Eustache. Arch. intern. de rinologia, No. 26, 1893.

Vatter. De quelques cas de corps étrangers de l'oreille chez des enfants; considérations sur le traitement. Rev. Méd. Sept. 18, 1892.

Verdos y Mauri. La surdité et son traitement. (Review.) Rev. de laryn., d'otol. Aug. 15, 1892.

Viquier. Papillome du pavillon de l'oreille. Jour. de Méd. de Bordeaux, No. 25, 1893.

Von Stein, S. The study of the functions of the different parts of the labyrinth of the ear. (Review.) Arch. of Otol. Vol. XXII. No. 1.

Von Stein. Etude sur les fonctions de chaque partie du labyrinth. Moscow, 1892.

Wagenhaüser. Labyrinthbefund eines Falles von Taubheit bei Leukämie. Arch. f. Ohrenh. 34 Bd. 3 Heft.

Wickersheimer. Kurze Anleitung zur Verwendung der Wickersheimer-'schen Flüssigkeit für anatomische Präparate, mit einem Anhange über Metallcorrosionen. (Review.) Arch f. Ohrenh. 34 Bd. 1 und 2 Heft.

Wilson, H. Vibratory massage of the middle ear by means of the telephone. N. Y. Med. Jour. Feb. 25, 1893.

Wurdemann, H. V. The treatment of chronic suppuration in the middle ear by removal of the carious ossicles, necrosed bone, and other obstructions in the tympanum, with nine illustrations. Annals of Ophth. and Otology, July, 1893.

Ziem, C. Zur Behandlung der paraauriculären Abscesse und der acuten Mittelohreiterung. Monatschr. f. Ohrenh. Oct. 1892.

Zuckerkandl, D. E. Normal and pathological anatomy of the nose and its pneumatic appendices. (Review.) Arch. of Otol. Vol. XXII. No. 1.